

CLINICAL REPORT

Retrospective Evaluation of Conservative Treatment for 140 Ingrown Toenails with a Novel Taping Procedure

Akiko WATABE, Kenshi YAMASAKI, Akira HASHIMOTO and Setsuya AIBA
Department of Dermatology, Tohoku University Graduate School of Medicine, Sendai, Japan

The aim of this study is retrospectively to review the efficacy of a taping procedure for treating ingrown toenails or for supporting other conservative treatments of ingrown toenails. A total of 140 ingrown toenails treated at the Dermatology Clinic in Tohoku University Hospital were retrospectively reviewed for demographic characteristics, association with granulation tissue or infection, treatment modalities and their outcomes, and classified according the treatment modalities. All the ingrown toenails were treated with a novel taping procedure, “slit tape-strap procedure” alone or in conjunction with other conservative treatments. The mean \pm SD duration until pain relief and until cure of the ingrown toenail were 4.8 ± 4.7 days, range 0–24 and 21.0 ± 11.2 weeks, range 4–56, respectively. All of the treatments were all effective, although 18 cases recurred after treatment. The “slit tape-strap procedure” is effective in treating ingrown toenails, either as a monotherapy or as a supportive therapy for other conservative treatments. *Key words:* ingrowing nail; tape-strapping treatment; foot care; non-invasive conservative treatment.

Accepted Feb 10, 2015; Epub ahead of print Feb 11, 2015

Acta Derm Venereol 2015; 95: 822–825.

Kenshi Yamasaki, Department of Dermatology, Tohoku University Graduate School of Medicine, 1-1 Seiryō-cho, Aoba-ku, Sendai 980-8574, Japan. E-mail: kyamasaki@med.tohoku.ac.jp

Ingrown toenails are a common condition seen by family physicians and hospital-based foot care units. The tip or edge of an ingrown toenail injures the skin of the nail fold and toe, causing pain, tenderness, infection, limited motion, and reduced quality of life. In patients with diabetes, injuries of the toes and foot often result in severe infections that can be life threatening. Invasive treatment for ingrown toenails may be contraindicated in patients with diabetes because of delayed wound healing.

There are 2 types of treatment for ingrown toenails: operative and conservative. Operative treatments are partial or complete nail avulsion, and matricectomy of ingrown nails by excision, bipolar diathermy, carbon dioxide laser or chemically with phenol, trichloroacetic acid and sodium hydroxide. Although operative treatments are effective and can achieve rapid resolution of infectious

complications, such as excessive granulation tissue, the procedures are invasive, time-consuming and expensive, and may, result in relapse and deformity of the toenails (1).

Several conservative treatments are reported to reduce complications and achieve success in offices lacking surgical equipment. These methods include cotton-wool insertion under the corner of the nail and silver nitrate cautery of the granulation tissue (2), gutter treatment or flexible tube splinting (3–5), taping for embedded toenails (6), elastic wire device (7, 8), and a shape-memory alloy device (9). The goal of these conservative methods is: (i) to protect the nail fold from an ingrown toenail, and then (ii) to reform the transverse overcurvature of the ingrowing toenail. Since a few to several months are required for nail growth to reform the ingrown toenail, self-administered care for the nail fold and bed is essential for successful treatment of ingrowing toenails.

Among conservative treatments, taping is the safest, least painful and most convenient procedure. In addition, performed correctly and consistently, it can achieve its goal in mild cases (6). However, treating toenails that have caused the formation of granulation tissue or whose surrounding skin is sweaty can be difficult because the tape does not remain stuck to the skin. To compensate for this, we created a novel taping “slit tape-strap” procedure.

In our foot-care unit, we treated 140 ingrown toenails of 121 patients from October 2007 to July 2010. All patients were treated conservatively with the “split tape-strap” procedure. Among them, 48 ingrown toenails were treated with taping (“split tape-strap” alone or “split tape-strap” + “Nishioka’s procedure”), while the other 92 ingrown toenails were treated with “split tape-strap” in conjunction with other conservative treatments. We retrospectively reviewed these cases and assessed the efficacy of the “slit tape-strap” procedure.

PATIENTS AND METHODS

Patients

This was a retrospective case study of ingrown toenails treated at the foot-care unit of the Dermatology Clinic in Tohoku University Hospital, Sendai, Japan, between October 2007 and July 2010. The study was approved by the ethics committee of Tohoku University Graduate School of Medicine. All patients were referred to the Dermatology Clinic and were treated with a taping procedure alone or in combination with other procedures, including an elastic wire device, gutter treatment, a shape-memory alloy device, or a combination of 2 or 3 different treatment devices.

To examine the background condition and to rule out possible adverse effects, some patients received examination for bacterial infection in the granulation tissue, or onychomycosis or fungal skin infection when necessary.

Data collection and classification

We systematically reviewed all case notes regarding 140 ingrown toenails of 121 patients. We collected information concerning gender, age, involved toes, nail shape, association with excessive granulation tissue, fungal or bacterial infection, applied treatments and their outcomes.

We classified the toenail shapes of the patients with ingrown toenails into 4 clinical types by modifying the classification reported by Baran et al. (10), since the ingrown toenails showed more or less transverse overcurvature. Clinical type 1 included the toenails with normal transverse curvature or overcurvature without rolling of the lateral plate margins. Clinical type 2 included pincer toenails that typically show the trumpet nail deformity with rolling of the lateral plate margins. Clinical type 3 included plicated toenails of moderate convexity with 1 or both lateral plate edges sharply bent to form a vertical sheet pressing into the lateral nail groove. Clinical type 4 included flat toenails without total loss of the transverse curve, mostly pressing into the lateral nail fold.

Treatment modality of the tape-strap method

We conducted 2 different taping procedures “split tape-strap procedure” and “Nishioka’s procedure” by which the patients

were taught how to cut and apply elastic tape to their ingrown toenails. The tape was changed every 1 or 2 days.

The “split tape-strap procedure” was conducted as follows. Depending on the width and length of the toe, the elastic tape is cut into pieces 3 cm wide and 8–10 cm long and folded in half longitudinally (Fig. 1A). The slit, cut to the width of the ingrown nail, is made at one-third the length of the tape-strap from the short edge (Fig. 1B and 1C). To apply “split tape-strap procedure” to ingrown nails (Fig. 1D and 1E), the ingrown nail tip is set in the centre of the slit by orienting the shorter side of the tape toward the dorsal side of the toe, and the slit edge of the longer side of the tape is hooked on the ingrown nail (red arrows in Fig. 1F). The longer side of the tape-strap is then attached to the plantar side of the toe with tension to draw the distal nail-fold skin toward the plantar side (blue arrows in Fig. 1F and 1G). Under mild tension (black arrows in Fig. 1H), the shorter side of tape is attached to the dorsal side of the toe. The “slit tape-strap procedure” can be applied to any toe by choosing tape of the appropriate width for each toe (Fig. 1I).

In Nishioka’s procedure, first introduced by Nishioka et al. (6) and modified by Arai et al. (5), an elastic strip of tape is cut to approximately 15–20 mm wide and 5 cm long and applied so that it allows the lateral nail fold to be pulled away from the toenail. This is usually done in an oblique and proximal direction over the pulp of the toe without impairing the joint movement and avoiding a circular constriction of the toe. A second, so-called anchor tape, is applied over the beginning of the first tape to fix it and exert more pull on the distal nail fold. In this study, we first applied the “split tape-strap procedure” and then conducted Nishioka’s procedure to utilize “split tape-strap” as an anchor tape.

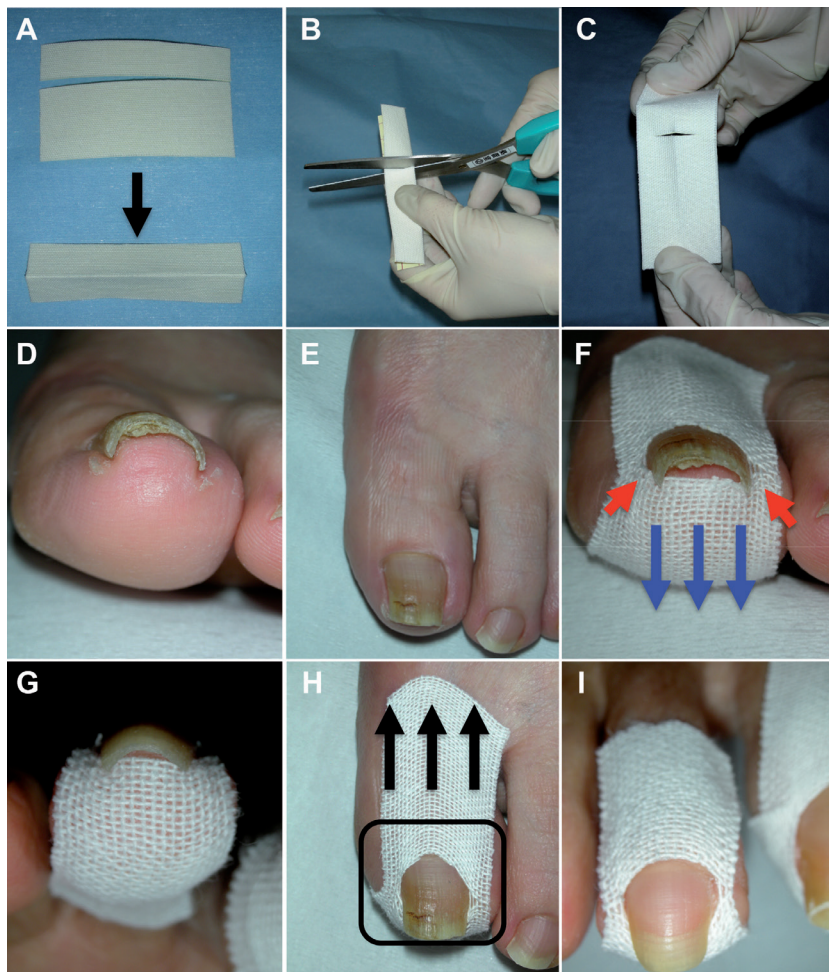


Fig. 1. Treatment modality of the “split tape-strap” procedure. (A) Elastic tape is cut into pieces approximately 3 cm wide and 8–10 cm long and folded in half longitudinally. (B, C) A slit is cut at one-third the length of the tape-strap from the short edge. (D, E) Clinical presentation of ingrown toenail on the left foot. (F) The ingrown nail tip is set in the centre of slit with the shorter side of the tape oriented toward the dorsal side of the toe. The edge of the slit is hooked on the edge of the ingrown nail (red arrows). The shorter side of the tape is attached to the dorsal side of the toe, while the longer side of the tape-strap is attached to the plantar side of the toe under tension in order to draw the nail-fold skin toward the plantar side (blue arrows). (G) The edge of the slit beneath the ingrown toenail. (H) The shorter side of the tape is stretched to attach to the dorsal side of the toe (black arrows) in order that the slit in the tape is hooked between the free nail edge and the nail bed. (I) The “slit tape-strap” procedure is applied to the second toe with the tape adjusted to an appropriate width.

RESULTS

Patients' characteristics and procedures

We retrospectively reviewed 140 ingrown toenails of 121 patients in total (mean \pm standard deviation (SD): age 54.6 ± 19.1 years; median and range: 58 and 7–92 years, respectively). The sample comprised 103 toenails from female patients and 37 nails from male patients. Among them, 50 ingrown toenails were either infected with fungi, as confirmed by KOH examination, or accompanied by bacterial paronychia with pus discharge.

We treated 140 ingrown toenails with 6 different procedures (Table I). Thirty-eight cases were treated with monotherapy of the “split tape-strap” procedure (Procedure 1) (Fig. 1), 31 cases with the “split tape-strap” procedure + elastic wire device (Procedure 2) (Fig. S1D¹), 20 with the “split tape-strap” procedure + gutter method (Procedure 3) (Fig. S1C¹), 12 cases with the “split tape-strap” procedure + a shape-memory alloy (Procedure 4) (Fig. S1F¹), 10 cases with the “split tape-strap” procedure + Nishioka's procedure (Procedure 5) (Fig. S1A and B¹), and 29 cases with various combinations of more than 2 different treatments (Procedure 6). Most of the patients visited every 2 weeks for the first 2 months and then every month thereafter.

This study included 45 toenails of clinical type 1, 43 of type 2, 41 of type 3, and 11 of type 4. Procedure 1 was performed for 4 toenail types, with higher frequency for type 3. Procedure 2 was performed with higher frequency for type 2. Procedure 3 was mainly for ingrown toenails accompanied by excessive granulation tissue. Procedures 4 and 5 were used for fewer cases of type 2. Procedure 6 was used for more cases of type 2. All pro-

cedures relieved pain for a mean of 3.7–6.8 days after the initiation of treatment. The mean duration required to completely cure an ingrown toenail ranged from 17.6 to 25.1 weeks. Patients treated with procedures 1 and 6 showed earlier resolution until cure of the ingrown toenail, while those treated with Procedure 2 required more time for complete resolution. Among these cases, however, 18 cases recurred 3 or more months after they were completely cured. The recurrence rates vary from 0% to 25% depending on the treatment modalities.

Tape-strap method combined with operative and other conservative treatments

One of the benefits of the “split tape-strap” procedure is that it is able to support other conventional and surgical treatments. Nishioka's procedure is also useful for drawing the granulation tissue away from an ingrowing toenail, but tape alone often fails to draw it away sufficiently because of the wet surface. The “split tape-strap” procedure can be used as the anchor tape of Nishioka's procedure in order to cover the wet surface of the granulation tissue with elastic tape (Fig. S1A and B¹). Because the “split tape-strap” covers wet granulation tissues, tapes of Nishioka's procedure can adhere rigidly to the anchoring “split tape-strap” and can efficiently draw granulation tissue away from the edge of nails. Furthermore, it is useful with the gutter method to keep the splinting tube away from the granulation tissue (Fig. S1C¹). This procedure protects the nail bed or nail fold from injury and contact with the metal devices when elastic wire devices, VHO-Osthold brace, or shape-memory alloy devices are applied (Fig. S1D–F¹). After cutting the edge of a pincer toenail, it prevents the growing nail from hurting the nail bed and edge (Fig. S1G–I¹). Thus the “split tape-strap” procedure is useful as a supportive treatment for other methods.

¹<https://doi.org/10.2340/00015555-2065>

Table I. Demographic data and treatment outcomes of each treatment procedure for ingrown toenails

No. Procedures	Ingrown toenails <i>n</i>	Sex, F/M <i>n</i>	Age, years Mean \pm SD Median (range)	Involved toes		Clinical types of nail shapes ^a				Exces- sive granu- lation <i>n</i> (%)	Infec- tion ^b <i>n</i> (%)	Duration until pain relief, Mean \pm SD Median (range)	Duration until cure of ingrown toenail, weeks Mean \pm SD Median (range)	Recurrence <i>n</i> (%)
				First <i>n</i>	Others <i>n</i>	1 <i>n</i>	2 <i>n</i>	3 <i>n</i>	4 <i>n</i>					
1 Slit tape-strap (STS)	38	28/10	57.1 \pm 17.3 59.5 (23–90)	34	4	10	8	18	2	2 (5)	15 (3)	3.7 \pm 4.0 2.0 (0.3–16)	17.6 \pm 10.3 13.5 (5–36)	3 (8)
2 STS + Elastic wire	31	26/5	58.0 \pm 18.1 62.0 (14–92)	31	0	12	15	4	0	1 (3)	7 (23)	6.8 \pm 5.5 6.0 (0.4–24)	25.1 \pm 11.4 24.0 (7–48)	5 (16)
3 STS + Gutter	20	10/10	43.1 \pm 25.1 42.0 (7–81)	17	3	6	2	5	7	19 (9)	14 (7)	4.5 \pm 5.4 2.5 (0–24)	20.3 \pm 11.5 17.5 (7–52)	1 (5)
4 STS + Shape-memory alloy	12	11/1	54.8 \pm 16.6 55.5 (30–74)	12	0	5	2	5	0	0 (0)	4 (33)	3.9 \pm 2.3 3.5 (1–8)	19.9 \pm 10.3 20.0 (5–44)	3 (25)
5 STS + Nishioka's procedure	10	5/5	61.7 \pm 20.8 61.5 (21–86)	10	0	3	1	4	2	4 (4)	3 (30)	5.1 \pm 7.1 2.5 (0.3–24)	19.3 \pm 13.9 15.5 (4–56)	0 (0)
6 STS + Multiple	29	23/6	53.1 \pm 16.0 58.0 (20–84)	29	0	9	15	5	0	12 (41)	7 (24)	4.4 \pm 3.8 3.0 (1–14)	22.6 \pm 10.6 20.0 (7–48)	6 (21)
Total	140	103/37	54.6 \pm 19.1 58.0 (7–92)	133	7	45	43	41	11	38 (27)	50 (36)	4.8 \pm 4.7 3.0 (0–24)	21.0 \pm 11.2 20.0 (4–56)	18 (13)

^aSee the Patients and Methods section. ^bIncludes fungal or bacterial infection.

DISCUSSION

In general, ingrown toenails are treated either with operative or conservative treatments. Operative treatments for ingrowing toenails, such as nail avulsion and matrixectomy, require equipment and skilled physicians, are often contraindicated by the patient's general condition or infection around the nail, and have the serious drawback of pain during and after the operation. Even with the proper procedures, operative treatments occasionally result in relapse of the ingrown toenail and nail deformity. In contrast, conservative treatments can be applied without equipment in a clinic or at home and induce fewer complications than operative treatment. Compared with operative therapies, however, conservative treatments take longer time to achieve satisfactory results because their success depends on proper nail growth. Thus, it is essential for conservative therapies to be easy and self-administrable by the patients themselves.

The taping method for ingrown toenails was first introduced by Nishioka et al. (6). The object of the method is to pull the lateral nail fold away from the offending lateral nail edge. Performed correctly and consistently, it can achieve its goal in mild cases of ingrown toenails. The technique of Nishioka's procedure is, however, crucial, and most patients require repeated education concerning how to perform it. Moreover, if the skin surrounding ingrown toenails is wet for any reason, it is difficult to apply this procedure because of the loss of adhesiveness of the elastic tape. To overcome this drawback, we devised the "slit tape-strap" procedure. Since, in this procedure, one edge of the slit is hooked on the edge of the ingrown toenail and the tape adheres to the skin throughout the whole circumference of the ingrown nail, a focal wet surface of the skin surrounding the ingrown toenail does not disturb this procedure.

Furthermore, this retrospective study revealed the following benefits of the "slit tape-strap" procedure: (i) it is convenient for patients of all ages regardless of their complications, (ii) it is effective for mild to severe ingrowing toenails, (iii) it can reduce downtime, (iv) it is useful as an anchor tape on granulation tissues, and (v) it can be combined with other methods. Any kind of elastic tape can be used for the tape-strap methods, and most elastic tapes are not expensive. Because patients can change the tape themselves, nails can be washed and the tape-strap can be changed easily. In our experience, all patients and families could follow this procedure after they were instructed once.

Recently, epidermal growth factor receptor (EGFR) inhibitors have become part of the therapeutic arsenal available for advanced colorectal cancer, non-small-cell lung cancer, pancreatic cancer and squamous-cell carcinoma of the head and neck. Paronychias are the earliest and most common form of unguis lesions, and are observed in 10–30% of patients receiving EGFR inhibitors (reviewed by Peuvrel et al. (11)). Paronychias can

be complicated by excessive granulation (12). Although paronychias regress rapidly within a few days once treatment is discontinued (12, 13), the clinical course of excessive granulation tissue is prolonged, even following the withdrawal of EGFR inhibitors (14). For such cases, the "slit tape-strap" procedure is recommended.

In conclusion, this retrospective study shows that conservative treatment can cure most cases of ingrown toenails and that, depending on the circumstances, the novel "slit tape-strap" procedure provides an effective treatment modality as a monotherapy or in conjunction with other conservative therapies.

ACKNOWLEDGEMENTS

We thank Yumiko Ito for valuable technical support. This study was supported in part by the Global-COE Program from the Japanese Ministry of Education, Culture, Sports, Science and Technology.

The authors declare no conflicts of interests.

REFERENCES

- Haneke E. Controversies in the treatment of ingrown nails. *Dermatol Res Pract* 2012; 2012: 783924.
- Senapati A. Conservative outpatient management of ingrowing toenails. *J R Soc Med* 1986; 79: 339–340.
- Wallace WA, Milne DD, Andrew T. Gutter treatment for ingrowing toenails. *BMJ* 1979; 2: 168–171.
- Schulte KW, Neumann NJ, Ruzicka T. Surgical pearl: nail splinting by flexible tube – a new noninvasive treatment for ingrown toenails. *J Am Acad Dermatol* 1998; 39: 629–630.
- Arai H, Arai T, Nakajima H, Haneke E. Formable acrylic treatment for ingrowing nail with gutter splint and sculptured nail. *Int J Dermatol* 2004; 43: 759–765.
- Nishioka K, Katayama I, Kobayashi Y, Takijiri C. Taping for embedded toenails. *Br J Dermatol* 1985; 113: 246–247.
- Machida E, Maruyama K, Sano S. [The correction of ingrown, curved nails with super elastic wire.] *J Jpn Soc Surg Foot* 1999; 20: S87 (in Japanese).
- Moriue T, Yoneda K, Moriue J, Matsuoka Y, Nakai K, Yokoi I, et al. A simple therapeutic strategy with super elastic wire for ingrown toenails. *Dermatol Surg* 2008; 34: 1729–1732.
- Ishibashi M, Tabata N, Suetake T, Omori T, Sutou Y, Kainuma R, et al. A simple method to treat an ingrowing toenail with a shape-memory alloy device. *J Dermatolog Treat* 2008; 19: 291–292.
- Baran R, Haneke E, Richert B. Pincer nails: definition and surgical treatment. *Dermatol Surg* 2001; 27: 261–266.
- Peuvrel L, Bachmeyer C, Reguiat Z, Bachet JB, Andre T, Bensadoun RJ, et al. Semiology of skin toxicity associated with epidermal growth factor receptor (EGFR) inhibitors. *Support Care Cancer* 2012; 20: 909–921.
- Robert C, Soria JC, Spatz A, Le Cesne A, Malka D, Pautier P, et al. Cutaneous side-effects of kinase inhibitors and blocking antibodies. *Lancet Oncol* 2005; 6: 491–500.
- Rigopoulos D, Larios G, Gregoriou S, Alevizos A. Acute and chronic paronychia. *Am Fam Physician* 2008; 77: 339–346.
- Agero AL, Dusza SW, Benvenuto-Andrade C, Busam KJ, Myskowski P, Halpern AC. Dermatologic side effects associated with the epidermal growth factor receptor inhibitors. *J Am Acad Dermatol* 2006; 55: 657–670.