

SHORT COMMUNICATION

Ultrastructural Investigations in an Autosomal Recessively Inherited Case of Dyschromatosis Universalis Hereditaria

Aayush Gupta¹, Yugal Kishor Sharma¹, Kedar Nath Dash¹, Sampurna Verma¹, Vivek T. Natarajan² and Archana Singh²¹Department of Dermatology, Leprology and Venereology, Dr. D.Y. Patil Medical College, Pimpri, Pune, and ²Systems Biology Group, CSIR-Institute of Genomics and Integrative Biology, New Delhi, India. E-mail: archana@igib.in, aayushgupta@gmail.com

Accepted Dec 3, 2014; Epub ahead of print Dec 4, 2014

The dyschromatoses are a group of rare genodermatoses characterised by the presence of asymptomatic mottled hyperpigmented macules admixed with variably sized hypopigmented macules (1). Dyschromatoses are divided into dyschromatosis symmetrica hereditaria (DSH) and dyschromatosis universalis hereditaria (DUH). DUH is clinically diagnosed on the basis of widely distributed small hypo- and hyperpigmented lesions with appearance in infancy or early childhood and progression until stagnation before adolescence (2). This division got highlighted recently by the detection of specific mutations in *ADARI/DSRAD* and *ABCB6* genes in DSH and DUH, respectively (1, 3). First reported from Japan, DUH has subsequently been reported from several regions of the world as a generalised leucomelanoderma relatively sparing the face, palms and soles. It is usually transmitted in an autosomal dominant (AD) pattern with variable penetrance, with very few autosomal recessive (AR) and even sporadic cases reported (4, 5). In this study, we present ultrastructural findings in a case of DUH, with probable AR transmission.

CASE REPORT

A 23-year-old unmarried male, product of consanguineous marriage, presented to us with mottled dyspigmentary patches

which appeared insidiously since the age of 15 years, initially over the trunk and slowly progressed over a period of 6 years onto the back, abdomen and proximal extremities sparing the palms and soles. He denied history of altered sensations, chronic drug intake, photosensitivity or any contact with chemicals. All, except the eldest of his siblings, were similarly affected. Neither their parents, nor any of the 9 children of his 4 siblings were affected. Pictures of 3 out of his 4 affected siblings are shown in Fig. S1¹. Dermatological examination revealed innumerable irregular 1–10 mm sized hypopigmented macules interspersed with numerous minute hyperpigmented ones, over trunk, back and proximal extremities (Fig. 1). Hair, nail, mucosae, general physical and systemic examination revealed no abnormality. On the basis of these features, our case was diagnosed to have DUH. The family was counselled and the hypo- and hyperpigmented lesions of the proband were subjected to ultrastructural and molecular analysis.

Transmission electron microscopy of ultrathin sections of the skin biopsies revealed comparable number of melanocytes in the 2 skin lesions, though the number of melanosomes per melanocytes were significantly reduced in hypopigmented epidermis as compared to hyperpigmented lesion (Fig. 2). Ultrastructure of melanocytes from ethnicity- and skin colour-matched normal skin is shown in Fig. S2¹.

Melanocytes and keratinocytes exist in the skin as a functional ‘epidermal melanin unit’. We therefore examined the distribu-

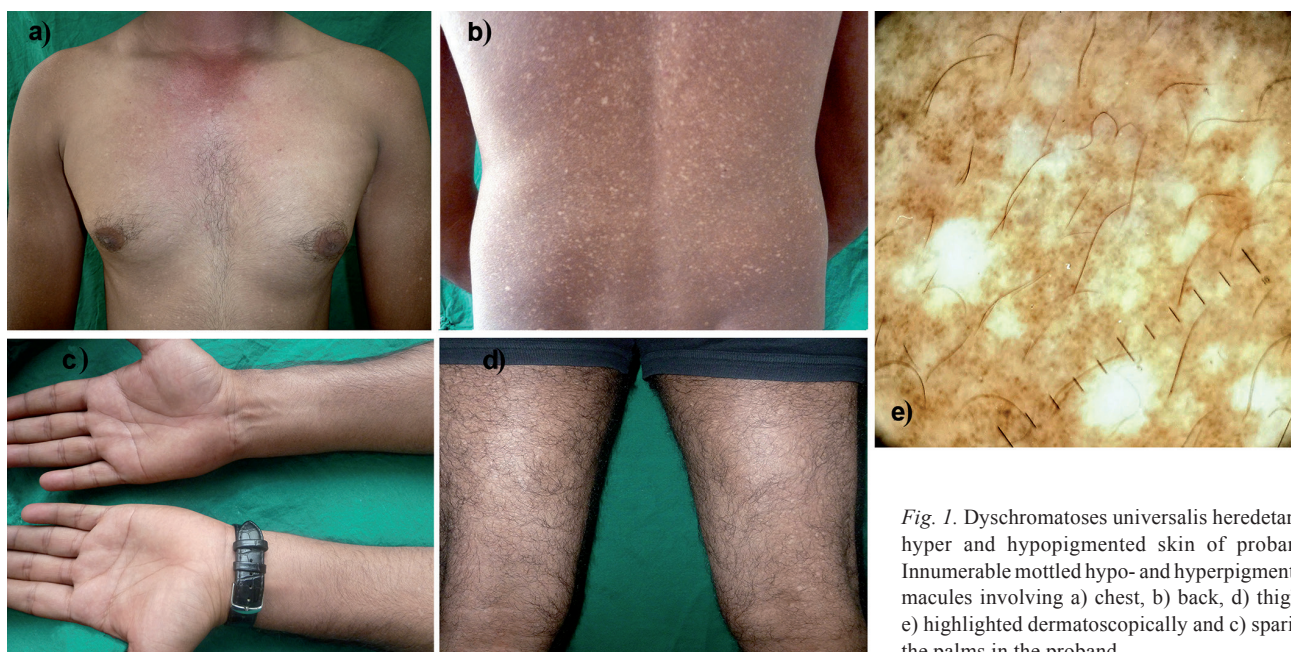
¹<https://doi.org/10.2340/00015555-2030>

Fig. 1. Dyschromatosis universalis hereditaria: hyper and hypopigmented skin of proband. Innumerable mottled hypo- and hyperpigmented macules involving a) chest, b) back, d) thighs, e) highlighted dermatoscopically and c) sparing the palms in the proband.

tion of melanosomes in the basal and suprabasal keratinocytes. The keratinocytes in hyperpigmented lesion presented with a relatively higher number of melanosomes (Fig. S3 a–e, vertical panel 3 and 4¹) compared to that of hypopigmented skin (Fig. S3 a–e, vertical panel 1 and 2¹). The increase in melanosome numbers in hyperpigmented epidermis was more than 2-fold compared to hypopigmented lesions (Fig. S3f¹). A large proportion of melanosomes were distributed in clusters and only a few of the single melanosomes were present in keratinocytes in both the lesions. Further analysis of melanosomes based on their distribution pattern in keratinocytes revealed significantly higher number of single as well as clusters of 2–4 melanosomes in hyperpigmented lesion compared to hypopigmented skin (Fig. S3g¹). We did not observe significant difference in the sizes of the melanosomes between the keratinocytes of hypo- and hyperpigmented lesions (Fig. S4a¹). Taken together, it suggests that in this form of DUH, melanocyte numbers are not affected. However, the melanosome synthesis and maturation are affected, accounting for lesser number of melanosomes in both melanocytes and keratinocytes of the hypopigmented lesions. Careful examination of the dermis showed presence of numerous melanophages in the hyperpigmented lesion (Fig. S4b–d¹), which was rarely observed in the hypopigmented lesional dermis.

Clear differences in the melanosome numbers in the 2 types of skin lesions prompted us to investigate the regulation of melanogenesis pathway in DUH. We compared the transcript levels of 3 key melanogenic enzymes – DCT (dopachrome tautomerase), TRP1 (tyrosinase related protein 1) and Tyr (tyrosinase) – in the epidermis of the biopsies. Total epidermal RNA was isolated and

converted to cDNA and quantitative real-time PCR analysis was carried out to examine the expression of DCT, TRP1 and TYR transcripts using TaqMan probes. Details of real-time PCR and ultrastructural studies are described in Appendix S1¹. Interestingly, both DCT and TYR showed more than two-fold upregulation in the hyperpigmented lesion as compared to hypopigmented lesion, though no significant difference was observed in expression levels of TRP1 between the 2 skin lesions (Fig. S3h¹).

DISCUSSION

Although most commonly reported inheritance of DUH has been AD (1, 5–8), our patients' pedigree is highly suggestive of an AR transmission (consanguineous marriage of unaffected parents, etc.). However, in absence of detailed genetic analyses, the probability of low penetrant AD pattern of inheritance cannot be ruled out.

The hyperpigmented lesions in DUH reveal increased melanin in the basal layer and, rarely, melanin incontinence. The hypopigmented lesions show decreased melanin deposition in the basal layer (9). Electron microscopically, a number of studies of hypopigmented as well as the hyperpigmented skin (1, 2) have demonstrated morphologically normal melanocytes containing melanosomes of all stages, normal keratinocyte to melano-

cyte ratio and tyrosinase activity as indicated by a positive DOPA reaction. However, the number of melanosomes is higher in both melanocytes and keratinocytes in hyperpigmented lesions and this feature has been observed in other studies as well (1, 10). We speculate that the presence of heavily pigmented cells in dermis could add to the perception of skin colour of the hyperpigmented lesions. Interestingly, the number of melanocytes in hypopigmented lesions in leprosy are also known to be comparable to that of the uninvolved skin (11). In future studies, mechanisms that alter melanocyte functions in these 2 contrasting disorders (DUH vs leprosy) would provide an opportunity to understand regulatory circuits involved in skin pigmentation.

The *ABCB6* gene, located at 2q36, is the cause of AD transmitted form of DUH (2, 12). This gene belongs to a family of transporters that play a critical role in cellular transition metal homeostasis (13). Copper, a co-factor for tyrosinase in vertebrates, is a candidate ion that could utilise this transporter. In view of more than two-fold increase observed in TYR and DCT genes in hyperpigmented epidermis viz-a-viz hypopigmented one, it would

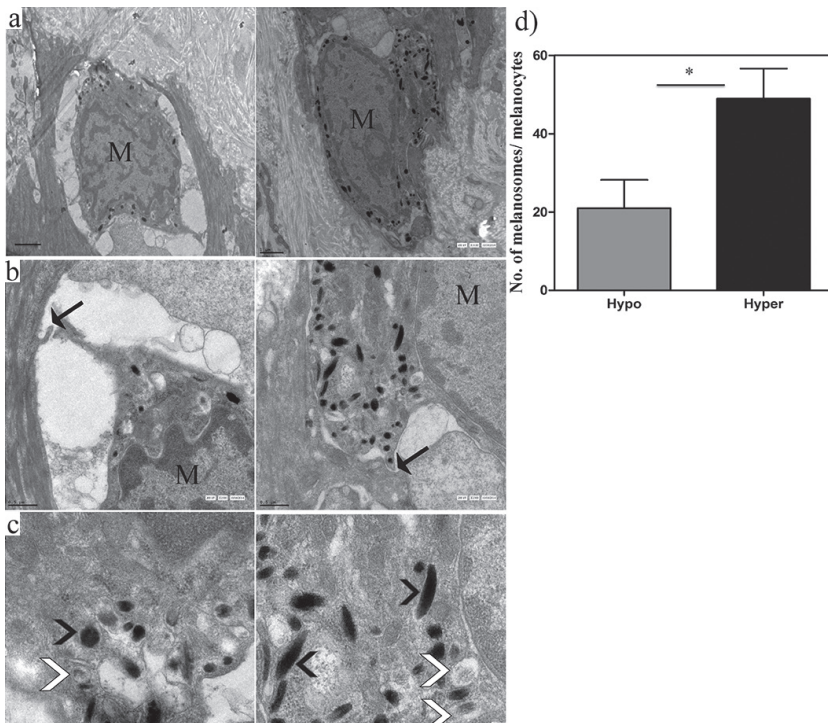


Fig. 2. Representative micrographs of melanocytes (M, at the dermal–epidermal junction) containing few melanosomes in the hypopigmented lesion (left panel) and relatively higher number of melanosomes in hyperpigmented lesion (right panel). Micrographs in a) show melanocytes at lower magnifications (scale bar 1 μ m). Arrows in b) show absence of desmosomal connections in cell–cell junction between melanocytes and neighbouring keratinocytes (scale bar 0.5 μ m). Magnified images in c) reveal presence of early (white arrowheads) and late stage melanosomes (black arrowheads) in both hypo- and hyperpigmented lesions (scale bar 0.2 μ m). d) Melanocytes in hyperpigmented epidermis show significantly higher number of melanosomes ($n=6$ melanocytes counted mean with SEM). * p -value < 0.05.

be interesting to investigate how mutations in copper transporter genes may result in transcriptional changes in tyrosinase and DCT.

Our cases have considerably later onset as well as stabilisation of the disease over time and an AR inheritance pattern. The latter has to the best of our knowledge been hitherto reported in 9 members of 2 families only, none of which were subjected to ultrastructural analysis. The identification of genetic loci for the AR form of DUH may soon lead to unravelling of its pathogenetic mechanisms and, if not identical to ABCB6, may shed further light on this extremely rare and genetic heterogeneous condition.

ACKNOWLEDGEMENTS (see Fig. S2¹)

REFERENCES

- Chin YY, Chen GS, Hu SC, Lan CC. Dyschromatosis universalis hereditaria: a familial case with ultrastructural skin investigation. *Derm Sinica* 2011; 29: 137–141.
- Nuber UA, Tinschert S, Mundlos S, Hauber I. Dyschromatosis universalis hereditaria: familial case and ultrastructural skin investigation. *Am J Med Gen* 2004; 125A: 261–266.
- Liu H, Li Y, Hung KKH, Wang N, Wang C, Chen X, et al. Genome-wide linkage, exome sequencing and functional analyses identify ABCB6 as the pathogenic gene of dyschromatosis universalis hereditaria. *PLoS ONE* 2014; 9: e87250.
- Yusuf SM, Mijinyawa MS, Maiyaki MB, Mohammed AZ. Dyschromatosis universalis hereditaria in a young Nigerian female. *Int J Dermatol* 2009; 48: 749–750.
- Bukhari IA, El-Harith EA, Stuhmann M. Dyschromatosis universalis hereditaria as an autosomal recessive disease in five members of one family. *J Eur Acad Dermatol Venereol* 2009; 20: 628–629.
- Wu CY, Huang WH. Two Taiwanese siblings with dyschromatosis universalis hereditaria. *Clin Exp Dermatol* 2009; 34: e666–e669.
- Wu YH, Lin YH. Generalized Dowling Degos disease. *J Am Acad Dermatol* 2007; 57: 327–334.
- Al Hawsawi K, Al Aboud K, Ramesh V, Al Aboud D. Dyschromatosis universalis hereditaria: report of a case and review of the literature. *Pediatr Dermatol* 2002; 19: 523–526.
- Wang G, Li CY, Gao TW, Liu YF. Dyschromatosis universalis hereditaria: two cases in a Chinese family. *Clin Exp Dermatol* 2005; 30: 494–496.
- Kim NS, Im S, Kim SC. Dyschromatosis universalis hereditaria: An electron microscopic examination. *J Dermatol* 1997; 24: 161–164.
- Natarajan VT, Ganju P, Singh A, Vijayan V, Kirty K, Yadav S, et al. IFN- γ signaling maintains skin pigmentation homeostasis through regulation of melanosome maturation. *Proc Natl Acad Sci USA* 2014; 111: 2301–2306.
- Zhang C, Li D, Zhang J, Chen X, Huang M, Archacki S, et al. Mutations in ABCB6 cause dyschromatosis universalis hereditaria. *J Invest Dermatol* 2013; 133: 2221–2228.
- Petris MJ, Strausak D, Mercer JF. The Menkes copper transporter is required for the activation of tyrosinase. *Hum Mol Genet* 2000; 9: 2845–2851.