

INVESTIGATIVE REPORT

Experimentally Induced Psoriatic Lesions Associate with Rapid but Transient Decrease in Interleukin-33 Immunostaining in Epidermis

Mireille-Maria SUTTLE¹, Mattias ENOKSSON², Anna ZOLTOWSKA², Madhumita CHATTERJEE², Gunnar NILSSON² and Ilkka T. HARVIMA¹

¹Department of Dermatology, University of Eastern Finland and Kuopio University Hospital, Kuopio, Finland, and ²Department of Medicine, Karolinska Institutet, Stockholm, Sweden

A slight epidermal damage can induce the Köbner reaction in psoriasis, and the “alarmin”, interleukin-33 (IL-33), may be involved in this process. Therefore, the uninvolved psoriatic skin was tape-stripped, and skin biopsies were collected at 0 day, 2 h and 3 days or at 0 day, 1 day and 7 days for immunohistochemistry. Eight patients out of 18 with the positive Köbner reaction showed a decrease in epidermal thickness and revealed transient reduction in epidermal nuclear immunostaining of IL-33 in 2-h, 1-day, 3-day biopsies compared to the 10 Köbner-negative patients. In keratinocyte cultures, the full-length 32-kDa IL-33 was detected after damaging the cells with freeze-thawing. Interestingly, a very low concentration of rh-IL-33 (0.001–0.01 ng/ml) significantly stimulated ³H-thymidine uptake by human LAD2 mast cells, but not by psoriatic peripheral blood mononuclear cells. The results show that epidermal IL-33 associates with positive Köbner response, and only a small amount of the IL-33 apparently released may induce proliferation in dermal mast cells. Key words: IL-33; psoriasis; epidermis; Köbner reaction; mast cell.

Accepted Nov 24, 2014; Epub ahead of print Nov 26, 2014

Acta Derm Venereol 2015; 95: 536–541.

Dr. Ilkka Harvima, Department of Dermatology, Kuopio University Hospital, POB 100, FIN-70029 Kuopio, Finland. E-mail: ilkka.harvima@kuh.fi

Numerous different cell types are involved in the pathogenesis of psoriasis, including T cells, antigen presenting cells, neutrophils, mast cells and keratinocytes (1, 2). Psoriasis is characterised by chronic inflammation and epidermal hyperplasia, and therefore epidermis and dermis are in close relationship in the developing lesion. An interesting feature of psoriasis is the Köbner reaction that usually develops in healthy-looking skin in 38–76% of patients 7–14 days after slight skin injury (3). The rupture of epidermis has been reported to be an initiating factor for the Köbner response, though dermal involvement is needed for lesion development (4).

The Köbner reaction can be induced by stripping the skin surface with an adhesive tape until slight erythema develops (5, 6). However, the early cellular mechanisms

that lead to psoriatic process after mild damage in the epidermis are poorly known. For example, the number of mast cells has been reported to increase temporarily within 6 h after scarification and thereafter the cell number increased again at day 4 (7). In addition, the activity of mast cell chymase decreases steadily after tape-stripping (5). Recently, it has been demonstrated that the expression of nerve growth factor is upregulated in Köbner-positive epidermis within 24 h after tape-stripping of uninvolved psoriatic skin (6).

Interleukin-33 (IL-33) is a relatively novel IL-1-like cytokine that is constitutively expressed in the nuclei of keratinocytes and endothelial cells. IL-33 is considered to be a novel alarmin that is released upon cell injury and thereafter alerts the immune system (8). Indeed, the tape-stripping of normal skin has recently been reported to lead to upregulation of gene expression of IL-33, IL-8, TNF- α , Hsp90 and Hsp70 in the epidermis at 6 h (9). One possible target of IL-33 is ST2-positive mast cells that are induced to produce a range of cytokines (10–12). Skin mast cells have recently been demonstrated to be the cell type that express the highest levels of mRNA of *IL1RL1*, the gene for ST2 receptor (13). This strongly suggests that ST2 plays an important role when mast cells respond to IL-33 released during, e.g., cell injury (14). Experimental evidence obtained from mouse cells clearly shows that cells rendered necrotic by freeze-thawing, such as fibroblasts and keratinocytes, can activate mast cells to release IL-6 and TNF- α through IL-33 and ST2 receptor (15). Furthermore, IL-33 expression and mast cell numbers are increased in the chronic psoriatic lesion (5, 10, 12, 16).

We have previously found that the mast cell expression of IL-6 is higher in skin biopsies taken from psoriatic patients showing the Köbner reaction (induced by the tape-stripping technique) compared to those without this reaction (17). In this work, we hypothesised that IL-33 is released from epidermal keratinocytes after damaging the skin surface leading to the initiation of a cascade of cellular events.

Using the same biopsy material as previously (17), we now tried to clarify immunohistochemically the early changes in epidermal IL-33 expression after tape-stripping. In addition, the purpose was to study whether there

are differences in IL-33 and ST2 expression between patients with or without Köbner reaction. Keratinocyte culture was used to study the expression of IL-33 in proliferating cells and the presence of full-length IL-33 after cellular damage by freeze-thawing. The effect of IL-33 was further studied in a human LAD2 mast cell line as well as in peripheral blood mononuclear cells (PBMNCs) from psoriatic patients to see whether cell proliferation is affected by IL-33.

MATERIALS AND METHODS

Tape-stripping of uninvolved psoriatic skin and collection of skin biopsies

The study included 18 subjects (4 females and 14 males, age 24–77 years) with chronic scaly psoriasis without pustular changes or erythroderma. The psoriasis area and severity index (PASI) score varied between 1.8 and 18.6 (17). After obtaining consent, the development of psoriatic lesion, i.e., Köbner reaction, was induced using the tape-stripping technique described previously (5). Briefly, a target area, about 2.5×5 –7 cm in size, on the lateral aspect of the arm was tape-stripped with an adhesive tape for about 30–40 times until the skin showed slight redness. The first (day 0) 4-mm punch biopsy was taken after local anaesthesia with 1% lidocaine and adrenaline from a skin site that was just outside of the tape-stripped area. Thereafter, the study subjects were randomly divided into 2 biopsing groups: in the first group the 4-mm skin biopsies were taken from the tape-stripped skin at time points of 2 h and 3 days; in the second group, at 1 day and 7 days. All subjects were evaluated for the development of psoriatic lesion in the follow-up visit about 2–2.5 weeks following the tape-stripping. The subject was judged to belong to the Köbner-positive group (8 subjects out of 18) if an identifiable reddish change, interpreted in a blinded fashion by a well-experienced dermatologist, could be seen on the tape-stripped area outside of the skin biopsy sites.

The patients had not received any effective systemic or local treatment in the preceding month. After removal, the skin biopsies were immediately embedded in OCT compound (Miles Scientific, Naperville, IL, USA) and frozen for preparing 5 µm-thick cryosections as described (5, 17). The methods used were approved by the Ethics Committee of Kuopio University Hospital, Kuopio, Finland.

Immunohistochemical staining of IL-33 and ST2 receptor and measurement of epidermal thickness

For the staining of IL-33 and ST2 the skin cryosections were fixed in cold acetone followed by immunohistochemistry (IHC) using 20 µg/ml rat anti-IL-33 monoclonal antibody (mAb) (clone 390412, R&D Systems, Abingdon, UK) or 5 µg/ml mouse anti-ST2 mAb (clone ST33868, Enzo Life Sciences, Lausen, Switzerland) and Vectastain Elite ABC kit (Vector Laboratories, Burlingame, CA) (5, 17). IL-33 expression in the epidermis was analysed using semiquantitative scoring: score 1 denotes weak staining predominantly in the nuclei of keratinocytes; score 2 denotes moderate nuclear staining along the whole epidermis; and score 3 strong nuclear staining. Since the uppermost epidermis was subject to tape-stripping-induced damage, this was taken into consideration in the analysis. The number of ST2⁺ cells was counted in a dermal area of 1.0 mm (width) \times 0.6 mm (depth) just beneath the epidermis. Only 0-day samples were analysed and the results are expressed as cells/mm².

The thickness of the whole epidermis, from the corneal layer to the basement membrane zone, was measured microscopically at a minimum of 3 random sites/cryosection on at least 2 sections using an ocular grid and $\times 40$ objective. Only 0-day, 2-h and 1-day samples were analysed for this purpose.

Measurement of IL-33 in the necrotic cell supernatant of cultured normal human keratinocytes

Keratinocytes were cultured from human foreskin specimens using keratinocyte-SFM serum-free medium supplemented with epidermal growth factor, bovine pituitary extract, 100 U/ml penicillin and 100 µg/ml streptomycin (18). After obtaining a large number of proliferating keratinocytes in a monolayer, the cells were washed in PBS and rendered necrotic by repeated freeze-thawing as described previously (15). The stock solution of necrotic cell supernatant (NCS) corresponded to 20×10^6 lysed cells per ml of PBS. IL-33 levels in the NCS was measured using ELISA analysis (catalogue number DY3625, R&D Systems). In addition, the presence of IL-33 in the NCS was analysed by Western blotting using 0.2 µg/ml biotinylated mouse anti-human IL-33 antibody (BAF3625, R&D Systems) and anti-biotin-HRP at 1:1000 dilution (Cell Signalling Technology, Boston, USA) (15).

Immunocytochemical staining of IL-33 in keratinocytes

The expression of IL-33 immunoreactivity in cultured keratinocytes was studied in cells grown on glass slides until subconfluent; and adherent cells were fixed using 4% paraformaldehyde and permeabilised with 0.5% triton-X-100. After blocking with 1% BSA in PBS, the cells were incubated overnight with mouse anti-human IL-33 mAb at 1:100 dilution (clone Nussy-1, Alexis Biochemicals, Lausen, Switzerland). Mouse IgG1 (Dako, Glostrup, Denmark) was used as the isotype control. Following thorough washing in a solution of PBS, 0.3% Triton X-100 and 0.1% Tween 20, the cells were incubated for 2 h with goat anti-mouse IgG1 (H+L) Alexa Flour 488 (at dilution 1:100; Invitrogen, Eugene, Oregon, USA). Images were acquired using a confocal laser scanning microscope (TCS SP2, Leica Microsystems).

Stimulation of LAD2 mast cells with IL-33

The human mast cell line LAD2 was cultured using StemPro-34 medium (Invitrogen, Carlsbad, CA, USA) supplemented with 100 ng/ml recombinant human stem cell factor (rh-SCF) (R&D Systems Europe, Oxon, UK), 2 mM L-glutamine, 100 U/ml penicillin and 100 µg/ml streptomycin (19). The cells (0.5 – 1×10^6 /ml) were plated in incomplete StemPro-34 medium, i.e. in the absence of rh-SCF, and were stimulated with a dilution series of rh-IL-33 (R&D Systems) (as described in Results) for 2 days.

³H-thymidine (85 Ci/mmol, Perkin-Elmer, Boston, MA, USA) in RPMI-1640 medium (Invitrogen) was added to the wells, and the cells were pulsed overnight, as described (20). The LAD2 cells were harvested using Combi Cell Harvester (Skatron Instruments AS, Lier, Norway) and the radioactivity was analysed with a liquid scintillation counter using ULTIMA Gold™ liquid scintillation fluid (Perkin-Elmer) (20).

Stimulation of peripheral blood mononuclear cells from psoriatic patients with IL-33

Heparinised blood sample was drawn from the antecubital vein of 4 patients with plaque psoriasis and PBMNCs were separated on Ficoll-Paque by centrifugation at $1,000 \times g$ for 10 min (20). PBMNCs were washed in incomplete (without serum) RPMI-1640 medium and the cells (1×10^6 /ml) were incubated with a dilution

series of rh-IL-33 (as described in Results) for 2 days followed by analysis of ^3H -thymidine incorporation as described above.

RESULTS

Characteristics of Köbner-positive and -negative patients

The mean \pm SD age and PASI score of the subjects in the Köbner-positive group ($n=8$) were 46 ± 15 years and 8.3 ± 4.4 , and those in the Köbner-negative group ($n=10$) were 54 ± 15 years and 6.7 ± 5.0 , respectively. There were statistically no significant differences between these values (unpaired t -test). Both groups included 2 female subjects, and 2 subjects in the Köbner-positive group and 3 subjects in the Köbner-negative group reported joint symptoms.

The mean age of disease onset was 25 ± 14 and 40 ± 17 years in the Köbner-positive and -negative groups, respectively ($p=0.064$, unpaired t -test). However, 7 subjects of 8 in the Köbner-positive group and only 3 subjects of 10 in the Köbner-negative group were found to have a disease onset at less than 30 years.

The thickness of epidermis decreased at 2 h in the Köbner-positive group but not in the Köbner-negative group

To see whether tape-stripping had caused a deeper injury in the epidermis of Köbner-positive patients, the thickness of epidermis was measured in 0-day, 2-h and 1-day biopsies. The epidermal thickness was 0.072 ± 0.022 mm, 0.072 ± 0.010 mm and 0.080 ± 0.024 mm in the Köbner-negative group, respectively, and no statistically significant changes were observed (paired t -test). In contrast, the epidermal thickness was 0.075 ± 0.019 mm, 0.055 ± 0.015 mm and 0.126 ± 0.034 mm in 0-day, 2-h and 1-day biopsies of the Köbner-positive group, respectively. The reduction in epidermal thickness at 2 h was statistically significant ($p=0.0054$, paired t -test), but the increase at 1 day was not ($p=0.12$). No significant differences in epidermal thickness were observed between Köbner-negative and -positive groups.

IL-33 immunostaining first decreased at 2 h, 1 day, 3 days and then increased at 7 days in the epidermis in the Köbner-positive group

The epidermis can be a marked source of IL-33 and the cytokine is presumably released from the nuclei of keratinocytes upon cell injury (8, 15). Therefore, the staining intensity of IL-33 was evaluated semi-quantitatively in the epidermis. As shown in Table I and Fig. 1, the epidermal expression of IL-33 immunoreactivity decreased significantly in keratinocyte nuclei in 2-h, 1-day, 3-day biopsies in the Köbner-positive group but then increased in 7-day biopsies. However the increase was not statistically significant. These changes are in clear contrast to the minor epidermal IL-33 changes in the Köbner-negative group (see Table I).

Full-length IL-33 is present in the supernatant after injury of cultured keratinocytes

Theoretically the reduction in IL-33 immunostaining in the Köbner-positive epidermis after tape-stripping can be either due to IL-33 release or to degradation by proteases or both. The former possibility was studied in cultured keratinocytes shown to express both nuclear and cytoplasmic IL-33 staining patterns (Fig. 2a). Keratinocytes were first damaged by freeze-thawing and subsequently IL-33 was analysed in the NCS by Western blotting (Fig. 2b) and ELISA (Fig. 2c). In the Western blot analysis, a band of approximately 32 kDa in size corresponding to a full-length IL-33 was observed suggesting milieu release. Moreover, the cytokine with this molecular size has been reported to be biologically active (21).

No significant difference in the number of dermal ST2⁺ cells between Köbner-positive and Köbner-negative groups

IL-33 released from epidermal keratinocytes upon cell injury may diffuse to upper dermis and activate cells carrying the ST2 receptor. Therefore, ST2⁺ cells were immunostained and counted in 0d biopsies. The immunostaining showed cells with membrane-like peripheral staining pattern in the upper dermis. The number of ST2⁺ cells was 101 ± 89 cells/mm² in the Köbner-negative group and 152 ± 177 cells/mm² in the Köbner-positive group. However, the difference was not significant ($p=0.474$, unpaired t -test).

Low concentration of rh-IL-33 stimulated LAD2 mast cell proliferation but not PBMNC proliferation

The release of IL-33 from the damaged Köbner-positive epidermis may result in the activation of proinflammatory cells, such as mast cells that are typically accumulated just beneath the epidermis. Therefore, the effect of a di-

Table I. The staining intensity of IL-33 immunoreactivity in the epidermis in Köbner-positive and -negative groups of psoriatic patients

	IL-33 staining intensity (mean \pm SD scores)				
	0 day	2 h	1 day	3 days	7 days
Köbner-positive ($n=8$)	1.1 ± 0.4 ($n=8$)	$0.6 \pm 0.2^*$ ($n=5$)	$0.7 \pm 0.3^{**}$ ($n=3$)	$0.5 \pm 0^{***}$ ($n=5$)	1.7 ± 0.6 ($n=3$)
Köbner-negative ($n=10$)	1.5 ± 0.5 ($n=10$)	1.1 ± 0.5 ($n=4$)	1.3 ± 0.3 ($n=6$)	1.2 ± 0.8 ($n=3$)	1.8 ± 0.6 ($n=6$)
p -value ^a	NS	NS	0.009	0.031	NS

^aMixed model analysis between Köbner groups.

IL-33 was analysed semiquantitatively: score 1 = weak staining predominantly in the nuclei of keratinocytes; score 2 = moderate nuclear staining along the whole epidermis; score 3 = strong nuclear staining. $*p=0.039$, $**p=0.011$ and $***p=0.012$ (mixed model analysis) when comparing the scores to those in corresponding 0-day biopsies (within the Köbner-positive group). NS: not significant.

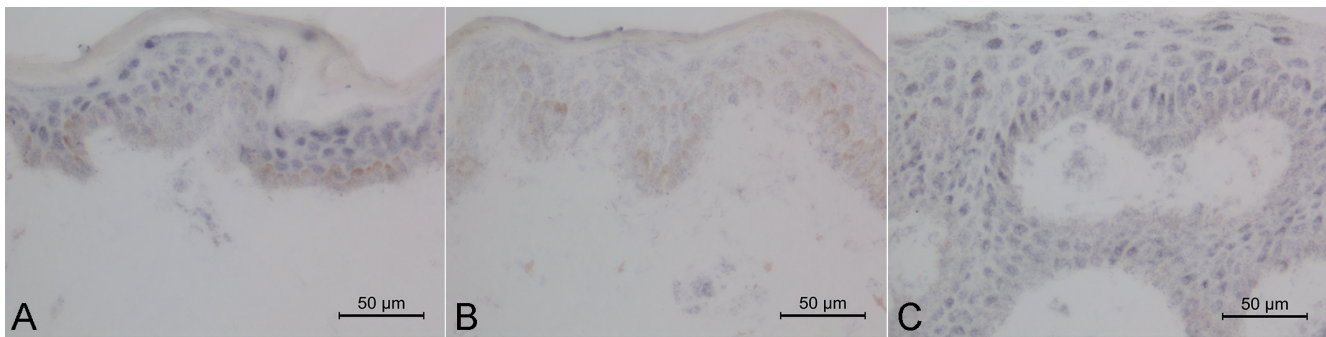


Fig. 1. IL-33 expression in the epidermis during the early phases of positive Köbner reaction. IL-33 was stained immunohistochemically on cryosections from skin biopsies taken A) on day 0, B) on day 1, and C) on day 7 after the tape-stripping. Note, that IL-33 staining is predominantly of the nuclear type, and it decreases on day 1 but then reappear on day 7. In addition, cytoplasmic staining is seen in the basal layer, especially on day 1 (B).

lution series of rh-IL-33 on ^3H -thymidine incorporation into LAD2 mast cells was studied in 6 independent cell culture experiments. When compared to the values by dilution control of rh-IL-33, the ^3H -thymidine incorporation was $110 \pm 12\%$, $131 \pm 36\%$, $130 \pm 25\%$, $125 \pm 35\%$, $98 \pm 19\%$ and $89 \pm 17\%$ at 0.001, 0.01, 0.1, 1.0, 10 and 50 ng/ml rh-IL-33, respectively (Fig. 3). Thus, already very low rh-IL-33 concentration (0.001–0.01 ng/ml) stimulated significantly ^3H -thymidine incorporation into LAD2 mast cells, whereas 10–50 ng/ml rh-IL-33 reversed the stimulation back to the baseline level or below it. In contrast to LAD2 cells, rh-IL-33 did not have any significant stimulatory or inhibitory effect on the ^3H -thymidine incorporation into psoriatic PBMNCs (Fig. 3).

DISCUSSION

About 38–76% of all psoriatic patients show the Köbner reaction in uninvolved psoriatic skin within 7–14 days after slight skin injury (22), and this reaction type has previously been used in the pathogenetic studies of early psoriatic lesion (4–8). However, the triggering factors and cellular mechanisms for the Köbner phenomenon

are still unclear (22). In this study, 8 patients out of 18 revealed the Köbner reaction after tape-stripping as verified at the follow-up visit 2–2.5 weeks later. Hence, this percentage is within the limits reported previously, and no significant differences in age, sex, PASI score and epidermal thickness in 0-day biopsies were found between Köbner-positive and -negative patients. The Köbner reactivity may be a characteristic feature of some psoriatic patients or there are variations between subjects regarding the number of tape-strippings needed for similar epidermal injury. In suction blister experiments, the Köbner reaction developed at sites where the blister roof was removed, but not in those skin sites where the blister roof was left intact or the blister base was occluded with a Finn chamber (4). In this study, the thickness of epidermis decreased significantly in 2-h biopsies of the Köbner-positive group but not in those of the Köbner-negative-group. However, the thickness returned to baseline, or the epidermis became somewhat thicker, in 1d biopsies in both groups. This suggests that a more severe transient damage to the upper epidermis took place during the tape-stripping of Köbner-positive patients. Therefore, the present finding support the pre-

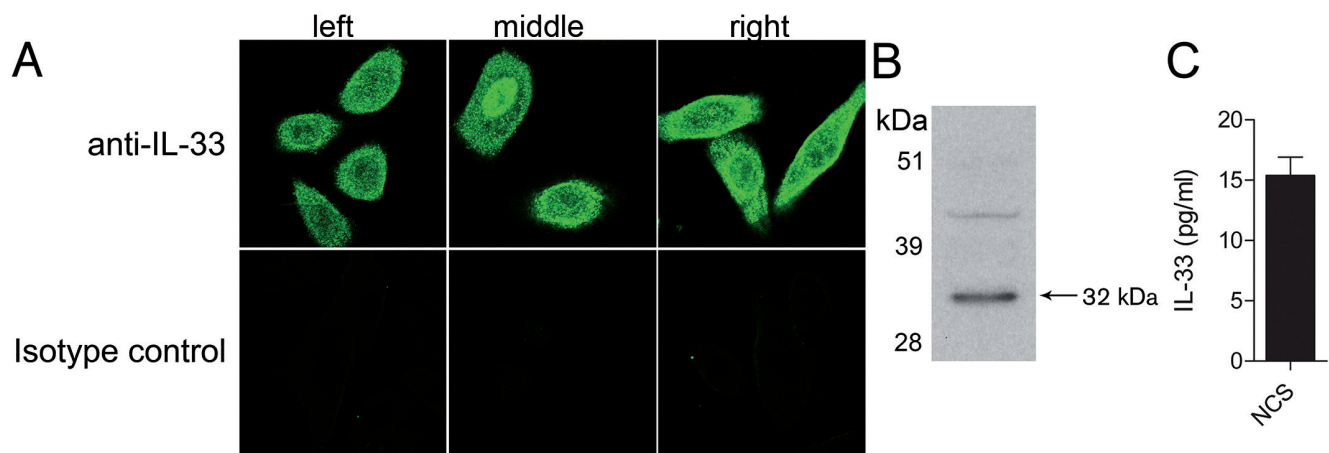


Fig. 2. A) Human proliferating keratinocytes were stained with anti-IL-33 mAb or isotype control. Note the nuclear (middle) and cytoplasmic staining (left, right) patterns of IL-33. B) Full-length IL-33 is present in the necrotic cell supernatant (NCS) of keratinocytes after freeze–thawing of the cells as studied by Western blotting. C) IL-33 immunoreactivity is liberated and is detected in NCS as analysed by ELISA.

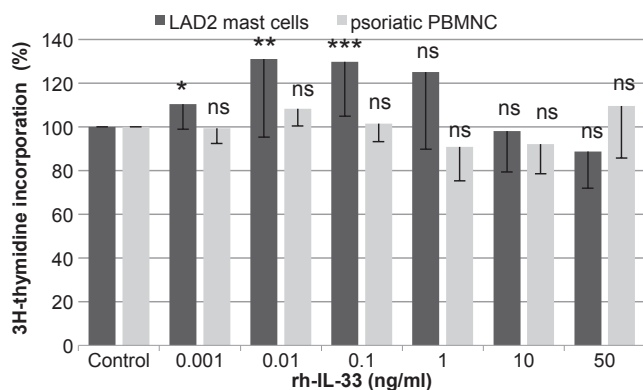


Fig. 3. The effect of rh-IL-33 on the ³H-thymidine incorporation into human LAD2 mast cells ($n=6$) and psoriatic peripheral blood mononuclear cells (PBMNCs) ($n=4$). The results are presented as mean \pm SD percentage compared to the original radioactivity values obtained with the diluent control (LAD2 cells: mean 33,300 cpm; PBMNCs: mean 690 cpm). * $p=0.039$ (paired t -test), ** $p=0.001$, and *** $p=0.003$. ns: not significant.

viously presented conclusion that a rupture in epidermis can be an initiating factor to the Köbner response (4).

The subjects in the Köbner-positive group appeared to have a lower age of disease onset than those in the Köbner-negative group. Such an association has, in fact, been reported previously (23). Possibly there are inherent structural alterations in the upper or corneal layer of epidermis in patients with positive Köbner response, such as changes in corneodesmosomal proteins or corneodesmosin (24, 25), which can explain a deeper damage in the upper epidermis after tape-stripping.

IL-33, an alarmin localised to the nuclei and cytoplasm of keratinocytes, is released upon cell injury (8, 26, the results of this study). This may reflect the function of IL-33, i.e. it can act both as a transcription factor and cytokine (8, 26). The significant decrease in IL-33 immunostaining in 2-h, 1-day, 3-days biopsies together with the decrease in epidermal thickness at 2 h in the Köbner-positive group can reflect the release of IL-33 after damage of the upper epidermis during tape-stripping. In contrast, no marked decrease in IL-33 immunostaining, nor decrease in epidermal thickness, could be noted in the Köbner-negative group. In line with previous studies (15, 20) the *in vitro* experiments with cultured keratinocytes subjected to cell damage by freeze-thawing revealed that a full-length IL-33 is present in the necrotic cell supernatant as detected by ELISA and Western blotting. This finding together with the results of a previous report (16) support the conclusion that biologically active pro-IL-33 is released after epidermal damage. Nevertheless it is still possible that the decrease in IL-33 immunostaining in the tape-stripped epidermis is also a result of proteolytic enzymes, e.g., caspases 1,3,7 and serine proteinases that might cleave the antigenic epitope recognised by the antibody (27).

The released IL-33 may diffuse from the epidermis to the dermis and reach cells carrying the ST2 receptor,

such as mast cells. The outcome can be cell activation and release of other proinflammatory cytokines, e.g. IL-6 and IL-8 (17, 28). For example, IL-33 may reach dermal mast cells loaded with IL-6 in the Köbner-positive group (17). Nevertheless, there was no significant difference in ST2⁺ cell numbers in 0-day biopsies between Köbner-positive and -negative groups, further suggesting that the primary difference in the IL-33-ST2 link appears to be in the rapid change in the expression of IL-33. The stability of the released IL-33 protein may be prolonged because mast cell chymase which has recently been shown to degrade IL-33 (29), is partially inactivated during the Köbner reaction induced by tape-stripping (5).

An interesting finding of our study is that a very low concentration of rh-IL-33, i.e. 0.001–0.01 ng/ml, induced an increase in the ³H-thymidine incorporation into LAD2 mast cells. No such increase in the proliferative response could be detected in psoriatic PBMNCs. This suggests that even minute amounts of the IL-33 released from the epidermis of the Köbner-positive group may induce marked activation of mast cells beneath the epidermis. However, higher concentrations of rh-IL-33 (10–50 ng/ml) reversed the stimulation back to the baseline or even below it. This suggests that rh-IL-33 may not only activate mast cells for proliferation but can also limit this activity. This conclusion is supported by the recent report showing that a prolonged exposure of human mast cells to 10 ng/ml IL-33 *in vitro* resulted in a hyporesponsive phenotype (30). Furthermore, the number of IL-33⁺ cells in the dermis of 0-day biopsies is significantly higher in the Köbner-negative group than in the Köbner-positive group, as reported by us recently (17), which suggests again that IL-33 may have a controlling effect. Alternatively, IL-33 at higher concentrations induces a release of substances that affected the proliferative response of LAD2 mast cells.

In summary, psoriatic patients with positive Köbner response showed a decrease in epidermal thickness and a transient reduction in epidermal IL-33 immunostaining after tape-stripping. Our experiments with keratinocyte cultures suggest that a full-length and biologically active IL-33 is released from these cells after cell injury. It appears that a small amount of released IL-33 can induce marked and rapid activation of mast cells just beneath the epidermis. Therefore, further insights regarding the potential interaction between IL-33 and ST2 may provide a new target in designing therapeutics for preventing the induction of psoriasis development (31).

ACKNOWLEDGEMENTS

The authors wish to thank the strategic funding of the Cancer Center of Eastern Finland of the University of Eastern Finland, the COST Action BM1007 (Mast cells and basophils – targets for innovative therapies), the VTR-funding of Kuopio Univer-

sity Hospital, and the Swedish research council – Medicine and Health. Ms Anne Koivisto and Ms Katja Dufva are acknowledged for expert technical assistance.

The authors declare no conflict of interest.

REFERENCES

- Sabat R, Philipp S, Höflich C, Kreutzer S, Wallace E, Asadullah K, et al. Immunopathogenesis of psoriasis. *Exp Dermatol* 2007; 16: 779–798.
- Harvima IT, Nilsson G, Suttle M-M, Naukkarinen A. Is there a role for mast cells in psoriasis? *Arch Dermatol Res* 2008; 300: 461–478.
- Farber EM, Nall ML. The natural history of psoriasis in 5600 patients. *Dermatologica* 1974; 148: 1–18.
- Powles AV, Baker BS, Rutman AJ, McFadden JP, Valdimarsson H, Fry L. Epidermal rupture is the initiating factor for the Koebner response in psoriasis. *Acta Derm Venereol* 1990; 70: 35–38.
- Harvima IT, Naukkarinen A, Paukkonen K, Harvima RJ, Aalto M-L, Schwartz LB, Horsmanheimo M. Mast cell tryptase and chymase in developing and mature psoriatic lesions. *Arch Dermatol Res* 1993; 285: 184–192.
- Raychaudhuri SP, Jiang WY, Raychaudhuri SK. Revisiting the Koebner phenomenon: role of NGF and its receptor system in the pathogenesis of psoriasis. *Am J Pathol* 2008; 172: 961–971.
- Toruniowa B, Jablonska S. Mast cells in the initial stages of psoriasis. *Arch Dermatol Res* 1988; 280: 189–193.
- Moussion C, Ortega N, Girard J-P. The IL-1-like cytokine IL-33 is constitutively expressed in the nucleus of endothelial cells and epithelial cells in vivo: a novel “alarmin”? *PLoS One* 2008; 3: e3331.
- Dickel H, Gambichler T, Kamphowe J, Altmeyer P, Skrygan M. Standardized tape stripping prior to patch testing induces upregulation of Hsp90, Hsp70, IL-33, TNF- α and IL-8/CXCL-8 mRNA: new insights into the involvement of ‘alarmins’. *Contact Dermatitis* 2010; 63: 215–222.
- Theoharides TC, Zhang B, Kempuraj D, Tagen M, Vasiadi M, Angelidou A, et al. IL-33 augments substance P-induced VEGF secretion from human mast cells and is increased in psoriatic skin. *Proc Natl Acad Sci (USA)* 2010; 107: 4448–4453.
- Iikura M, Suto H, Kajiwara N, Oboki K, Ohno T, Okayama Y, et al. IL-33 can promote survival, adhesion and cytokine production in human mast cells. *Lab Invest* 2007; 87: 971–978.
- Hueber AJ, Alves-Filho JC, Asquith DL, Michels C, Millar NL, Reilly JH, et al. IL-33 induces skin inflammation with mast cell and neutrophil activation. *Eur J Immunol* 2011; 41: 2229–2237.
- Motakis E, Guhl S, Ishizu Y, Itoh M, Kawaji H, de Hoon M, et al. Redefinition of the human mast cell transcriptome by deep-CAGE sequencing. *Blood* 2014; 123: e58–67.
- Lunderius-Andersson C, Enoksson M, Nilsson G. Mast cells respond to cell injury through the recognition of IL-33. *Front Immunol* 2012; 3: 82.
- Enoksson M, Lyberg K, Möller-Westerberg C, Falon PG, Nilsson G, Lunderius-Andersson C. Mast cells as sensors of cell injury through IL-33 recognition. *J Immunol* 2011; 186: 2523–2528.
- Balato A, Lembo S, Mattii M, Schiattarella M, Marino R, De Paulis A, et al. IL-33 is secreted by psoriatic keratinocytes and induces pro-inflammatory cytokines via keratinocyte and mast cell activation. *Exp Dermatol* 2012; 21: 892–894.
- Suttle M-M, Nilsson G, Snellman E, Harvima IT. Experimentally induced psoriatic lesion associates with IL-6 in mast cells and appearance of dermal cells expressing IL-33 and IL-6 receptor. *Clin Exp Immunol* 2012; 169: 311–319.
- Huttunen M, Hyttinen M, Nilsson G, Butterfield JH, Horsmanheimo M, Harvima IT. Inhibition of keratinocyte growth in cell culture and whole skin culture by mast cell mediators. *Exp Dermatol* 2001; 10: 184–192.
- Kirshenbaum AS, Akin C, Wu Y, Rottem M, Goff JP, Beaven MA, et al. Characterization of novel stem cell factor responsive human mast cell lines LAD 1 and 2 established from a patient with mast cell sarcoma/leukemia; activation following aggregation of Fc ϵ RI or Fc γ RI. *Leuk Res* 2003; 27: 677–682.
- Ilves T, Harvima IT. OX40 ligand and OX40 are increased in atopic dermatitis lesions but do not correlate with clinical severity. *J Eur Acad Dermatol Venereol* 2013; 27: e197–205.
- Talabot-Ayer D, Lamacchia C, Gabay C, Palmer G. Interleukin-33 is biologically active independently of caspase-1 cleavage. *J Biol Chem* 2009; 284: 19420–19426.
- Weiss G, Shemer A, Trau H. The Koebner phenomenon: review of the literature. *J Eur Acad Dermatol Venereol* 2002; 16: 241–248.
- Melski JW, Bernhard JD, Stern RS. The Koebner (isomorphic) response in psoriasis. Associations with early age at onset and multiple previous therapies. *Arch Dermatol* 1983; 119: 655–659.
- Simon M, Tazi-Ahnini R, Jonca N, Caubet C, Cork MJ, Serre G. Alterations in the desquamation-related proteolytic cleavage of corneodesmosin and other corneodesmosomal proteins in psoriatic lesional epidermis. *Br J Dermatol* 2008; 159: 77–85.
- Ameen M, Allen MH, Fisher SA, Lewis CM, Cuthbert A, Kondeatis E, et al. Corneodesmosin (CDSN) gene association with psoriasis vulgaris in caucasian but not in japanese populations. *Clin Exp Dermatol* 2005; 30: 414–418.
- Balato A, Di Caprio R, Canta L, Mattii M, Lembo S, Raimondo A, et al. IL-33 is regulated by TNF- α in normal and psoriatic skin. *Arch Dermatol Res* 2014; 306: 299–304.
- Lefrancais E, Cayrol C. Mechanisms of IL-33 processing and secretion: differences and similarities between IL-1 family members. *Eur Cytokine Netw* 2012; 23: 120–127.
- Fischer M, Harvima IT, Carvalho RFS, Möller C, Naukkarinen A, Enblad G, Nilsson G. Mast cell CD30 ligand is up-regulated in cutaneous inflammation and mediates degranulation-independent chemokine secretion. *J Clin Invest* 2006; 116: 2748–2756.
- Roy A, Ganesh G, Sippola H, Bolin S, Sawesi O, Dagälv A, et al. Mast cell chymase degrades the alarmins heat shock protein 70, biglycan, HMGB1, and interleukin-33 (IL-33) and limits danger-induced inflammation. *J Biol Chem* 2014; 289: 237–250.
- Jung MY, Smrč D, Desai A, Bandara G, Ito T, Iwaki S, et al. IL-33 induces a hyporesponsive phenotype in human and mouse mast cells. *J Immunol* 2013; 190: 531–538.
- Harvima IT, Levi-Schaffer F, Draber P, Friedman S, Polakovicova I, Gibbs BF, et al. Molecular targets on mast cells and basophils for novel therapies. *J Allergy Clin Immunol* 2014; 134: 530–544.