

INVESTIGATIVE REPORT

Dermoscopy of Naevus-associated Melanomas

Danielle SHITARA^{1,2}, Mauricio NASCIMENTO², Priscila ISHIOKA², Cristina CARRERA^{1,3}, Lúcia ALOS⁴, Josep MALVEHY^{1,3} and Susana PUIG^{1,3}

¹Melanoma Unit, Dermatology Department, Hospital Clinic of Barcelona, IDIBAPS, Universitat de Barcelona, Barcelona, Spain, ²Department of Dermatology, Federal University of São Paulo, São Paulo, Brazil, ³IBER de Enfermedades Raras, Instituto de Salud Carlos III, and ⁴Melanoma Unit, Pathology Service, Hospital Clinic of Barcelona, IDIBAPS, Universitat de Barcelona, Barcelona, Spain

In order to determine dermoscopic parameters, a case-control test set of naevus-associated melanomas vs *de novo* melanomas paired by Breslow thickness and histopathological subtype was analysed by 2 blinded experienced dermoscopists, according to presence of naevus, pattern analysis and ABCD dermoscopy score. The ability to identify naevus-associated melanomas by pattern analysis was low for both blinded dermoscopists ($\kappa < 0.2$). Dermoscopy features associated with naevus-associated melanomas were: presence of negative pigment network (OR 9.915, CI 95% 2.182–45.049), globules (OR 2.383, CI 95% 1.15–4.95) and streaks (OR 2.439, CI 95% 1.271–4.680). In contrast, the presence of blue-white veil was related to absence of associated naevus (OR 0.520, CI 95% 0.273–0.991). With the results obtained, 2 different algorithms were proposed. The use of the proposed algorithms could help raise awareness of naevus-associated melanomas and avoid the possibility of incorrectly diagnosing a naevus-associated melanoma if partial biopsies are performed. **Key words: naevus-associated melanoma; *de novo* melanoma; dermoscopy; biopsy.**

Accepted Nov 12, 2014; Epub ahead of print Nov 14, 2014

Acta Derm Venereol 2015; 95: 671–675.

Susana Puig, MD, Consultant, Melanoma Unit, Dermatology Department, Hospital Clinic Barcelona, Villarroel 170, ES-08036 Barcelona. Spain. E-mail: susipuig@gmail.com, spuig@clinic.ub.es

Association of melanoma with a pre-existing naevus is still a debated subject in the literature. Melanoma seems to arise either in association with a pre-existing naevus or *de novo*, without any associated lesion.

At the histopathological level, benign naevus cells are found in association with 20–50% of melanomas (1–10). Factors, such as tumour thickness, could be responsible for a confounding role in such discrepant values, since naevus are more easily demonstrated in thinner tumours and may have been destroyed in thicker ones (5, 11).

In the diagnosis of melanocytic lesions, the role of partial biopsies has been long discussed, but there is still no consensus among practitioners of whether or not to perform a whole lesion excision for diagnosis

(12, 13). But considering the fact that as many as 50% of tumours may be in contiguity of benign naevus remnants (2), the role of partial biopsies for diagnosis of melanocytic lesions could be herein condemned, since the pathologist may only encounter benign naevus cells and be confounded in the diagnosis of melanoma. This is also one of the main reasons why step-sectioning should be the standard in the pathology procedure for the diagnosis of melanocytic lesions to avoid not correctly diagnosing a melanoma.

Dermoscopy is a non-invasive technique that increases the diagnostic accuracy in the diagnosis of melanoma (14, 15). It has been previously assessed as a tool in the recognition of naevus-associated melanoma (NA-M) in a study of 108 consecutive diagnosed thin melanomas that were evaluated for dermoscopic criteria (16). Stante et al. (16) found that NA-M show atypical pigment network and regression when compared to *de novo* melanomas (DN-M). Since it has been previously referred in the literature that NA-M are more frequent on the trunk and DN-M are more frequent on head and neck (8), and that Stante et al. evaluated a consecutive melanoma sample, not taking into account thickness, location or subtype of the melanomas, the findings of this previous study could be primarily related to the location of the melanomas rather than specific criteria for NA-M. In order to avoid this bias, we proposed a case control study of NA-M and DN-M, controlling for thickness and melanoma subtype in order to evaluate the dermoscopy of NA-M.

METHODS

This study was approved by the Ethics committee of the Hospital Clinic, Barcelona Spain.

All lesions were excised during the same time period (2008–2013) at the Melanoma Unit of Hospital Clinic, Barcelona. Pathological records evaluated by a highly experienced pathologist (Alos), with a diagnosis of melanoma and NA-M were included in this study. Benign naevomelanocytic aggregates (i.e. typical junctional, compound or dermal naevomelanocytic nevus, junctional or compound dysplastic naevi) were considered as “naevi” in this study (17–19). Only lesions with dermoscopic images were selected for the case control test set. Selected melanomas were further paired according to Breslow thickness, histopathological subtype and location (when possible) based on data available in the pathological records. The final test set consisted of 81 NA-M and 80 DN-M.

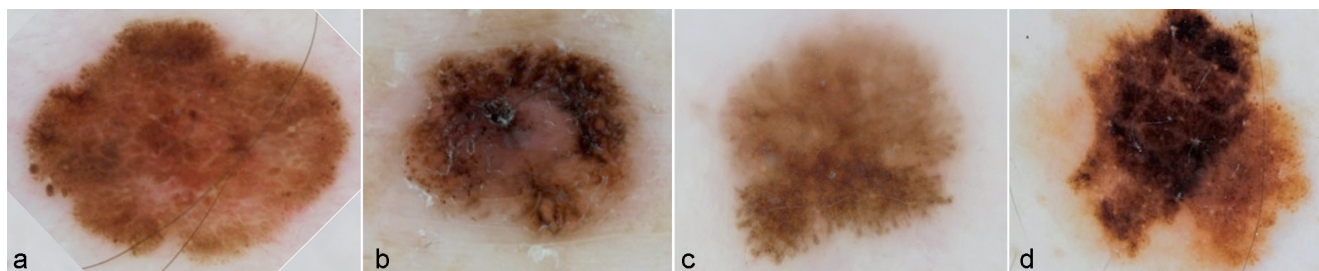


Fig. 1. Dermoscopic images of 4 melanomas arising in a naevus. Negative pigment network (+1) and globules (+1) with a Score for Algorithm I of +2 and the same for Algorithm II (a). Globules (+1) (b) and Streaks (+1) (c) with a Score for Algorithm I of +1 and the same for Algorithm II. Streaks (+1) and globules (+1) with a Score for Algorithm I of +2 and the same for Algorithm II (d). All lesions were true positives (melanomas arising in a naevus) for Algorithm I and Algorithm II.

Dermoscopy images were obtained with a DermLite Foto (3GEN), and a Canon camera (Canon Powershot G7, 10 mega pixels) and retrospectively evaluated.

The dermoscopic images were randomised to compose a test set. Two blinded dermatologists, highly experienced in dermoscopy (minimum 7-year training) were each independently asked to evaluate images on a computer screen. First, each one was asked to try to determine whether the dermoscopic image corresponded to a NA-M or a DN-M analysing the overall pattern of the lesion. If the evaluator considered the lesion to be a NA-M, they were asked to draw the area of the lesion, which they considered corresponded to the naevus (Island sign) (20).

The evaluators were further asked to evaluate the melanomas according to dermoscopic pattern analysis parameters: type of global pattern present (reticular, globular, cobblestone, starburst, homogeneous, multicomponent, unspecific), and the presence or absence of local dermoscopy features (atypical network, dots and globules, streaks (streaks and/or pseudopods) (21), blue white veil, regression (i.e., scar like depigmentation and/or peppering), hypopigmentation, blotch, vascular structures (milky red globules, comma vessels, dotted vessels, polymorphic vessels). The presence or absence of new parameters such as negative pigment network (22) and shiny white streaks were also evaluated, since polarised images for all lesions were available (23).

Further, the parameters for the ABCD Rule for dermoscopy were assessed as follows: presence of asymmetry on 1 or 2 axes ($\times 1.3$), number of sharply ending borders ($\times 0.1$), number of colours present (white, red, brown, blue-gray and black) ($\times 0.5$) and presence of different structures (network, dots, globules, streaks and structureless areas) ($\times 0.5$) and a Total Dermoscopic Score (TDS) was calculated, as described previously (24). Lesions on the face and acral sites were excluded from the evaluation of TDS score due to peculiarities in the dermoscopic diagnosis of melanomas at these sites, as described elsewhere (24). However, melanomas on the face were evaluated according to previously described dermoscopic criteria for facial areas: presence or absence of asymmetrically pigmented follicular openings, rhomboidal

structures, annular-granular pattern, homogeneous areas, fingerprint-like areas, pseudo-cysts, moth-eaten border (25, 26).

Statistical analysis

Statistical assay was performed using the SPSS version 16 program. Pearson χ^2 and symmetric measures of risk were calculated with a significant $p < 0.05$ and a confidence interval of 95%.

An algorithm for predicting NA-M was developed as follows: each dermoscopic criterion statistically positively associated with NA-M was awarded a value of +1 and each criterion statistically negatively associated with NA-M was awarded a value of (-1) (Algorithm I).

A second algorithm created included only those dermoscopic criteria statistically positively associated with NA-M, with each criterion present receiving a value of +1 (Algorithm II).

Sensitivity and specificity were calculated for each observer, algorithm I, algorithm II, and each dermoscopic criterion statistically associated with NA-M. The best cut off point of the score was selected according to the accuracy of the algorithm.

¹<https://doi.org/10.2340/00015555-2009>

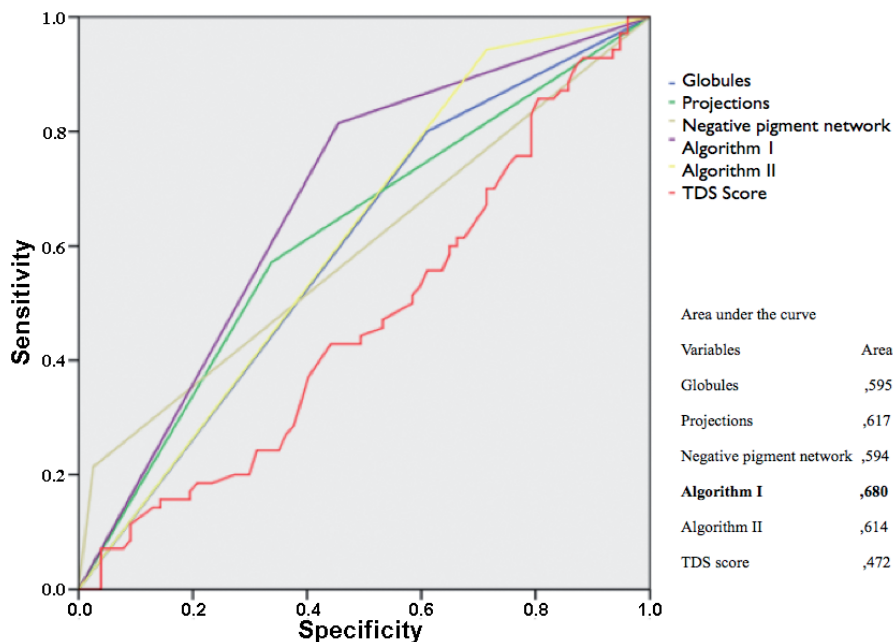


Fig. 2. Area under the curve: showing that the best diagnostic technique for naevus associated melanoma is Algorithm I.

Receiver Operating Characteristic (ROC) curve and area under the curve were calculated for each criterion associated with melanoma arising in a naevus, for each algorithm and for the TDS score.

RESULTS

The melanoma test set consisted of 161 tumours, 81 being NA-Ms and 80 DN-Ms, 49 being *in situ* (30.4%) and 112 invasive (69.6%).

In regard to histopathological subtype, 120 were superficial spreading melanoma (74.5%), 8 acral lentiginous melanoma (4.9%), 5 nodular melanoma (3.1%), 3 lentigo malignant melanoma (1.9%) and 25 *in situ* melanomas without any histopathological sub-classification (15.5%). Regarding the lesion site, 10 melanomas were located on the head, 75 affected the trunk, 58 the limbs and 9 were on acral sites. In 9 cases the primary location was not available. Unfortunately, in order to keep paired Breslow thickness between both groups, site distribution between trunk (59% NA-M and 41% DN-M) and limbs (30% NA-M and 70% DN-M) could not be completely equivalent ($p < 0.05$). The distribution of acral or facial melanomas was similar between groups (NA-M and DN-M) and there was no difference in Breslow thickness (1.38 for NA-M and 1.20 for DN-M; $p = 0.763$).

When considering the dermoscopic parameters evaluated, the presence of globules ($p < 0.018$), the presence of streaks ($p < 0.007$) and the presence of negative pigment network ($p < 0.000$) were significantly related to a NA-M (Fig 1, Table S1¹), the latter being the most specific criterion. In contrast, the presence of blue-white veil ($p = 0.046$) was related to absence of associated naevus (Fig. S1¹). No significant difference was found among the other dermoscopic criteria nor any global pattern in pattern analysis.

The sensitivity and specificity of diagnosing a NA-M is presented in Table I. Considering solely dermoscopy pattern analysis evaluation, the sensitivity for both blind evaluators was below 50% and the kappa value with histopathology of both blinded dermatologists was lower than 0.2. The sensitivity and specificity of each dermoscopic parameter significantly related to NA-M were evaluated as well. The mean TDS score for NA-Ms and DN-Ms was very similar (5.98 and 6.00 respectively; $p = 0.95$).

Two algorithms were developed: the first awarded a value of +1 to criterion, highly associated with NA-M (globules, streaks and negative pigment network), and

a value of -1 for the presence of blue white veil, which is inversely associated with melanoma arising in a naevus. A second algorithm was developed including only positive criteria with a value of +1 for each criterion (globules, streaks and negative pigment network).

The score being greater than 1 conveyed a sensitivity in the diagnosis of NA-M of 80.3% and a specificity of 54.5% for the first algorithm. In the second algorithm, which excluded the Blue White Veil parameter, there was an increase in sensitivity in detriment of specificity. But when considering the ROC curve area, for compare the performance of the proposed algorithms, TDS score and each parameter statistically associated with NA-M, the greatest contemplated area corresponded to the first algorithm (G+P+NN-V) (Fig. 2).

DISCUSSION

Only one previous study specifically analysed the dermoscopy criteria associated with melanoma arising in a naevus. They showed that atypical pigment network and regression structures were associated with melanomas arising in a naevus (16). That study was not controlled by the pathological subtype of primary melanoma nor Breslow thickness, both being possible biases for dermoscopy evaluation. When using a study set of NA-Ms and DN-Ms controlled by Breslow thickness, histopathological type and by site (at least for acral and facial), no atypical pigment network nor regression structures to be associated with the presence of an NA-M were found.

This discrepancy could be explained by the type of sample of the previous study. Stante et al. (16) evaluated 108 consecutive melanomas, 35 were NA-M and 73 DN-M. The majority of NA-M were invasive melanomas, while most of the DN-Ms were *in situ*. In the present study, *in situ* melanomas were well balanced between both groups. It has been previously suggested that regression structures may vary depending on whether the melanoma is *in situ* or invasive (27, 28). Also, in the study by Stante et al., 66% of NA-M were located on the trunk, whilst 58% of DN-Ms were located elsewhere, including the face. In the present study, at least for acral and facial sites, the distribution was well balanced, and for trunk and extremities it was less divergent. Since dermoscopic criteria may vary according to lesion site, this different distribution could also justify the absence of similar findings in our study.

Table I. Sensitivity and Specificity of distinct parameters regarding the diagnosis of naevus-associated melanoma

	1 st observer	2 nd observer	Algorithm I Score>0	Algorithm II Score>0	Globules	Streaks	Negative pigment network	Absence of Blue White Veil
Sens	48.4%	35.9%	80.3%	94.4%	78.9%	55.4%	20.3%	63.5%
Specif	49.2%	77.5%	54.5%	28.6%	39%	66.2%	97.5%	52.5%

Algorithm I: +1 (for each parameter present: globules, streaks and negative pigment network) -1 (if presence of blue white veil).

Algorithm II: +1 (for each parameter present: globules, streaks and negative pigment network).

Even though recent findings that benign dermoscopic features, such as cobblestone pattern, homogeneous pattern, typical pigment network, are more frequently associated with NA-M than DN-M (11), none of these parameters showed any difference between NA-M and DN-M in the present study. The difference in these results may relate to the sample of each study, since Di Stefani considered 373 consecutive melanomas for analysis, neither paired for Breslow thickness, nor histopathological subtype.

Nevertheless, we found the presence of globules and streaks to be related with NA-M. This seems compatible with the fact that globules are dermoscopic parameters related to melanocytic cells aggregated in nests and a common dermoscopic parameter for naevi (15). Also, streaks, according to histopathology and confocal microscopy correlation studies, seem to correspond to globular-like structures at the extremity, but with a comet star-like appearance (29, 30).

The negative pigment network (NPN) is considered to be a melanoma feature, being more frequent than previously described (31). Even though it was recently suggested that NPN and Shiny White Streaks (SWS, also known as Chrysalis structures) could be manifestations of the same histopathological finding (changes in orientation and composition of collagen in stroma), NPN and SWS refer to different dermoscopic parameters (32). NPN is described as relatively light areas making up the “cords” of the network, and darker areas filling the holes, making it appear as a negative of the pigmented network (22, 33); while SWS is described as shiny, bright, often orthogonal, unconnected white lines that do not make up a network pattern (34). It has previously been suggested that the presence of NPN is associated with in situ melanoma arising on a naevus, in 66.7% of the cases and it could represent the expression of fibrotic regression, as a reaction of a benign lesion against the malignant evolution (35). Indeed our findings support this since NPN is present in 88.0% of the NA-Ms, and represents a 9.915 greater risk of being a NA-M [CI 95% (2.182–45.049)]. It is also of note that even though negative pigment network is not a typical naevus criterion, it was the single most specific criterion for melanoma associated with a naevus (97.5%), followed by streaks (66.2%), whilst presence of globules was the most sensitive parameter (78.9%). Recently, the appearance of a negative pigment network in a pre-existing melanocytic naevus in patients under treatment with BRAF inhibitors has been associated with the diagnosis of early melanomas arising in a nevus during the treatment (36), in agreement with our finding.

The diagnosis of NA-M with dermoscopy yields different sensitivities and specificities (see Table I). It is difficult to diagnose a NA-M with the naked eye or even with broadly acknowledged dermoscopic methods, such as pattern analysis or the ABCD rule. Also, the inter-

observer reproducibility of the island sign (area supposed to correspond to the melanoma arising in a naevus) is low. Therefore, in an attempt to improve diagnosis of NA-M based on dermoscopy, we developed 2 different algorithms as described previously, with algorithm I having the best performance according to area under ROC curve. Even though the specificity of both proposed algorithms was low, both improve the dermoscopic diagnosis of NA-M, so that fewer NA-M are incorrectly diagnosed by the use of partial biopsies, when facing a melanocytic lesion with benign appearance.

This is to our knowledge the first study evaluating the dermoscopic parameters of NA-M controlled for parameters such as Breslow thickness, histopathological subtype and lesion site (in most cases), which could render bias in the results.

The results of this study show that it is difficult to distinguish NA-M and DN-M based on dermoscopy, so when facing a melanocytic lesion with a benign appearance or a benign pathological diagnosis, the presence of significantly associated features of NA-M, such as negative pigment network, globules and streaks, should raise the awareness of the dermatologist regarding the risk of not correctly diagnosing a NA-M. So if these dermoscopic criteria are present in a lesion and a naevus is not mentioned in the pathology report, the pathologist should then take a second look. Even though it is not directly analysed in our study, our results provide further evidence of the need to avoid partial biopsies and to perform step sections for pathology.

ACKNOWLEDGEMENTS

We are indebted to all our patients and their families who have always collaborated with us and who are the objective of our work; our colleagues, to our nurses, Pablo Iglesias, Daniel Gabriel and M Eugenia Moliner, who work together on a daily basis and whose effort is not always reflected in research papers. We also thank Helena Kruyer for her help with text edition.

Funding/support: The research at the Melanoma Unit in Barcelona is partially funded by grants from Fondo de Investigaciones Sanitarias P.I. 09/01393 and P.I. 12/00840, Spain; by the CIBER de Enfermedades Raras of the Instituto de Salud Carlos III, Spain, co-funded by “Fondo Europeo de Desarrollo Regional (FEDER). Unión Europea. Una manera de hacer Europa”; by the AGAUR 2009 SGR 1337 of the Catalan Government, Spain; by the European Commission under the 6th Framework Programme, Contract nr: LSHC-CT-2006-018702 (GenoMEL).

Role of the sponsors: The sponsors had no role in the design and conduct of the study; the sponsors also had no role in the collection, management, analysis and interpretation of data, as well as preparation, review or approval of the manuscript.

The authors declare no conflict of interest.

REFERENCES

1. Togawa Y, Nakamura Y, Kamada N, Kambe N, Takahashi Y, Matsue H. Melanoma in association with acquired melanocytic nevus in Japan: a review of cases in the literature.

- Int J Dermatol 2010; 49: 1362–1367.
2. Tsao H, Bevona C, Goggins W, Quinn T. The transformation rate of moles (melanocytic nevi) into cutaneous melanoma: a population-based estimate. *Arch Dermatol* 2003; 139: 282–288.
 3. Purdue MP, From L, Kahn HJ, Armstrong BK, Kricger A, Gallagher RP, et al. Etiologic factors associated with p53 immunostaining in cutaneous malignant melanoma. *Int J Cancer* 2005; 117: 486–493.
 4. Skender-Kalnenas TM, English DR, Heenan PJ. Benign melanocytic lesions: risk markers or precursors of cutaneous melanoma? *J Am Acad Dermatol* 1995; 33: 1000–1007.
 5. Sagebiel RW. Melanocytic nevi in histologic association with primary cutaneous melanoma of superficial spreading and nodular types: effect of tumor thickness. *J Invest Dermatol* 1993; 100: 322S–325S.
 6. Massi D, Carli P, Franchi A, Santucci M. Naevus-associated melanomas: cause or chance? *Melanoma Res* 1999; 9: 85–91.
 7. Bogdan I, Smolle J, Kerl H, Burg G, Boni R. Melanoma ex naevo: a study of the associated naevus. *Melanoma Res* 2003; 13: 213–217.
 8. Weatherhead SC, Haniffa M, Lawrence CM. Melanomas arising from naevi and de novo melanomas – does origin matter? *Br J Dermatol* 2007; 156: 72–76.
 9. Garcia-Cruz A, Florez A, de la Torre-Fraga C, Cruces Prado M. Observational cross-sectional study comparing Breslow thickness of melanoma arising from naevi and melanoma de novo. *Br J Dermatol* 2009; 161: 700–702.
 10. Carli P, Massi D, Santucci M, Biggeri A, Giannotti B. Cutaneous melanoma histologically associated with a nevus and melanoma de novo have a different profile of risk: results from a case-control study. *J Am Acad Dermatol* 1999; 40: 549–557.
 11. Di Stefani A, Massone C, Soyer HP, Zalaudek I, Argenziano G, Arzberger E, et al. Benign dermoscopic features in melanoma. *J Eur Acad Dermatol Venereol* 2014; 28: 799–804.
 12. Tloughan BE, Orlow SJ, Schaffer JV. Spitz nevi: beliefs, behaviors, and experiences of pediatric dermatologists. *JAMA Dermatol* 2013; 149: 283–291.
 13. Barr RJ, Linden KG, Rubinstein G, Cantos KA. Analysis of heterogeneity of atypia within melanocytic nevi. *Arch Dermatol* 2003; 139: 289–292.
 14. Kittler H, Pehamberger H, Wolff K, Binder M. Diagnostic accuracy of dermoscopy. *Lancet Oncol* 2002; 3: 159–165.
 15. Hirokawa D, Lee JB. Dermatoscopy: an overview of sub-surface morphology. *Clin Dermatol* 2011; 29: 557–565.
 16. Stante M, Carli P, Massi D, de Giorgi V. Dermoscopic features of naevus-associated melanoma. *Clin Exp Dermatol* 2003; 28: 476–480.
 17. Dadzie OE, Goerig R, Bhawan J. Incidental microscopic foci of nevic aggregates in skin. *Am J Dermatopathol* 2008; 30: 45–50.
 18. Dadzie OE, Yang S, Emley A, Keady M, Bhawan J, Mahalingam M. RAS and RAF mutations in banal melanocytic aggregates contiguous with primary cutaneous melanoma: clues to melanomagenesis. *Br J Dermatol* 2009; 160: 368–375.
 19. Kaddu S, Smolle J, Zenahlik P, Hofmann-Wellenhof R, Kerl H. Melanoma with benign melanocytic naevus components: reappraisal of clinicopathological features and prognosis. *Melanoma Res* 2002; 12: 271–278.
 20. Borsari S, Longo C, Ferrari C, Benati E, Bassoli S, Schianchi S, et al. Dermoscopic island: a new descriptor for thin melanoma. *Arch Dermatol* 2010; 146: 1257–1262.
 21. Argenziano G, Soyer HP, Chimenti S, Talamini R, Corona R, Sera F, et al. Dermoscopy of pigmented skin lesions: results of a consensus meeting via the Internet. *J Am Acad Dermatol* 2003; 48: 679–693.
 22. Menzies SW, Ingvar C, McCarthy WH. A sensitivity and specificity analysis of the surface microscopy features of invasive melanoma. *Melanoma Res* 1996; 6: 55–62.
 23. Shitara D, Ishioka P, Alonso-Pinedo Y, Palacios-Bejarano L, Carrera C, Malvey J, et al. Shiny white streaks: a sign of malignancy at dermoscopy of pigmented skin lesions. *Acta Derm Venereol* 2014; 94: 132–137.
 24. Nachbar F, Stolz W, Merkle T, Coggnetta AB, Vogt T, Landthaler M, et al. The ABCD rule of dermoscopy. High prospective value in the diagnosis of doubtful melanocytic skin lesions. *J Am Acad Dermatol* 1994; 30: 551–559.
 25. Schiffner R, Schiffner-Rohe J, Vogt T, Landthaler M, Wlotzke U, Coggnetta AB, et al. Improvement of early recognition of lentigo maligna using dermoscopy. *J Am Acad Dermatol* 2000; 42: 25–32.
 26. Menzies SW, Ingvar C, McCarthy WH. An atlas of surface microscopy of pigmented skin lesions. : McGraw-Hill, 1996.
 27. Seidenari S, Ferrari C, Borsari S, Benati E, Ponti G, Bassoli S, et al. Reticular grey-blue areas of regression as a dermoscopic marker of melanoma in situ. *Br J Dermatol* 2010; 163: 302–309.
 28. Bassoli S, Borsari S, Ferrari C, Giusti F, Pellacani G, Ponti G, et al. Grey-blue regression in melanoma in situ: evaluation on 111 cases. *J Skin Cancer* 2011; 2011: 180980.
 29. Pellacani G, Longo C, Malvey J, Puig S, Carrera C, Segura S, et al. In vivo confocal microscopic and histopathologic correlations of dermoscopic features in 202 melanocytic lesions. *Arch Dermatol* 2008; 144: 1597–1608.
 30. Rezzè GG, Scramim AP, Neves RI, Landman G. Structural correlations between dermoscopic features of cutaneous melanomas and histopathology using transverse sections. *Am J Dermatopathol* 2006; 28: 13–20.
 31. Pizzichetta MA, Talamini R, Marghoob AA, Soyer HP, Argenziano G, Bono R, et al. Negative pigment network: an additional dermoscopic feature for the diagnosis of melanoma. *J Am Acad Dermatol* 2013; 68: 552–559.
 32. Botella-Estrada R, Requena C, Traves V, Nagore E, Guillen C. Chrysalis and negative pigment network in Spitz nevi. *Am J Dermatopathol* 2012; 34: 188–191.
 33. Bassoli S, Ferrari C, Borsari S, Giusti F, Magnoni C, Pellacani G, et al. Negative pigment network identifies a peculiar melanoma subtype and represents a clue to melanoma diagnosis: a dermoscopic study of 401 melanomas. *Acta Derm Venereol* 2013; 93: 650–655.
 34. Shitara D, Ishioka P, Alonso-Pinedo Y, Palacios-Bejarano L, Carrera C, Malvey J, et al. Shiny white streaks: a sign of malignancy at dermoscopy of pigmented skin lesions. *Acta Derm Venereol* 2014; 94: 132–137.
 35. Seidenari S, Ferrari C, Borsari S, Bassoli S, Cesinaro AM, Giusti F, et al. The dermoscopic variability of pigment network in melanoma in situ. *Melanoma Res* 2012; 22: 151–157.
 36. Debarbieux S, Dalle S, Depaepe L, Poulalhon N, Balme B, Thomas L. Second primary melanomas treated with BRAF blockers: study by reflectance confocal microscopy. *Br J Dermatol* 2013; 168: 1230–1235.