

## QUIZ SECTION

### Vegetating Inguinal and Perianal Lesions: A Quiz

**Louai A. Salah**

Department of Dermatology and Venereology, Sahlgrenska University Hospital, SE-413 45 Gothenburg, Sweden and Ministry of Health, Jeddah, Kingdom of Saudi Arabia. E-mail: louai.salah@vgregion.se

A 72-year-old woman was referred to the dermatology department with a one-month history of non-itching skin lesions in the groin. The rash had been initially diagnosed as impetigo as the lesions started as pustules. However, no improvement was noted on antibiotic treatment. The lesions changed to become larger, warty and vegetating (Fig. 1). Smaller lesions were seen perianally. No vesicles or bullae were noted. She denied loss of appetite or weight loss. There was no relevant drug history.

Laboratory tests showed erythrocyte sedimentation rate of 80 mm/h (normal

<28 mm/h) and positive haemoglobin in one out of 3 foecal samples. A gastrointestinal investigation including endoscopy was negative.

A skin biopsy was taken (Fig. 2). At the following visit, the patient developed papules and early exophytic plaques on the dorsal side of the tongue.

*What is your diagnosis? See next page for answer.*

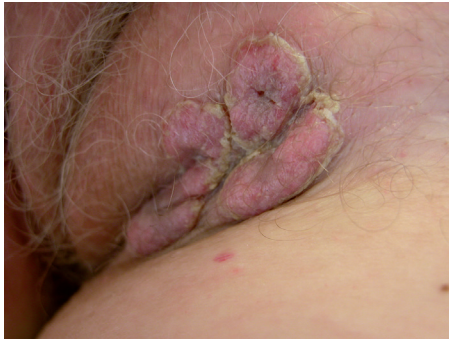

Fig. 1. Vegetating red plaques in the left and right intertriginous regions.

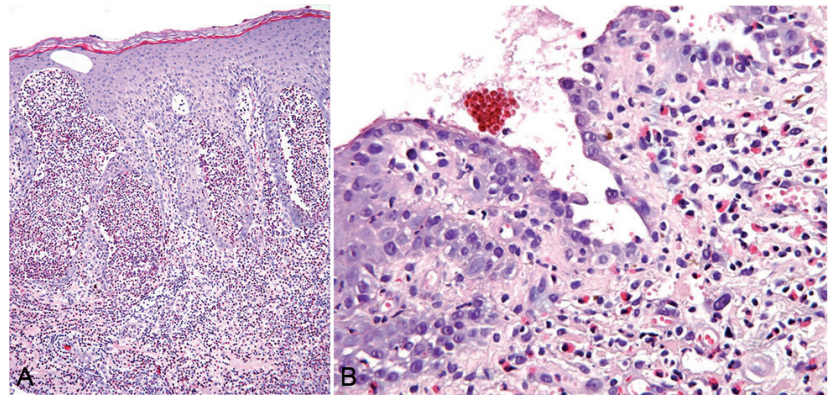


Fig. 2. Histological picture (H&E staining): (A) Prominent acanthosis with intraepidermal abscesses. (B) At higher magnification, suprabasal clefts, rounded acantholytic cells and eosinophilic infiltrate are seen.

## ANSWERS TO QUIZ

**Vegetating Inguinal and Perianal Lesions: A comment**

Acta Derm Venereol

**Diagnosis: Pemphigus Vegetans, Hallopeau Type**

Based on the clinical and laboratory findings, the above-mentioned diagnosis was actively made and our patient was treated locally with Dermovate cream (clobetasol) under occlusion and a 10-day course of oral cefadroxil was given. Likewise, oral lesions were treated with clobetasol gel. By the end of the 2-month period, oral and intertriginous lesions had completely cleared.

Pemphigus vegetans (PV) is an extremely rare disorder in Europe. Its incidence is reported to be higher in North Africa and more specifically Tunisia (1). Nevertheless, to our knowledge, this is the first reported case of pemphigus vegetans in the Nordic countries (1). While warmer climates and strong UV radiation are thought to be implicated in increased pemphigus vulgaris expression, the opposite might be specifically true in explaining the rarity of pemphigus vegetans in colder countries with higher latitude like Sweden (2).

Two types of PV have been described: Hallopeau and Neumann. Distinction is made based on their clinical courses, relapses and clinical and histological features (3, 4). Hallopeau type usually starts with grouped and annular pustules while Neumann type arises with bullae and erosions. Both tend to become undistinguishable late in their course with purple vegetative lesions studded with pustules (4). Although eosinophilic microabscesses are found more frequently in early lesions of Hallopeau in comparison to Neumanns, no significant histological disparity between both entities has been found in well-developed lesions. Characteristic histological picture of both types includes epithelial hyperplasia, suprabasal cleft and acantholysis (see Fig. 2) (5). Moreover, direct and indirect immunofluorescence data are typically positive for IgG and C3 directed towards intercellular cement substance (results not shown). Autoantibodies against desmoglein 3 are commonly detected (in our case a titer > 100 units/ml was observed) whereas anti-desmoglein 1 autoantibodies are only occasionally found (1, 6, 7).

While Razzaque & Blose (3) described a patient with Hallopeau type having vesicles in truncal distribution in addition to axillae and groin, subsequent reports including our case had lesions mainly in intertriginous areas (8). The propensity of the disease to develop specifically in intertriginous zones, also illustrated in Fig. 3, has been hypothesised in many reports to be attributed to occlusion and secondary bacterial infection (9). However, the exact pathogenesis of the diseases is yet to be discovered.

The prognosis of each type of PV has been reported to differ significantly, with a better response to therapy, faster recovery and fewer recurrences in Hallopeau type (4, 10).

The mainstay of treatment is corticosteroids. While our case responded primarily to topical steroid with the addition of a short course of first generation cephalosporin, inconsistent response to topical therapy has rather been reported in the literature, especially in the Neuman type (8,

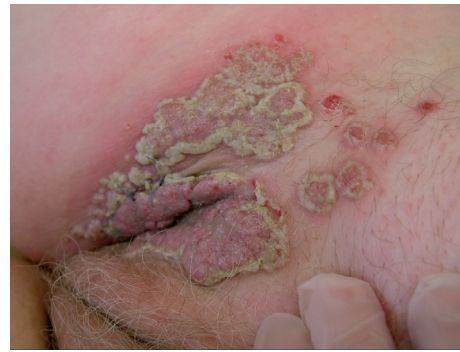

Fig. 3. Vegetating lesions in the patient's right groin.

11). In fact, healing of the lesions in our case is believed to be mainly due to anti-inflammatory action of steroids, rather than the antibiotic course. Accordingly, other systemic immunosuppressive drugs have been proposed to induce remission in other studies including dapsone, etretinate, azathioprine and cyclophosphamide with various response and disease-free periods (8, 11).

## ACKNOWLEDGEMENT

I am indebted to Dr. Ingrid Rossmann-Ringdahl and Prof. Jan Faergemann for valuable advice and guidance.

## REFERENCES

- Zaraa I, Sellami A, Bouguerra C, Sellami M, Chelly I, Zitouna M, et al. Pemphigus vegetans: a clinical, histological, immunopathological and prognostic study. *J Eur Acad Dermatol Venereol* 2011; 25: 1160–1167.
- Kyriakis KP, Vareltzidis AG, Tosca AD. Environmental factors influencing the biologic behavior of patterns of pemphigus vulgaris: epidemiologic approach. *Int J Dermatol* 1995; 34: 181–185.
- Razzaque AA, Blose DA. Pemphigus vegetans. Neumann type and Hallopeau type. *Int J Dermatol* 1984; 23: 135–141.
- Lever WF. Pemphigus and pemphigoid: Charles C Thomas, 1965.
- Jansen T, Messer G, Meurer M, Plewig G. Pemphigus vegetans Eine historische Betrachtung. *Hautarzt* 2001; 52: 504–509.
- Nelson CG, Apisarnthanarax P, Bean SF, Mullins JF. Pemphigus vegetans of Hallopeau: immunofluorescent studies. *Arch Dermatol* 1977; 113: 942.
- Neumann HM, Faber WR. Pyodermite végétante of Hallopeau: Immunofluorescence studies performed in an early disease stage. *Arch Dermatol* 1980; 116: 1169–1171.
- Ichimiya M, Yamamoto K, Muto M. Successful treatment of pemphigus vegetans by addition of etretinate to systemic steroids. *Clin Exp Dermatol* 1998; 23: 178–180.
- Nanda S, Grover C, Garg V, Reddy B. Pemphigus vegetans of hallopeau. *Indian J Dermatol* 2005; 50: 166.
- Frühwald R. Pemphigus vegetans: monographisch dargestellt: Voss, 1915.
- Rackett SC, Rothe MJ, Hoss DM, Grin-Jorgensen CM, Grant-Kels JM. Treatment – resistant pemphigus vegetans of the scalp. *Int J Dermatol* 1995; 34: 865–866.