

CLINICAL REPORT

Atopic Diathesis in Hypohidrotic/Anhidrotic Ectodermal Dysplasia

Hanako KOGUCHI-YOSHIOKA¹, Mari WATAYA-KANEDA¹, Mizuki YUTANI¹, Hiroyuki MUROTA¹, Hajime NAKANO², Daisuke SAWAMURA² and Ichiro KATAYAMA¹

Departments of Dermatology, ¹Course of Integrated Medicine, Graduate School of Medicine, Osaka University, Osaka, and ²Hirosaki University Graduate School of Medicine, Hirosaki, Japan

Recently, patients with hypohidrotic/anhidrotic ectodermal dysplasia (H/AED) have been reported to have a higher prevalence of symptoms suggestive of atopic disorders than the general population. To better understand atopic diathesis in H/AED, 6 cases of clinically or genetically diagnosed H/AED were examined. The following criteria were evaluated with patient consent: sweating, blood test results, histopathology and filaggrin staining. Five of 6 H/AED cases displayed atopic dermatitis-like manifestations, and 3 of these 5 cases experienced periorbital lesions. Sweat ducts were not histopathologically observed, and filaggrin staining was similar to normal subjects. Serum IgE was elevated in 2 of the 3 patients. H/AED patients tended to present with atopic dermatitis-like eruptions with characteristics potentially indicative of periorbital lesions. Atopic diathesis in H/AED appeared not to be associated with filaggrin. We could speculate that hypohidrosis or anhidrosis itself might impair skin barrier function and contribute to atopic diathesis. Key words: hypohidrotic/anhidrotic ectodermal dysplasia; hypohidrosis/anhidrosis; atopic dermatitis; periorbital eczema.

Accepted Sep 30, 2014; Epub ahead of print Oct 1, 2014

Acta Derm Venereol 2015; 95: 476–479.

Mari Wataya-Kaneda, MD, PhD, Department of Dermatology, Course of Integrated Medicine, Graduate School of Medicine, Osaka University, 2-2, Yamadaoka, Suita-shi, Osaka, 565-0871, Japan. E-mail: mkaneda@derma.med.osaka-u.ac.jp

Hypohidrotic/anhidrotic ectodermal dysplasia (H/AED) is a rare genodermatosis characterised by abnormal development of the sweat glands, teeth, and hair. Using questionnaires, Mark et al. (1) recently demonstrated that children with ED syndromes have higher prevalence of symptoms suggestive of atopic disorders than the general paediatric population. However, few reports have described the characteristics of H/AED skin lesions from a clinical perspective. Our aim was to clarify atopic diathesis, the tendency to develop one or more of the atopic diseases, in H/AED. We also evaluated filaggrin expression in the skin of patients with H/AED.

MATERIALS AND METHODS

Patients

Six patients with H/AED at Osaka University Hospital were examined (5 men and 1 woman; median age 12.5, range 1–35) (Patient Nos. 1–5 were clinically diagnosed with H/AED based on the triad signs of H/AED, and patient No. 6 was genetically diagnosed via a causative gene mutation).

Measurement of sudomotor function

Sweating was evaluated in 2 cases via starch-iodide paper or the quantitative sudomotor axon reflex test (Q-SART). Starch-iodide paper was attached to the palm. Dark spots on the patient's palm result from reaction between starch and iodide in the presence of water from the sweat droplets, and these spots were compared to those on a control. Q-SART was performed as previously described (2). Briefly, a 2 mA current was applied for 5 min together with 10% acetylcholine to determine axon reflex-mediated sweating responses during acetylcholine iontophoresis.

Histopathology

Four-mm punch biopsies were collected from anhidrotic areas of in 3 patients. Hematoxylin-eosin or immunoperoxidase staining of paraffin-embedded sections was performed. A monoclonal mouse anti-human filaggrin antibody (Santa Cruz Biotechnology, Santa Cruz, California, USA) was used at a 1:450 dilution. Antigen retrieval was performed by heating sections under pressure for 10 min in 10 mM sodium citrate buffer, pH 6.0. Filaggrin stained H/AED skin was compared with filaggrin-related atopic dermatitis specimens and normal skin samples.

Ethical issue

The genetic analysis was performed at Hirosaki University Faculty of Medicine under the approval of its ethics committee. Written informed consent from the participant (patient No. 6) was obtained at Osaka University Faculty of Medicine. We were permitted to use the database of the result of genetic analysis by the ethics committee of the Osaka University Faculty of Medicine.

RESULTS

The patients' characteristics are detailed in Table I. Five of the 6 cases had skin lesions resembling AD, such as dry skin, recurring itchy erythema, lichenification, or hyperpigmentation (Fig. 1). These 5 cases met Hanifin & Rajka's (3) diagnostic criteria for AD. Three of these 5 patients (patient Nos. 2 [Fig. 1a], 4, and 5 [Fig. 1b]), displayed recurring eczema on peri-

Table I. Patients' characteristics

Pat. No.	Age/sex	Hair	Teeth	Sweat	Skin lesions	Other clinical signs	Evaluation of sweating	Histopathology	Serum IgE (IU/ml)	Family history	Genetic mutation
1	1/M	+	+	+	Dry skin Erythema on the cheeks	-	N/A	No sweat ducts (Fig. 3a)	N/A	Mother and a maternal uncle with AD	N/A
2	10/M	+	+	+	Pigmentation on the periorbital sites (Fig. 1a)	-	N/A	N/A	2,800	Negative	N/A
3	2/M	+	+	+	Eczema on the cubital (Fig. 1c) and popliteal regions	-	Starch-iodide paper (Fig. 2)	N/A	137	Mother with hypohidrosis and hay fever A brother and a sister with asthma	N/A
4	35/M	+	+	+	Eczema on the whole body	-	N/A	No sweat duct (Fig. 3b)	4,500	A maternal uncle with H/AED	N/A (x-linked s/o)
5	6/M	+	+	+	Lichenification especially on the periorbital sites (Fig. 1b)	Short stature	N/A	N/A	N/A	A maternal uncle with H/AED	N/A (x-linked s/o)
6	21/F	-	-	+	-	-	Q-SART	No sweat ducts	N/A	Father with H/AED	EDARADD

N/A, not available; AD: atopic dermatitis; H/AED: hypohidrotic/anhidrotic ectodermal dysplasia; +: feature present; -: within normal clinical limits; s/o: suspect of.

orbital sites. Serum IgE levels were elevated in 2 of the 3 patients having a blood test (patient Nos. 2–4) (normal range: <300 IU/ml) (4). Two patients had a positive family history of allergic disorders, including AD, asthma, or hay fever. Starch-iodide paper sweat test results demonstrated minimal sweating responses (Fig. 2a) compared with the normal control (Fig. 2b). For patient No. 6, the Q-SART measurement results were 0 mg/cm² on the abdomen and 0.18 mg/cm² on the palm. Q-SART allows us to quantitate the amount of sweating and distinguish between anhidrotic and hypohidrotic regions in the patient. Mutational analysis using genomic DNA extracted from blood leukocytes of patient No. 6 revealed a heterozygous c.157insA

mutation in the EDARADD gene, one of the causative genes of H/AED. Skin biopsies from anhidrotic areas of 3 patients (patient Nos. 1, 4, 6) showed normal epidermis but no sweat ducts in the dermis or subcutaneous adipose tissue (Fig. 3a, b). Immunohistochemical anti-filaggrin staining of patient skin specimens (Fig. 3a, b, lower parts) showed comparable staining to the normal control (Fig. 3d); staining was not reduced, unlike in filaggrin-related AD specimens (Fig. 3c).

DISCUSSION

Similar to previous reports (1, 5), our H/AED cases frequently suffered from skin lesions that resembled AD.

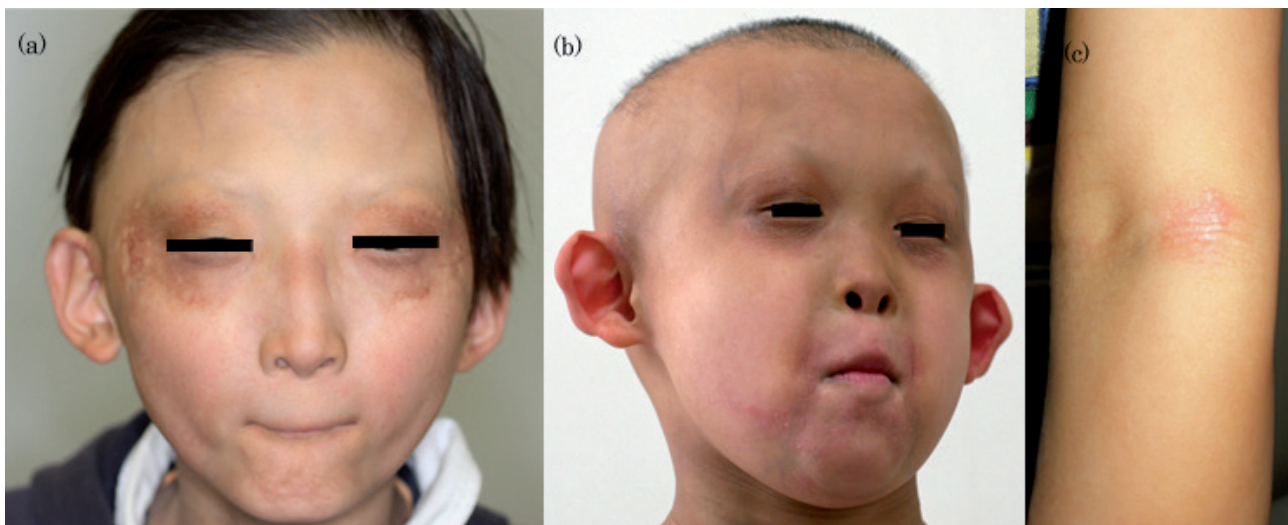


Fig. 1. (a) Patient 2 presented with hyperpigmentation at periorbital sites. (b) Patient 5 experienced lichenification and pigmentation on periorbital regions. (c) Patient 3 displayed recurring itchy erythema on the cubital fossa. A written permission is given to publish this figures.

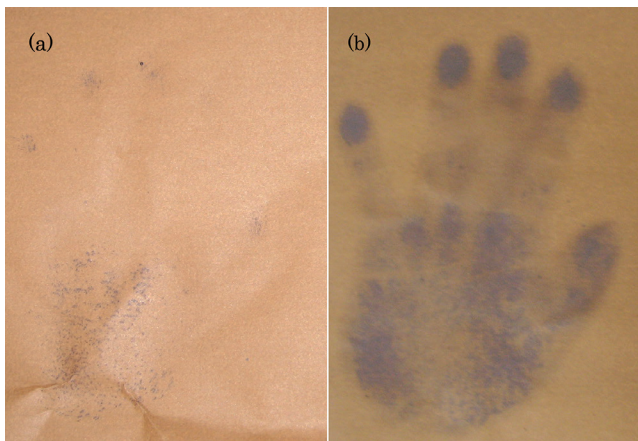


Fig. 2. Starch-iodide paper test; dark spots on the patient's palm (a) resulting from the reaction between starch and iodide in the presence of water from sweat droplets were markedly reduced compared with the control (b).

Three of 5 patients with AD-like eczema experienced eruptions at periorbital sites. According to Feser et al., (6) the following are significant risk factors for periorbital eczema; female, atopic skin diathesis and ≥ 40 years. Three patients with periorbital eczema were male and under 40 years of age; so in all the 3 risk factors which Feser et al. described, atopic skin diathesis was left. We could speculate that atopic diathesis in these H/AED patients might be attributed to periorbital dermatitis, which could be one of the characteristics of H/AED skin lesions.

Two of the 6 cases had a positive family history of allergic disorders, including AD, asthma, or hay fever. In addition, 2 of the 3 patients having a blood test displayed a high serum IgE level; Davis & Solomon (5) reported

that IgE levels in patients with H/AED were higher than those of a control group, with a significance level of $p=0.01$. Recent knowledge suggests that barrier dysfunction is the primary cause of AD and that increased IgE levels might be a secondary phenomenon (7). Speculatively, a defective skin barriers in patients with H/AED could be associated with increased IgE levels.

It is unclear, however, what causes the impaired skin barrier function in H/AED patients. Mutations in the gene-encoding filaggrin are a major genetic predisposing factor for AD (8). Angelova-Fischer et al. (9) demonstrated that the filaggrin mutation carriers had significantly reduced total and percentage amount of ceramide 4 compared with the wild-type. In addition, Jungerstedt et al. (10) reported similar ceramide profiles in H/AED and AD patients. However, our results suggest no association between H/AED and filaggrin although filaggrin status were not available for all the patients because some patients disagreed with several kinds of tests, or stopped follow-up visit.

Impaired sweating was recently implicated as a cause of barrier dysfunction in AD (2, 11). Various reports indicate reduced sweating responses in AD patients compared with non-atopic controls (2, 11, 12). It is also reported that patients with AD have reduced amount of dermcidin in sweat, which is one of the human antimicrobial peptides secreted into sweat (13). This might contribute to the high susceptibility of AD patients to skin infections and to altered bacterial skin colonisation. Although filaggrin data were not reported in these studies, it could be said that most of these AD cases exhibiting defective sweating were unrelated to filaggrin, taking into the frequency of filaggrin mutation

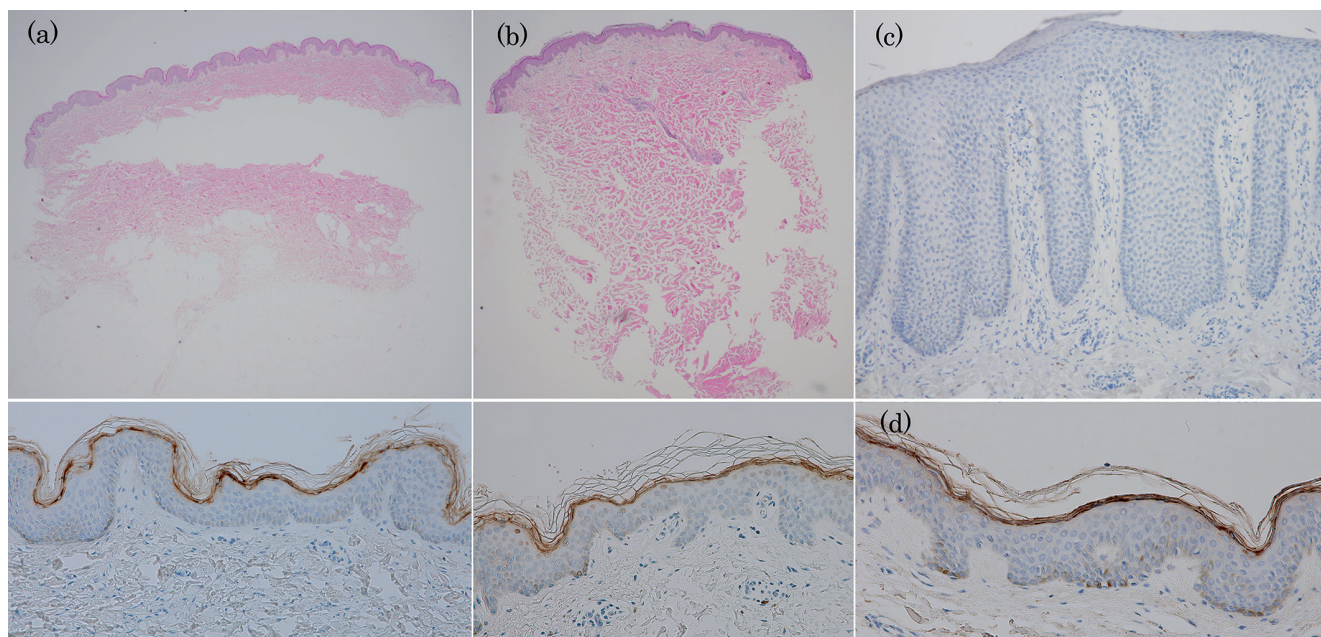


Fig. 3. No sweat ducts were histopathologically observed in an anhidrotic area of patient 1 (a) and 4 (b). Filaggrin staining in patient 1 (a, lower part) and 4 (b, lower part) was similar to that of the normal control (d). Staining was not reduced unlike the staining of filaggrin-related atopic dermatitis specimen (c).

account (for example, the percentage of Japanese AD patients with filaggrin mutation is about 25% (14)). In addition, Watabe et al. (15) demonstrated that among natural moisturising factors, the levels of lactate, urea, sodium, and potassium were significantly lower in anhidrotic areas of patients with acquired idiopathic generalised anhidrosis or segmental anhidrosis than in adjacent hidrotic areas. They concluded that these factors in sweat played a crucial role in maintaining the hydration state of stratum corneum.

H/AED is a rare genetic disease, so it is difficult to statistically prove that reduced sweat production is underlying cause for atopic eczema, but taking the above findings together, we could predict that hypohidrosis/anhidrosis itself might contribute to impaired barrier function, resulting in AD diathesis and secondarily to elevated IgE levels in patients with H/AED.

Consistent with previous reports, our H/AED patients tended to present with skin manifestations that were indistinguishable from AD. Our clinical evaluation indicated that periorbital dermatitis could be characteristics of H/AED skin lesions. H/AED appears to be not associated with filaggrin. In addition, it could be speculated that hypohidrosis or anhidrosis itself might impair the skin barrier and contribute to atopic diathesis in H/AED.

The authors declare no conflict of interest.

REFERENCES

1. Mark BJ, Becker BA, Halloran DR, Bree AF, Sindwani R, Fete MD, et al. Prevalence of atopic disorders and immunodeficiency in patients with ectodermal dysplasia syndromes. *Ann Allergy Asthma Immunol* 2012; 108: 435–438.
2. Kijima A, Murota H, Matsui S, Takahashi A, Kimura A, Kitaba S, et al. Abnormal axon reflex-mediated sweating correlates with high state of anxiety in atopic dermatitis. *Allergol Int* 2012; 61: 469–473.
3. Hanifin JM, Rajka G. Diagnostic features of atopic dermatitis. *Acta Derm Venereol* 1980; Suppl. 92: 44–47.
4. Kuwana M. IgE. *J Jpn Med Assoc* 2006; 135: S149.
5. Davis JR, Solomon LM. Cellular immunodeficiency in anhidrotic ectodermal dysplasia. *Acta Derm Venereol* 1976; 56: 115–120.
6. Feser A, Plaza T, Vogelgsang L, Mahler V. Periorbital dermatitis – a recalcitrant disease: causes and differential diagnoses. *Br J Dermatol* 2008; 159: 858–863.
7. Kabashima K. New concept of the pathogenesis of atopic dermatitis: interplay among the barrier, allergy, and pruritus as a trinity. *J Dermatol Sci* 2013; 70: 3–11.
8. Palmer CN, Irvine AD, Terron-Kwiatkowski A, Zhao Y, Liao H, Lee SP, et al. Common loss-of-function variants of the epidermal barrier protein filaggrin are a major predisposing factor for atopic dermatitis. *Nat Genet* 2006; 38: 441–446.
9. Angelova-Fischer I, Mannheimer AC, Hinder A, Ruether A, Franke A, Neubert RH, et al. Distinct barrier integrity phenotypes in filaggrin-related atopic eczema following sequential tape stripping and lipid profiling. *Exp Dermatol* 2011; 20: 351–356.
10. Jungersted JM, Høgh JK, Hellgren LI, Agner T, Jemec GB. Ceramide profile in hypohidrotic ectodermal dysplasia. *Clin Exp Dermatol* 2012; 37: 153–155.
11. Eishi K, Lee JB, Bae SJ, Takenaka M, Katayama I. Impaired sweating function in adult atopic dermatitis: results of the quantitative sudomotor axon reflex test. *Br J Dermatol* 2002; 147: 683–688.
12. Shiohara T, Doi T, Hayakawa J. Defective sweating responses in atopic dermatitis. *Curr Probl Dermatol* 2011; 41: 68–79.
13. Paulmann M, Arnold T, Linke D, Ozdirekcan S, Kopp A, Gutsmann T, et al. Structure-activity analysis of the dermcidin-derived peptide DCD-1L, an anionic antimicrobial peptide present in human sweat. *J Biol Chem* 2012; 287: 8434–8443.
14. Nomura T, Akiyama M, Sandilands A, Nemoto-Hasebe I, Sakai K, Nagasaki A, et al. Prevalent and rare mutations in the gene encoding filaggrin in Japanese patients with ichthyosis vulgaris and atopic dermatitis. *J Invest Dermatol* 2009; 129: 1302–1305.
15. Watabe A, Sugawara T, Kikuchi K, Yamasaki K, Sakai S, Aiba S. Sweat constitutes several natural moisturizing factors, lactate, urea, sodium, and potassium. *J Dermatol Sci* 2013; 72: 177–182.