

CLINICAL REPORT

Desmoplakin Mutations with Palmoplantar Keratoderma, Woolly Hair and Cardiomyopathy

Manuela PIGORS¹, Agnes SCHWIEGER-BRIEL¹, Rodica COSGAREA², Adriana DIACONEASA³, Leena BRUCKNER-TUDERMAN¹, Thilo FLECK⁴ and Cristina HAS¹

¹Department of Dermatology, Medical Center – University Freiburg, Freiburg, Germany, ²Department of Dermatology, University of Medicine and Pharmacy “Iuliu Hatieganu” Cluj-Napoca, ³Dermatology Ambulatory Care Center, Children’s Emergency Hospital “Grigore Alexandrescu”, Bucharest, Romania and ⁴Department of Congenital Heart Disease and Paediatric Cardiology, University Heart Centre, Freiburg, Germany

Mutations in genes encoding for desmosomal components are associated with a broad spectrum of phenotypes comprising skin and hair abnormalities and account for 45–50% of cases of arrhythmogenic right ventricular cardiomyopathy. Today, more than 120 dominant and recessive desmoplakin (*DSP*) gene mutations have been reported to be associated with skin, hair and/or heart defects. Here we report on 3 cases with yet unreported *DSP* mutations, c.7566_7567delAAinsC, p.R2522Sfs*39, c.7756C>T, p.R2586*, c.2131_2132delAG and c.1067C>A, p.T356K, that were associated with variable woolly hair or hypotrichosis, palmoplantar keratoderma, and cardiac manifestations. In addition, we review and summarise the clinical features and *DSP* mutations of the patients described in the literature, which illustrates the complexity of this group of disorders and of their genotype–phenotype correlations, which cannot be easily predicted. Early diagnosis is crucial and cardiac examinations have to be performed on a regular basis. Key words: desmoplakin; DSP; keratoderma; woolly hair; skin fragility; striate palmoplantar keratoderma.

Accepted Sep 16, 2014; Epub ahead of print Sep 17, 2014

Acta Derm Venereol 2015; 95: 337–340.

Prof. Dr. Cristina Has, Department of Dermatology, Medical Center – University Freiburg, Hauptstrasse 7, DE-79104 Freiburg, Germany. E-mail: cristina.has@uniklinik-freiburg.de

Desmosomes are intercellular junctions that anchor intermediate filaments to the plasma membrane, providing mechanical resistance to tissues, and interacting with signalling cascades to regulate tissue homeostasis (1). Mutations in genes encoding desmosomal components, including plakophilin 1, desmoplakin, plakoglobin, desmogleins 1 and 4, desmocollins 2 and 3, and corneodesmosin are associated with a broad spectrum of phenotypes comprising skin (e.g. fragility, barrier dysfunction, palmoplantar keratoderma) and hair abnormalities, which were recently reviewed (2–5). Moreover, desmosomal gene mutations account for 45–50% of cases of arrhythmogenic right ventricular cardiomyopathy (3).

Today, more than 120 dominant and recessive desmoplakin gene (*DSP*) mutations have been reported to be associated with skin, hair and/or heart defects (HGMD professional 2014.2). The classification of these phenotypes and the genotype–phenotype correlations are challenging, partly because in the literature, different terms are used to designate disorders which comprise similar clinical features (see Table SI¹). Hence, the desmoplakin associated cutaneous phenotypes are classified as epidermolysis bullosa, as palmoplantar keratoses or as hypotrichoses, depending on the predominant features. Besides, in most cases the precise consequences of the mutations and the molecular pathology remain elusive because expression and functional studies are lacking. Absence of desmoplakin or of its tail gives rise to acantholytic epidermolysis bullosa (AEB), which leads to early demise (6). In contrast, haploinsufficiency and various combinations of missense, loss-of-function and truncating mutations are associated with cardiocutaneous syndromes, a phenotypic spectrum including skin fragility, striate palmoplantar keratoderma, variable degrees of hair involvement ranging from complete alopecia or hypotrichosis, to woolly hair, and cardiac anomalies (2) (Table SI¹). Plakoglobin and desmocollin 2 gene mutations lead to overlapping cardiocutaneous phenotypes with those caused by *DSP* mutations (5).

Here we report on 3 cases with yet unreported *DSP* mutations that were associated with woolly hair or hypotrichosis, palmoplantar keratoderma, and variable cardiac manifestations.

CASE REPORTS

The male index case 1 presented at the age of 5 years with hypotrichosis (Fig. 1a), striate and focal keratoderma on palms and soles (Fig. 1b, c), and keratotic papules on the dorsal aspects of the hands, arms and lower legs (Fig. 1d). A cardiac ultrasound at the age of 6 years revealed no signs of cardiac involvement. His parents are of Romanian origin, healthy and not consanguineous by report and there was no other affected member in the family.

¹<https://doi.org/10.2340/00015555-1974>

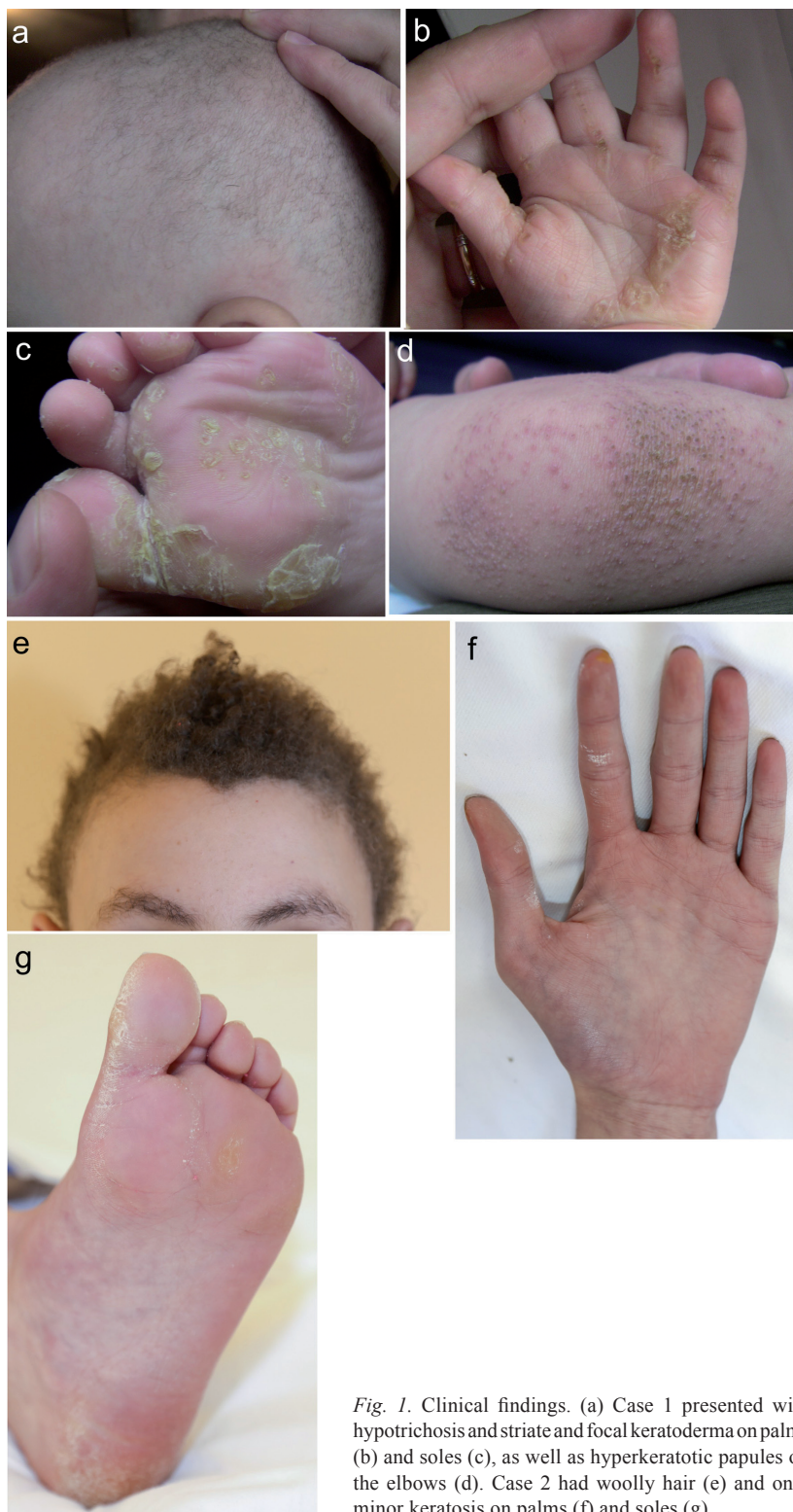


Fig. 1. Clinical findings. (a) Case 1 presented with hypotrichosis and striate and focal keratoderma on palms (b) and soles (c), as well as hyperkeratotic papules on the elbows (d). Case 2 had woolly hair (e) and only minor keratosis on palms (f) and soles (g).

Case 2 was a 14-year-old male born without any abnormalities after an uneventful pregnancy. Initially, his hair appeared normal. However, after the shedding of neonatal hair, new hair grew extremely slowly and scarce, with a woolly appearance. At age 13, the patient

suffered a sudden episode of acute heart failure with need of resuscitation and implantation of an extracorporeal life support device. He was diagnosed with dilated cardiomyopathy with severe left ventricular insufficiency. Recently, a cardiac transplant was successfully performed. On clinical examination, woolly hair and mild focal palmoplantar keratosis were noted (Fig. 1e–g).

Case 3 was the 10-year-old sister of case 2. She had no scalp hair at birth, and later, hair grew sparse. Because of the severe cardiac disease in her brother, she was carefully examined and found to have a dilated cardiomyopathy with an ejection fraction of 35–40%. Clinical examination revealed mild focal plantar keratoses and hypotrichosis. The family history of the siblings revealed curly hair in many members of the maternal family. The mother also had very curly hair and suffered from mild bradycardia. She had suffered 2 miscarriages early in the course of the pregnancy. The patients' father had suffered a myocardial infarction as a young man and had passed away from a malignant gastrointestinal carcinoma in his thirties.

Following written informed consent, genomic DNA was extracted from EDTA-blood and amplification and sequencing of *DSP* (NM_004415.2) was performed, as described in (7). The study was approved by the ethics committee of the University of Freiburg and was conducted according to the Declaration of Helsinki Principles.

In case 1, a deletion-insertion mutation, c.7566_7567delAAinsC, p.R2522Sfs*39 and a nonsense mutation, c.7756C>T, p.R2586*, in exon 24 of *DSP*, both in a heterozygous state were disclosed (Fig. S1a¹). The father was found to be a heterozygous carrier of the deletion-insertion mutation while the nonsense mutation was found in a heterozygous manner in the mother's DNA. In cases 2 and 3, c.1067C>A, p.T356K in exon 9 and c.2131_2132delAG, p.S711Cfs*4 at the acceptor splice site of exon 16 of *DSP* were found in a heterozygous state (Fig. S1b¹). The mother was a heterozygous carrier of the deletion. To the best of our knowledge, all these variants have

not been reported before (HGMD Professional 2014.2, 1000 genome project and Exome variant server). The mutations c.7566_7567delAAinsC, p.R2522Sfs*39, c.7756C>T, p.R2586* and c.2131_2132delAG lead to premature termination codons, and are therefore pathogenic. Different outcomes are conceivable – mRNA decay, loss of protein expression, or expression of reduced amounts of C-terminally truncated desmoplakin molecules. The substitution, c.1067C>A, p.T356K, replaces a highly conserved threonine in the helix domain between the spectrin 2 and 3a repeats of desmoplakin and is predicted to be the cause of the disease (Mutation Taster score 0.99, PolyPhen2 score 1). Because of the mild skin anomalies, no skin biopsies were performed and therefore the exact consequences of the mutations on protein level remain elusive.

DISCUSSION

The cases described here illustrate the challenges in the diagnosis and management of desmosomal disorders. While hypotrichosis and palmoplantar keratoderma were early features in case 1, there were no signs of cardiac disease at this point in time. The absence of skin fragility strongly suggests that residual expression of truncated desmoplakin accounts for a partial function of desmosomes. Since both mutations, p.R2522Sfs*39 and p.R2586* are located within the C-terminus of desmoplakin, it is highly probable that they will lead to the formation of truncated polypeptides. The same effect was shown for the deletion c.7623delG, p.K2542Sfs*19 (8) that is in close proximity to the mutations reported in this study, whereas the mutation, c.7248delT was associated with AEB (9). The C-terminus of desmoplakin is crucial for its interaction with the keratin intermediate filaments (10), but since both variants in the patient will only affect the last of the 3 desmoplakin functional C-terminal domains, namely subdomain C, the coherence of desmoplakin and keratin filaments will probably only be weakened but not completely interrupted.

Prediction of the consequences of the mutations c.1067C>A, p.T356K and c.2131_2132delAG found in cases 2 and 3 is challenging. Intriguingly, compared with the patient reported by Whittock et al. (11), who had a comparable mutation constellation, our cases had no skin fragility. The palmoplantar keratoses were minor and remained initially unrecognised, while hair involvement was variable, with the sister being more severely affected than her brother. DNA of the deceased father or of his relatives was not available for analysis, but myocardial infarction at a young age in the father suggests a link to his putative *DSP* mutation, p.T356K. The curly hair and cardiac problems in the mother might be related to the *DSP* mutation c.2131_2132delAG.

The overview of the clinical features and *DSP* mutations of the patients described in the literature

(Table S1¹, Fig. S1c¹[6, 8, 9, 11, 15–37]) illustrates the complexity of this group of disorders and of their genotype-phenotype correlations, which cannot be easily predicted. Beside the largest isoform, DSPI, 2 additional isoforms, DSPII and DSPiA, are produced by alternative mRNA splicing (Fig. S1c¹). Both isoforms, DSPII and DSPiA, encode for a smaller version of DSPI, as they lack parts of the central alpha-helical rod domain with DSPII missing amino acids 1195–1793 and DSPiA missing amino acids 1351–1793 (Fig. S1c¹) (3, 12). DSPI is the major isoform expressed in heart tissue, whereas DSPII is absent from the heart and simple epithelia (13), but plays a more significant role than DSPI in maintaining robust adhesion in keratinocytes (14). DSPiA is evident in both heart and skin, but at considerably lower levels than DSPI and DSPII (12). Mechanistically, it seems that a minimal critical amount of desmoplakin is sufficient to maintain skin integrity. Various intermediately reduced isoform levels and structural defects impact hair development, as well as the mechanical resistance of tissues exposed to high mechanical stress (i.e. palmoplantar skin and myocardium), or other critical functions beyond cell adhesion and intermediate filament stability. Hair anomalies are present in the neonatal period, whereas palmoplantar keratoderma develops gradually. Cardiac dysfunction begins in most cases at a young age and determines the prognosis. Therefore, early diagnosis is crucial and cardiac examinations must be performed on a regular basis.

ACKNOWLEDGEMENTS

We are very grateful to the patients and their families who participated in this study.

REFERENCES

1. Nekrasova O, Green KJ. Desmosome assembly and dynamics. *Trends Cell Biol* 2013; 23: 537–546.
2. Petrof G, Mellerio JE, McGrath JA. Desmosomal genodermatoses. *Br J Dermatol* 2012; 166: 36–45.
3. Nitoiu D, Etheridge SL, Kelsell DP. Insights into desmosome biology from inherited human skin disease and cardiocutaneous syndromes. *Cell Commun Adhes* 2014; 21: 129–140.
4. Patel DM, Green KJ. Desmosomes in the heart: a review of clinical and mechanistic analyses. *Cell Commun Adhes* 2014; 21: 109–128.
5. Ishida-Yamamoto A, Igawa S. Genetic skin diseases related to desmosomes and corneodesmosomes. *J Dermatol Sci* 2014; 74: 99–105.
6. Jonkman MF, Pasmooij AM, Pasmans SG, van den Berg MP, Ter Horst HJ, Timmer A, et al. Loss of desmoplakin tail causes lethal acantholytic epidermolysis bullosa. *Am J Hum Genet* 2005; 77: 653–660.
7. Pigors M, Kiritsi D, Krumpelmann S, Wagner N, He Y, Podda M, et al. Lack of plakoglobin leads to lethal congenital epidermolysis bullosa: a novel clinico-genetic entity. *Hum Mol Genet* 2011; 20: 1811–1819.
8. Norgett EE, Hatsell SJ, Carvajal-Huerta L, Cabezas JC,

- Common J, Purkis PE, et al. Recessive mutation in desmoplakin disrupts desmoplakin-intermediate filament interactions and causes dilated cardiomyopathy, woolly hair and keratoderma. *Hum Mol Genet* 2000; 9: 2761–2766.
9. Hobbs RP, Han SY, van der Zwaag PA, Bolling MC, Jongbloed JD, Jonkman MF, et al. Insights from a desmoplakin mutation identified in lethal acantholytic epidermolysis bullosa. *J Invest Dermatol* 2010; 130: 2680–2683.
 10. Delva E, Tucker DK, Kowalczyk AP. The desmosome. *Cold Spring Harb Perspect Biol* 2009; 1: a002543.
 11. Whittock NV, Wan H, Morley SM, Garzon MC, Kristal L, Hyde P, et al. Compound heterozygosity for non-sense and mis-sense mutations in desmoplakin underlies skin fragility/woolly hair syndrome. *J Invest Dermatol* 2002; 118: 232–238.
 12. Cabral RM, Wan H, Cole CL, Abrams DJ, Kelsell DP, South AP. Identification and characterization of DSPiA, a novel isoform of human desmoplakin. *Cell Tissue Res* 2010; 341: 121–129.
 13. Angst BD, Nilles LA, Green KJ. Desmoplakin II expression is not restricted to stratified epithelia. *J Cell Sci* 1990; 97: 247–257.
 14. Cabral RM, Tattersall D, Patel V, McPhail GD, Hatzimassoura E, Abrams DJ, et al. The DSPiI splice variant is crucial for desmosome-mediated adhesion in HaCaT keratinocytes. *J Cell Sci* 2012; 125: 2853–2861.
 15. Getsios S, Huen AC, Green KJ. Working out the strength and flexibility of desmosomes. *Nat Rev Mol Cell Biol* 2004; 5: 271–281.
 16. Green KJ, Virata ML, Elgart GW, Stanley JR, Parry DA. Comparative structural analysis of desmoplakin, bullous pemphigoid antigen and plectin: members of a new gene family involved in organization of intermediate filaments. *Int J Biol Macromol* 1992; 14: 145–153.
 17. Whittock NV, Ashton GH, Dopping-Hepenstal PJ, Gratian MJ, Keane FM, Eady RA, et al. Striate palmoplantar keratoderma resulting from desmoplakin haploinsufficiency. *J Invest Dermatol* 1999; 113: 940–946.
 18. Sen-Chowdhry S, Syrris P, Prasad SK, Hughes SE, Merrifield R, Ward D, et al. Left-dominant arrhythmogenic cardiomyopathy: an under-recognized clinical entity. *J Am Coll Cardiol* 2008; 52: 2175–2187.
 19. Christensen AH, Benn M, Bundgaard H, Tybjaerg-Hansen A, Haunso S, Svendsen JH. Wide spectrum of desmosomal mutations in Danish patients with arrhythmogenic right ventricular cardiomyopathy. *J Med Genet* 2010; 47: 736–744.
 20. Armstrong DK, McKenna KE, Purkis PE, Green KJ, Eady RA, Leigh IM, et al. Haploinsufficiency of desmoplakin causes a striate subtype of palmoplantar keratoderma. *Hum Mol Genet* 1999; 8: 143–148.
 21. Boule S, Fressart V, Laux D, Mallet A, Simon F, de Groote P, et al. Expanding the phenotype associated with a desmoplakin dominant mutation: Carvajal/Naxos syndrome associated with leukonychia and oligodontia. *Int J Cardiol* 2012; 161: 50–52.
 22. Keller DI, Stepowski D, Balmer C, Simon F, Guenthard J, Bauer F, et al. De novo heterozygous desmoplakin mutations leading to Naxos-Carvajal disease. *Swiss Med Wkly* 2012; 142: w13670.
 23. Chalabreysse L, Senni F, Bruyere P, Aime B, Ollagnier C, Bozio A, et al. A new hypo/oligodontia syndrome: Carvajal/Naxos syndrome secondary to desmoplakin-dominant mutations. *J Dent Res* 2011; 90: 58–64.
 24. Norgett EE, Lucke TW, Bowers B, Munro CS, Leigh IM, Kelsell DP. Early death from cardiomyopathy in a family with autosomal dominant striate palmoplantar keratoderma and woolly hair associated with a novel insertion mutation in desmoplakin. *J Invest Dermatol* 2006; 126: 1651–1654.
 25. Tanaka A, Lai-Cheong JE, Cafe ME, Gontijo B, Salomao PR, Pereira L, et al. Novel truncating mutations in PKP1 and DSP cause similar skin phenotypes in two Brazilian families. *Br J Dermatol* 2009; 160: 692–697.
 26. Bolling MC, Veenstra MJ, Jonkman MF, Diercks GF, Curry CJ, Fisher J, et al. Lethal acantholytic epidermolysis bullosa due to a novel homozygous deletion in DSP: expanding the phenotype and implications for desmoplakin function in skin and heart. *Br J Dermatol* 2010; 162: 1388–1394.
 27. Uzumcu A, Norgett EE, Dindar A, Uyguner O, Nisli K, Kayserili H, et al. Loss of desmoplakin isoform I causes early onset cardiomyopathy and heart failure in a Naxos-like syndrome. *J Med Genet* 2006; 43: e5.
 28. Krishnamurthy S, Adhisivam B, Hamilton RM, Baskin B, Biswal N, Kumar M. Arrhythmogenic dilated cardiomyopathy due to a novel mutation in the desmoplakin gene. *Indian J Pediatr* 2011; 78: 866–869.
 29. Asimaki A, Syrris P, Ward D, Guereta LG, Saffitz JE, McKenna WJ. Unique epidermolytic bullous dermatosis with associated lethal cardiomyopathy related to novel desmoplakin mutations. *J Cutan Pathol* 2009; 36: 553–559.
 30. Vahlquist A, Virtanen M, Hellström-Pigg M, Dragomir A, Ryberg K, Wilson NJ, et al. A Scandinavian case of skin fragility, alopecia and cardiomyopathy caused by DSP mutations. *Clin Exp Dermatol* 2014; 39: 30–34.
 31. Williams T, Machann W, Kuhler L, Hamm H, Muller-Hocker J, Zimmer M, et al. Novel desmoplakin mutation: juvenile biventricular cardiomyopathy with left ventricular non-compaction and acantholytic palmoplantar keratoderma. *Clin Res Cardiol* 2011; 100: 1087–1093.
 32. Yesudian PD, Cabral RM, Ladusans E, Spinty S, Gibbs J, Fryer A, et al. Novel compound heterozygous mutations in the desmoplakin gene cause hair shaft abnormalities and culminate in lethal cardiomyopathy. *Clin Exp Dermatol* 2014; 39: 506–508.
 33. Smith FJ, Wilson NJ, Moss C, Dopping-Hepenstal P, McGrath J. Compound heterozygous mutations in desmoplakin cause skin fragility and woolly hair. *Br J Dermatol* 2012; 166: 894–896.
 34. Al-Owain M, Wakil S, Shareef F, Al-Fatani A, Hamadah E, Haider M, et al. Novel homozygous mutation in DSP causing skin fragility-woolly hair syndrome: report of a large family and review of the desmoplakin-related phenotypes. *Clin Genet* 2011; 80: 50–58.
 35. Alcalai R, Metzger S, Rosenheck S, Meiner V, Chajek-Shaul T. A recessive mutation in desmoplakin causes arrhythmogenic right ventricular dysplasia, skin disorder, and woolly hair. *J Am Coll Cardiol* 2003; 42: 319–327.
 36. Mahoney MG, Sadowski S, Brennan D, Pikander P, Saukko P, Wahl J, et al. Compound heterozygous desmoplakin mutations result in a phenotype with a combination of myocardial, skin, hair, and enamel abnormalities. *J Invest Dermatol* 2010; 130: 968–978.
 37. Rasmussen TB, Hansen J, Nissen PH, Palmfeldt J, Dalager S, Jensen UB, et al. Protein expression studies of desmoplakin mutations in cardiomyopathy patients reveal different molecular disease mechanisms. *Clin Genet* 2013; 84: 20–30.