

## QUIZ SECTION

### Solitary Red-purple Plaque on the Chest of a 7-year-old Boy: A Quiz

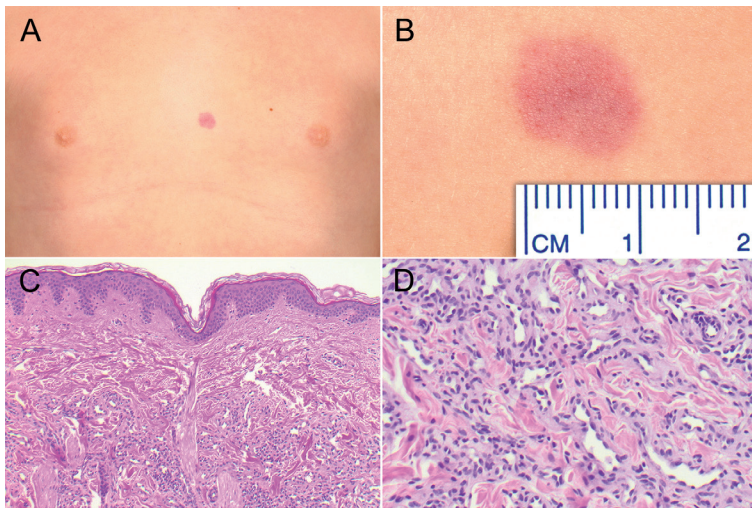
Philipp-Sebastian Koch, Sergij Goerdt and Wiebke K. Peitsch\*

Department of Dermatology, Venereology and Allergology, University Medical Center and Medical Faculty Mannheim, University of Heidelberg and Center of Excellence in Dermatology, Theodor-Kutzer-Ufer 1–3, DE-68135 Mannheim, Germany. \*E-mail: wiebke.ludwig@umm.de

A 7-year-old boy presented with a slowly growing solitary red-purple plaque that had developed during the last 3 months on his chest. The lesion was asymptomatic and the patient was otherwise healthy. There was no history of trauma, insect bite or tick bite. Clinical examination revealed a non-scaly, round, purple-erythematous plaque

sized 10 × 10 mm on the chest (Fig. 1A, B) with multiple red globules seen by dermoscopy. Apart from this lesion, the physical examination was completely unremarkable. A H&E-stained punch biopsy was taken from the plaque (Fig. 1C, D).

*What is your diagnosis? See next page for answer.*



*Fig. 1. Clinical and histopathological findings. (A, B) Purple-erythematous plaque sized 10 × 10 mm on the chest. (C, D) Haematoxylin-eosin stained skin biopsy specimen, showing a vascular neoplasm with slit-like irregularly branched mature vessels in the middle and deep dermis. Magnification: 100-fold (C, survey) or 200-fold (D, detail).*

## ANSWERS TO QUIZ

**Solitary Red-purple Plaque on the Chest of a 7-year-old Boy: A Comment**

Acta Derm Venereol

**Diagnosis: Microvenular haemangioma**

Histopathological examination showed slit-like irregularly branched mature vessels with thin walls and focally slightly dilated lumina in the middle and deep dermis, surrounded by sclerotic stroma with a sparse lymphocytic infiltrate (Fig. 1C). Endothelial cells did not display mitotic figures, pleomorphism or cellular atypia (Fig. 1D). No hobnail endothelium, no cannonball tufted vessels and no hyaline globules were seen. Moreover, there was no erythrocyte extravasation and no haemosiderin deposition. Immunophenotypically, the endothelial cells expressed CD31, CD34, factor VIII and Wilms tumour protein 1 (WT1) but lacked expression of GLUT-1, c-myc and HHV8. Lymphatic endothelial cells in the upper dermis stained positive for D2-40/podoplanin and stabilin-2 whereas the neoplastic vessels were negative for these markers. Antibodies against smooth muscle actin labelled pericytes around the neoplastic vessels.

Taking together clinical and histopathological findings, the patient was diagnosed with microvenular haemangioma (MH), a rare, benign, acquired vascular neoplasm of unknown aetiology. MH was first described by Hunt and colleagues in 1991 (1), although Bantel et al. (2) had reported a similar entity designated “micropapillary angioma” in 1989. MH typically presents as a slowly enlarging, red, purple or reddish-blue plaque or nodule of less than 30 mm diameter on the trunk or limbs of young to middle-aged adults (3, 4). The lesion is mostly solitary and asymptomatic. However, some cases with multiple lesions or with slight tenderness have been described (3, 4).

The diagnosis of MH can be established by routine histology (5, 6) and immunohistochemistry (4, 6).

Clinical and histological differential diagnoses of MH include early-stage Kaposi's sarcoma, kaposiform haemangiioendothelioma, well-differentiated angiosarcoma, lobular capillary haemangioma, acquired tufted angioma and targetoid haemosiderotic haemangioma (5). In contrast to the first 3, MH lacks pleomorphism, cellular atypia and mitoses. Unlike Kaposi's sarcoma, it does not exhibit erythrocyte extravasation, haemosiderin, hyaline globules, spindle-cell fascicles and plasma cells and does not express HHV8. A feature discriminating MH from tufted angioma is lack of the cannonball-like aggregates of vessels typical of the latter. Tufted angioma and kaposiform haemangiioendothelioma are lymphatic anomalies that can be excluded by D2-40 stain. Features differentiating MH from targetoid haemosiderotic haemangioma are absence of hobnail endothelium, dilated vessels, erythrocyte extravasation and haemosiderin.

Less than 50 cases of MH have been published to date, among them only 6 paediatric cases (1, 5, 7–10). Affected

children were between 5 and 13 years of age. Interestingly, all of them were boys, although no male preponderance has been reported in adults. Their lesions were between 10 and 30 mm in size and most frequently located on the trunk (7–10), as in our patient. Most children with MH described so far were healthy, but 2 boys had received a bone marrow transplant, one due to acute myelogenous leukaemia and one due to Wiskott-Aldrich syndrome and lymphoma (8, 9).

Despite the rarity of paediatric MH, knowledge and recognition of this condition are extremely important, as proper diagnosis can prevent unnecessary concern and overtreatment. Our patient and his parents were informed about the benign nature of the lesion and offered treatment with pulsed dye laser. However, the family did not desire any treatment at the moment. A follow-up visit was scheduled after 6 months.

## ACKNOWLEDGEMENTS

The authors thank PD Dr. Cyrill Géraud and Dr. Faisal Tobeigi as well as Prof. Dr. Alexander Marx (University Medical Center Mannheim) for helpful discussion.

## REFERENCES

- Hunt SJ, Santa Cruz DJ, Barr RJ. Microvenular hemangioma. *J Cutan Pathol* 1991; 18: 235–240.
- Bantel E, Grosshans E, Ortonne JP. Zur Kenntnis mikrokapillärer Angiome. Beobachtung bei schwangeren bzw. unter hormoneller Antikonzeption stehenden Frauen. *Z Hautkr* 1989; 64: 1071–1074.
- Linos K, Csaposs J, Carlson JA. Microvenular hemangioma presenting with numerous bilateral macules, patches, and plaques: a case report and review of the literature. *Am J Dermatopathol* 2013; 35: 98–101.
- Ai DF, Li Y, Jindal A, Li P. Multiple microvenular hemangioma: A case report. *Oncol Lett* 2014; 7: 275–277.
- Berk DR, Abramova L, Crone KG, Bayliss SJ. Microvenular haemangioma: report of a paediatric case. *Clin Exp Dermatol* 2009; 34: e304–306.
- Trindade F, Kutzner H, Requena L, Tellechea O, Colmenero I. Microvenular hemangioma – an immunohistochemical study of 9 cases. *Am J Dermatopathol* 2012; 34: 810–812.
- Sanz-Trelles A, Ojeda-Martos A, Jimenez-Fernandez A, Vera-Casaño A. Microvenular haemangioma: a new case in a child. *Histopathology* 1998; 32: 89–90.
- Rikihisa W, Yamamoto O, Kohda F, Hamada M, Yasumoto S, Kiryu H, Asahi M. Microvenular haemangioma in a patient with Wiskott-Aldrich syndrome. *Br J Dermatol* 1999; 141: 752–754.
- Chang SE, Roh KH, Lee MW, Choi JH, Sung KJ, Moon KC, et al. Microvenular hemangioma in a boy with acute myelogenous leukemia. *Pediatr Dermatol* 2003; 20: 266–267.
- Nakamura Y, Takahashi T, Xu X, Otsuka F. Multiple microvenular hemangiomas in a healthy child. *Int J Dermatol* 2009; 48: 95–97.