

SHORT COMMUNICATION

TRPS1 Haploinsufficiency Results in Increased STAT3 and SOX9 mRNA Expression in Hair Follicles in Trichorhinophalangeal SyndromeAkitaka Shibata[#], Kana Tanahashi[#], Kazumitsu Sugiura and Masashi Akiyama*

Department of Dermatology, Nagoya University Graduate School of Medicine, 65 Tsurumai-cho, Showa-ku, Nagoya, Japan, 466-8550. E-mail: makiyama@med.nagoya-u.ac.jp

[#]These authors contributed equally to this work and should be considered as first authors.

Accepted Aug 19, 2014; Epub ahead of print Aug 19, 2014

Trichorhinophalangeal syndrome types I and III (TRPS1, OMIM 190350; TRPS3, OMIM 190351) are rare hereditary diseases with autosomal dominant inheritance (1, 2). The first case was reported in 1966 (3). In 2000 the *TRPS1* gene was identified as one of its causative genes and mapped to chromosomal region 8q24.1 (1).

These syndromes have characteristic sparse and slow-growing hair, craniofacial abnormalities, such as bulbous pear-shaped nose, and skeletal abnormalities (3–5). We report here the effects of TRPS1 protein deficiency in a case of TRPS1.

CASE REPORT

A 26-year-old Japanese woman was referred to us for sparse scalp hair from birth. Physical examination revealed characteristic symptoms of TRPS1 (Fig. 1a–c). Her serum creatinine level was 0.71 mg/dl (normal range <0.70 mg/dl). Radiologically, cone-shaped epiphyses were found at the phalanges (Fig. S1¹). She had never had growth hormone treatment. She was 158 cm tall, roughly the mean height of Japanese females, and had no growth

retardation. None of her family members showed hypotrichosis or skeletal abnormalities. The patient was suspected of having TRPS, and a *TRPS1* mutation search was performed. The ethics committee of Nagoya University approved the studies described below, which were conducted according to the principles of the Declaration of Helsinki. The participants gave written informed consent. Direct sequencing of the entire coding regions and exon-intron boundaries of *TRPS1* revealed the patient to be heterozygous for the previously unreported nonsense mutation c.2191G>T in *TRPS1*, resulting in an immediate stop codon (p.Glu732X) (Fig. 1d). This mutation was not found in 100 healthy Japanese control individuals. No other mutation was found in the *TRPS1* gene of the patient. TRPS III has missense mutations specifically in the GATA DNA-binding zinc finger of the TRPS1 protein, located in the region, the amino acid positions 896–920. TRPS III shows similar clinical features to TRPS I, except that TRPS III presents more severe brachydactyly and growth retardation (2). From the clinical features and causative gene mutation, we diagnosed the patient as TRPS1. In our patient, we analysed mRNA levels of TRPS1 and TRPS1-related molecules expressed

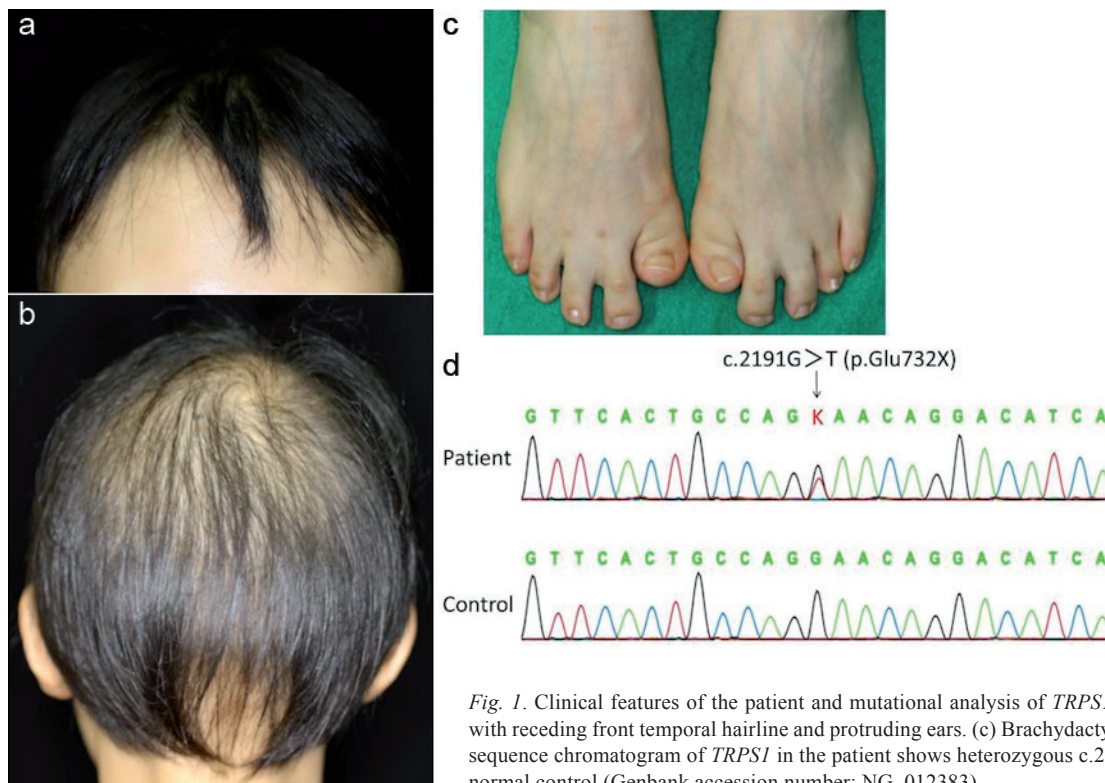
¹<https://doi.org/10.2340/00015555-1948>

Fig. 1. Clinical features of the patient and mutational analysis of *TRPS1*. (a, b) Sparse scalp hair with receding front temporal hairline and protruding ears. (c) Brachydactyly of the big toes. (d) The sequence chromatogram of *TRPS1* in the patient shows heterozygous c.2191G>T compared with a normal control (Genbank accession number: NG_012383).

by cutaneous epithelial cells using total RNA samples extracted from plucked hairs of the patient and 7 normal control individuals. *TRPS1* was down-regulated and *STAT3*, *SOX9* and *CTNNB1* were up-regulated in plucked hairs from the patient compared with those in normal controls (Fig. S2 a, b¹). *FGF5*, *TGFB1*, *STAT6* and *STAT1* were not up-regulated (Fig. S2c¹).

DISCUSSION

The *TRPS1* gene encodes a zinc-finger transcription factor TRPS1 protein composed of 1,281 amino acids with 9 putative zinc-finger motifs (1). The *IKAROS*-like sequence consists of the last 2 zinc-finger motifs (motifs 8 and 9) and mediates the transcription repressive function. The 7th zinc-finger motif binds to the GATA consensus *cis* element and also mediates repressive activity (6). For example, Trps1 is assumed to be a regulator of chondrocyte proliferation and survival via the control of Stat3 expression (7). Indeed, up-regulated expression of STAT3 was observed in the outer root sheath of hair follicles in a TRPS1 patient with a TRPS1 mutation by immunohistochemistry (8). The Sox9 gene is known to regulate the proliferation and survival of hair follicle stem cells. Trps1 also regulates epithelial proliferation in the developing hair follicle via its control of Sox9 expression by the binding GATA sequence (9). β -catenin drives a hair shaft formation signal and is a key component of canonical Wnt signalling. Recent evidence suggests that the Wnt/ β -catenin pathway cross-talks with STAT3 signalling to regulate the survival of retinal pigment epithelial cells (10). In mice model, Trps1 is also reported to interact with 2 histone deacetylases, Hdac1 and Hdac4, thereby increasing their activity. Loss of Trps1 results in histone H3 lysine 9 (H3K9) hyperacetylation, which is maintained during mitosis (11).

We confirmed that mRNA decay occurred in *TRPS1* in plucked hairs. The GATA-type zinc-finger is resident at position 896–920. Thus, it is thought that transcription repressive function would be lost and haploinsufficiency would occur. We assumed that TRPS1 would also directly repress STAT3 and SOX9 activity by binding the GATA sequence in human hair follicles as in the mice model. The mutant TRPS1 in the present case was unable to repress *STAT3* and *SOX9* mRNA expression. The present results show that the elevation of CTNNB1 in mRNA level indicated that crosstalk of STAT3 and Wnt/ β -catenin would also occur in hair follicles. Thus, TRPS1 would also repress Wnt/ β -catenin signalling by repressing STAT3. In light of this, we think that the present TRPS1 loss-of-function mutation leads to the up-regulation of Sox9 and STAT3 and that the increased STAT3 signal results in the activation of hair shaft formation signalling by Wnt/ β -catenin and the depletion of progenitor cells for the hair follicle epithelium. This depletion might be associated with the hypotrichosis phenotype in TRPS1. We speculate that FGF-5 and TGF- β 1, which are degradation period shift signals in hair cycle, STAT6 and STAT1 were not directly influ-

enced by TRPS1. Furthermore, loss of TRPS1 function may result in H3K9 hyperacetylation, which is maintained during mitosis (11) and supposedly lead to hypotrichosis.

In conclusion, we clearly demonstrate for the first time that haploinsufficiency of TRPS1 leads to the up-regulation of STAT3 and SOX9, and that activated STAT3 and β -catenin signalling might be associated with the hypotrichosis phenotype in TRPS1 (Fig. S2d¹). Our data give us further insight into the function of TRPS1 in hair signalling and into the pathomechanisms of TRPS.

ACKNOWLEDGEMENT

This study was supported in part by Grant-in-Aid for Scientific Research (A) 23249058 to M. Akiyama from the Ministry of Education, Culture, Sports, Science and Technology of Japan and by a grant from the Ministry of Health, Labor and Welfare of Japan (Health and Labor Sciences Research Grants; Research on Intractable Diseases; H22-Nanchi-Ippan-177) to M. Akiyama.

REFERENCES

1. Momeni P, Glockner G, Schmidt O, von Holtum D, Albrecht B, Gillessen-Kaesbach G, et al. Mutations in a new gene, encoding a zinc-finger protein, cause tricho-rhino-phalangeal syndrome type I. *Nat Genet* 2000; 24: 71–74.
2. Ludecke HJ, Schaper J, Meinecke P, Momeni P, Gross S, von Holtum D, et al. Genotypic and phenotypic spectrum in tricho-rhino-phalangeal syndrome types I and III. *Am J Hum Genet* 2001; 68: 81–91.
3. Giedion A, Burdea M, Fruchter Z, Meloni T, Trosc V. Autosomal-dominant transmission of the tricho-rhino-phalangeal syndrome. Report of 4 unrelated families, review of 60 cases. *Helv Paediatr Acta* 1973; 28: 249–259.
4. Felman AH, Frias JL. The trichorhinophalangeal syndrome: study of 16 patients in one family. *AJR Am J Roentgenol* 1977; 129: 631–638.
5. Ning CC, Hsu MM, Lee JY, Chao SC. Clinical characteristics of tricho-rhino-phalangeal syndrome type I in Taiwanese. *J Formos Med Assoc* 2001; 100: 635–638.
6. Kaiser FJ, Brega P, Raff ML, Byers PH, Gallati S, Kay TT, et al. Novel missense mutations in the TRPS1 transcription factor define the nuclear localization signal. *Eur J Hum Genet* 2004; 12: 121–126.
7. Suemoto H, Muragaki Y, Nishioka K, Sato M, Ooshima A, Itoh S, et al. Trps1 regulates proliferation and apoptosis of chondrocytes through Stat3 signaling. *Dev Biol* 2007; 312: 572–581.
8. Ito T, Shimomura Y, Farooq M, Suzuki N, Sakabe J, Tokura Y. Trichorhinophalangeal syndrome with low expression of TRPS1 on epidermal and hair follicle epithelial cells. *J Dermatol* 2013; 40: 396–398.
9. Fantauzzo KA, Kurban M, Levy B, Christiano AM. Trps1 and its target gene Sox9 regulate epithelial proliferation in the developing hair follicle and are associated with hypertrichosis. *PLoS Genet* 2012; 8: e1003002.
10. Frago MA, Patel AK, Nakamura RE, Yi H, Surapaneni K, Hackam AS. The Wnt/ β -catenin pathway cross-talks with STAT3 signaling to regulate survival of retinal pigment epithelium cells. *PLoS One* 2012; 7: e46892.
11. Wuelling M, Pasdziernik M, Moll CN, Thiesen AM, Schneider S, Johannes C, et al. The multi zinc-finger protein Trps1 acts as a regulator of histone deacetylation during mitosis. *Cell Cycle* 2013; 12: 2219–2232.