

SHORT COMMUNICATION

***Mycobacterium ulcerans* Disease (Buruli Ulcer) in Mali: A New Potential African Endemic Country**Didier Bessis¹, Marie Kempf^{2,3} and Laurent Marsollier^{3,4}¹Département de Dermatologie, Université Montpellier 1, Hôpital Saint-Éloi, CHU Montpellier, 80 avenue Augustin Fliche, FR-34295 Montpellier,²Laboratoire de Bactériologie, Institut de Biologie en Santé, ³L'UNAM Université, Université d'Angers, IRIS, CHU, and ⁴ATOMyC.A, Inserm Avenir team, CRCNA, Inserm U892, 6299 CNRS, Université et CHU Angers, Angers, France. E-mail: d-bessis@chu-montpellier.fr

Accepted Aug 11, 2014; Epub ahead of print Aug 13, 2014

Buruli ulcer (BU) is a necrotizing skin and soft tissue infection caused by *Mycobacterium ulcerans*. This tropical disease has been relatively neglected up to now, but it is the third most common chronic mycobacterial infection in humans, with cases reported from more than 30 countries. The highest incidence rate is observed in sub-Saharan Africa, but, to date, Mali has not been cited as an endemic country (1, 2). We report here a case of BU in a young girl living in Bamako, Mali. To our knowledge, this is the second case reported in this country (3).

CASE REPORT

A 9-year-old girl was referred for assessment of an extensive oedematous ulcerated lesion on the left lower leg, ankle and dorsum of the foot (Fig. 1A). The

patient came from Bamako, Mali, where she had been living in the streets before recently being placed in an orphanage. The lesions had appeared 3 years earlier, but no other information was available. Physical examination revealed a painless, large (16 cm along its longer axis) and circumferential ulcer of the lower left leg, with necrotic and granulation tissue and undetermined hyperpigmented edges. Peripheral firm skin oedema was also noted, mostly on the ankle and the dorsum of the left foot. Standard laboratory findings were within normal limits, except for a C-reactive protein level of 14.6 mg/l (normal <5 mg/l). Serological tests were negative for HIV 1 and 2 and hepatitis B and C. Bacteriological examination and culture by wound swabs and skin biopsies failed to identify acid-fast bacilli. Histopathological findings for a specimen taken from the edge of the ulceration showed a non-specific epithelial hyperplasia with dermal inflammatory infiltrate. Periodic acid-Schiff staining and Ziehl-Neelsen staining were both negative. Tissue specimens were placed onto Löwenstein-Jensen slants (incubated at 30°C). No growth was detected 12 weeks later. Magnetic resonance imaging of the left leg showed a contiguous osteomyelitis with thinning of the cortex and periosteal reactive new bone under the ulcer (Fig. 2).

Taq-Man real-time quantitative PCR that used primers for 2 *M. ulcerans*-specific genes (insertion sequence 2404 and ketoreductase B gene) (4) was performed on the wound swab after hydration. The results showed the presence of *M. ulcerans* DNA. A normalized standard curve was constructed, which indicated a bacterial load of $\approx 5 \times 10^2$ organisms/ml.

According to the World Health Organization (WHO) recommendations, oral antibiotic regimen, including rifampicin 300 mg/day, clarithromycin 450 mg/day, was started and the ulcer was dressed regularly. Due to the large size of ulceration and the bone involvement, ciprofloxacin 900 mg/day was added and treatment was continued through 6 months. At this time, re-epithelialization of the granulomatous tissues, reduction in size of the ulceration, and decreased oedema were observed (Fig. 1B). The patient returned to Mali with the recommendation to continue treatment for an additional 6 months (total 1 year) before returning to France for a decision on the need for surgical skin and bone management.

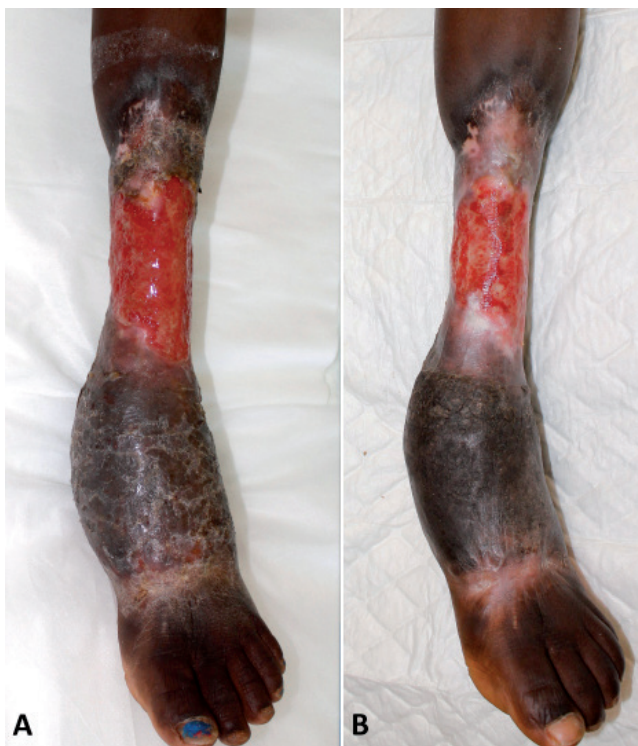

Fig. 1. Buruli ulcer of the lower left leg, ankle and dorsum of the foot. (A) Extensive oedematous ulcerated lesion on initial admission. (B) After 6 months of an oral antibiotic regimen and regular dressings, re-epithelialization of the granulomatous tissues, reduction in the size of ulceration, and decrease in the oedema were observed.

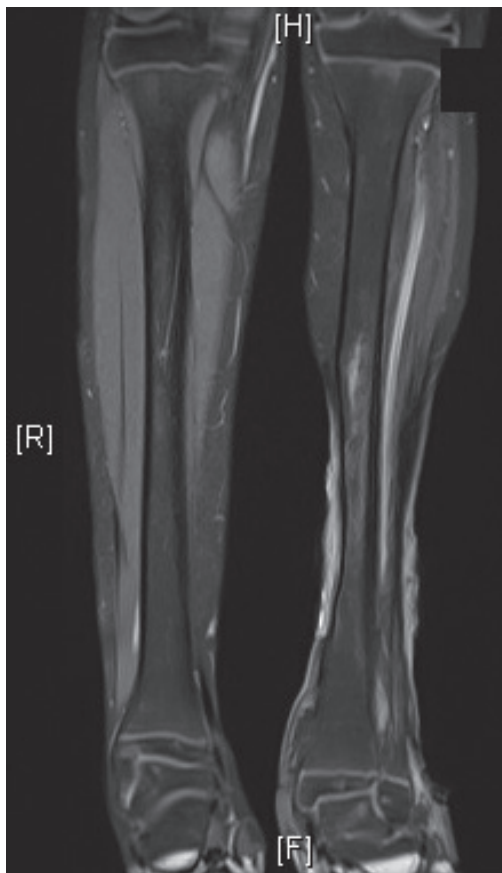


Fig. 2. Osteomyelitis of the lower left leg, under the ulcer, with thinning of the cortex and periosteal reactive bone.

DISCUSSION

This young girl was transferred from an orphanage in Bamako, Mali, to the University Hospital of Montpellier, France, under collaborative contracts with humanitarian aid organizations. Upon her admission, the diagnosis of BU was quickly raised because of the typical clinical signs, although Mali is not known to be an endemic country for *M. ulcerans* (1, 2). Indeed, despite other suspected cases in Mali, no confirmation has been available and, according to the WHO, Mali is not considered an endemic zone for BU based on the results of the *M. ulcerans* observatory created in 2002. Mali is in West Africa and is bordered by 7 countries, 2 of which are BU endemic countries: Guinea, in the southwest, and Ivory Coast, in the south (5, 6). In Ivory Coast, 1,386 cases of BU were reported in 2012, whereas in Guinea, 82 cases were reported in the same year (1).

The exact mode of transmission of *M. ulcerans* remains unclear, although the role of aquatic insects has been supported by observation and experimental studies (7, 8). The Niger River, crossing Bamako, can host such insects. In our young patient, the environmental reservoir and mode of transmission of BU are unknown.

Moreover, it was difficult to obtain information on the possible exposure of unprotected skin to stagnant or slow-flowing water, which is known to be linked with BU, because of the girl's young age and homeless status prior to orphanage placement.

The clinical presentation of this case, with a lesion that had appeared 3 years earlier, first as a nodule, then as a painless large ulcer that slowly progressed without systemic symptoms, is consistent with BU. The microbiological diagnosis of BU was based on PCR detection of 2 *M. ulcerans*-specific genes. This procedure is adequate, according to Johnson et al. (9). The relatively low number of detected organisms may explain the negative acid-fast bacilli smear and negative culture results (10).

In conclusion, detection of this case of BU suggests that Mali is a potential endemic country for BU. Further cases should be actively sought in this country, and adjoining districts should be visited to evaluate the geographical extent of the disease.

The authors declare no conflicts of interest.

REFERENCES

1. Global Buruli Ulcer Initiative (GBUI), World Health Organization. Buruli ulcer endemic countries [Internet]. 2013. Available from: <http://www.who.int/buruli/country/en/>.
2. Johnson PD, Stinear T, Small PL, Pluschke G, Merritt RW, Portaels F, et al. Buruli ulcer (*M. ulcerans* infection): new insights, new hope for disease control. *PLoS Med* 2005; 2: e108.
3. Ezzedine K, Pistone T, Guir V, Malvy D. Painful Buruli ulcer in a Malian visitor to France. *Acta Derm Venereol* 2010; 90: 424.
4. Ezzedine K, Pistone T, Cottin J, Marsollier L, Guir V, Malvy D. Buruli ulcer in long-term traveler to Senegal. *Emerg Infect Dis* 2009; 15: 118–119.
5. Brou T, Broutin H, Elguero E, Asse H, Guegan JF. Landscape diversity related to Buruli ulcer disease in Cote d'Ivoire. *PLoS Negl Trop Dis* 2008; 2: e271.
6. Amofah G, Bonsu F, Tetteh C, Okrah J, Asamoah K, Asiedu K, et al. Buruli ulcer in Ghana: results of a national case search. *Emerg Infect Dis* 2002; 8: 167–170.
7. Marion E, Eyangoh S, Yeramian E, Doannio J, Landier J, Aubry J, et al. Seasonal and regional dynamics of *M. ulcerans* transmission in environmental context: deciphering the role of water bugs as hosts and vectors. *PLoS Negl Trop Dis* 2010; 4: e731.
8. Marsollier L, Robert R, Aubry J, Saint Andre JP, Kouakou H, Legras P, et al. Aquatic insects as a vector for *Mycobacterium ulcerans*. *Appl Environ Microbiol* 2002; 68: 4623–4628.
9. Johnson PD, Hayman JA, Quek TY, Fyfe JA, Jenkin GA, Buntine JA, et al. Consensus recommendations for the diagnosis, treatment and control of *Mycobacterium ulcerans* infection (Bairnsdale or Buruli ulcer) in Victoria, Australia. *Med J Aust* 2007; 186: 64–68.
10. Marsollier L, Prevot G, Honore N, Legras P, Manceau AL, Payan C, et al. Susceptibility of *Mycobacterium ulcerans* to a combination of amikacin/rifampicin. *Int J Antimicrob Agents* 2003; 22: 562–566.