

## SHORT COMMUNICATION

## Rapidly Developed Neurosyphilis in a Psoriasis Patient Under Treatment with Infliximab: A Case Report

Kimi Kase<sup>1</sup>, Yasue Ishii-Osai<sup>1</sup>, Yasuyuki Sumikawa<sup>1</sup>, Akihiro Yoneta<sup>1</sup>, Daisaku Himeno<sup>2</sup>, Yohei Kakutani<sup>2</sup> and Toshiharu Yamashita<sup>1</sup>Departments of <sup>1</sup>Dermatology and <sup>2</sup>Neuropsychiatry, Sapporo Medical University School of Medicine, South 1, West 16, Chuo-ku, Sapporo 060-8543, Japan.E-mail: [kkase@sapmed.ac.jp](mailto:kkase@sapmed.ac.jp)

Accepted Aug 11, 2014; Epub ahead of print Aug 11, 2014

Tumour necrosis factor (TNF)- $\alpha$  inhibitors may be associated with an increased risk of infections, including serious and rare opportunistic infections (1), but no specific precautions have been recommended against syphilis in the guidelines for treatment of psoriasis by biologics (2, 3). A case of neurosyphilis that developed in a psoriasis patient treated with a TNF- $\alpha$  inhibitor is presented.

## CASE REPORT

A 40-year-old Japanese man, unmarried, with a 30-year history of psoriasis vulgaris began treatment with infliximab, a TNF- $\alpha$  inhibitor. The patient's PASI score declined from 9.4 to 0.3 by 54 weeks post-treatment. However, at around the same time, the patient began experiencing emotional instability and excitability. Upon entering the neuropsychiatry ward of our hospital, the serological assay for *T. pallidum* was 14.0 R.U. according to a rapid plasma reagin (RPR) card test and 23,250 R.U. on a *T. pallidum* particle agglutination assay test (TPPA). An HIV-I/II antibody test was negative. To evaluate neurological involvement of syphilis, a lumbar puncture was performed, which indicated an increased cell count of 83/mm<sup>3</sup> (normal < 5/mm<sup>3</sup>) as well as an increased protein level of 79 mg/dl (normal 15–45 mg/dl), positive TPPA (4,962 R.U.) and RPR (5.8 R.U.)

in the cerebrospinal fluid. A neurological examination revealed no dysfunction. Cranial magnetic resonance imaging showed a manifestation of limbic encephalitis (Fig. 1), while 99mTc-ECD brain single photon emission computed tomography was normal. Neuropsychological subtests by WAIS (Wechsler Adult Intelligence Scale)-III and WMS-R (Wechsler Memory Scale-Revised) revealed decreases in the patient's verbal and performance IQ, and verbal and non-verbal memory abilities, respectively. The Benton visual retention test, which measures visual perception and visual memory, showed the presence of an acquired intellectual disability.

After the diagnostic work-up, the patient confessed that he had frequent sexual relationships with commercial sex workers. The patient received antibiotic treatment with penicillin (24 million IE IV/day) for 9 days. Due to a drug eruption caused by the penicillin, not Jarisch-Herxheimer reaction, he was then treated with ceftriaxone for 28 days until the RPR tests in both the blood serum and cerebrospinal fluid were negative. Due to the functional disability of his brain, he was unable to return to his work as a machinist and remained in a slightly depressive state. After his treatment with infliximab ceased, his psoriasis eruptions became slightly worse with the PASI score increasing to 3.2. After the patient began receiving cyclosporine at 200 mg/day, the PASI score decreased to 0.

## DISCUSSION

Neurosyphilis literally means syphilitic infection of the central nervous system, but is often incorrectly referred to as “tertiary syphilis.” Neurosyphilis can occur at any time in the course of syphilis, even at the earliest primary stage. Early forms of neurosyphilis primarily affect the meninges, cerebrospinal fluid and cerebral or spinal cord vasculature. Late forms of neurosyphilis primarily affect the brain and spinal cord parenchyma (4). In recent years the time interval between early and late neurosyphilis can also be very short (5). Several reports of “neurosyphilis mimicking herpes simplex encephalitis” have appeared in the past 10 years (6–10). These observations share several features: the patients were relatively young, and most had a brief history of cognitive impairment.

A few reports have described secondary syphilis occurring after using TNF- $\alpha$  inhibitors (11–13). In our case, the patient developed irreversible brain damage due to neurosyphilis.

It is not clear whether latently infected *T. pallidum* propagated rapidly in our patient due to the TNF- $\alpha$  inhibitor or if it infected the patient during the treatment with biologics. Because of the high titre of TPPA (23,250

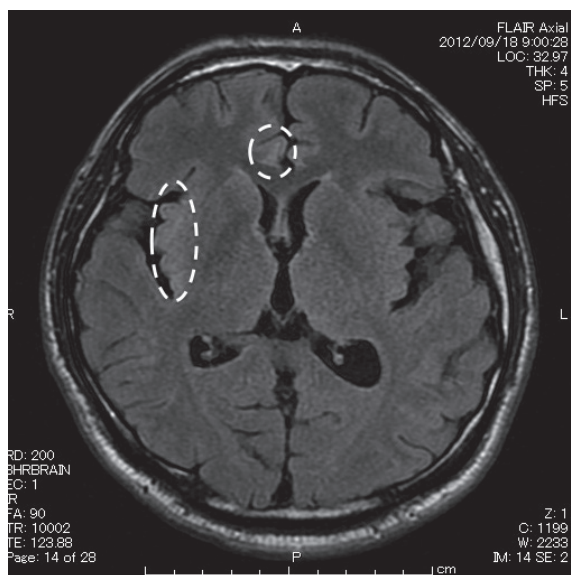


Fig. 1. Brain image of MRI: There were isolated lesions showing high signal intensity on FLAIR 2 (Fluid Attenuated Inversion Recovery) image in right frontal lobe and right insular cortex (circle); this is a manifestation of limbic encephalitis.

R.U.), it is conceivable that *T. pallidum* infected and rapidly propagated to neurosyphilis due to the biologics.

Our patient had no history or memories of genital eruptions or palmoplantar eruptions, or other types of macular syphilis. However, the secondary syphilis may have been overlooked due to it occurring at the same time as a psoriatic eruption. Also, secondary syphilis may mimic a paradoxical reaction caused by infliximab (11), however, the patient showed no papulosquamous eruptions during the treatment period with infliximab. It might be under review whether serological testing for syphilis is necessary examination before treatment of psoriasis with a TNF- $\alpha$  inhibitor.

*The authors declare no conflict of interest.*

## REFERENCES

1. Saraceno R, Chimenti S. How to manage infections in the era of biologics? *Dermatol Ther* 2008; 21: 180–186.
2. Smith CH, Anstey AV, Barker JN, Burden AD, Chalmers RJ, Chandler DA, et al. British Association of Dermatologists' guidelines for biologic interventions for psoriasis 2009. *Br J Dermatol* 2009; 161: 987–1019.
3. Coates LC, Tillett W, Chandler D, Helliwell PS, Korendowych E, Kyle S, et al. The 2012 BSR and BHPR guideline for the treatment of psoriatic arthritis with biologics. *Rheumatol (Oxford)* 2013; 52: 1754–1757.
4. Marra CM. Update on neurosyphilis. *Curr Infect Dis Rep* 2009; 11: 127–134.
5. Timmermans M, Carr J. Neurosyphilis in the modern era. *J Neurol Neurosurg Psychiatry* 2004; 75: 1727–1730.
6. Gürses C, Bilgiç B, Topçular B, Tuncer OG, Akman-Demir G, Hanağasi H, et al. Clinical and magnetic resonance imaging findings of HIV-negative patients with neurosyphilis. *J Neurol* 2007; 254: 368–374.
7. Noone ML, Sinha S, Taly AB, Chandrika S. Periodic lateralized epileptiform discharges in neurosyphilis. *Epilepsia* 2007; 48: 390–393.
8. Chang YP, Lin RT, Liu CK, Liu CK, Chao HL, Chao AC. Neurosyphilis presenting with status epilepticus. *Neurologist* 2006; 12: 314–317.
9. Bash SM, Hathout GN, Cohen S. Mesiotemporal T2-weighted hyperintensity: neurosyphilis mimicking herpes encephalitis. *Am J Neuroradiol* 2001; 22: 314–316.
10. Szilak I, Marty F, Helft J, Soeiro R. Neurosyphilis presenting as herpes simplex encephalitis. *Clin Infect Dis* 2001; 32: 1108–1109.
11. Asahina A, Ishii N, Tohma S. Secondary syphilis following tumor necrosis factor- $\alpha$  inhibitor treatment for rheumatoid arthritis. *J Dermatol* 2012; 39: 199–201.
12. Bettenworth D, Floer M, Krummenerl T, Wehrmann W, Schärer L, Heidemann J. Advanced-stage syphilis unmasking after immunomodulator therapy in a patient with ulcerative colitis. *Am J Gastroenterol* 2012; 107: 144–145.
13. Bories-Haffner C, Buche S, Paccou J. Secondary syphilis occurring under anti-TNF $\alpha$  therapy. *Joint Bone Spine* 2010; 77: 364–365.