

CLINICAL REPORT

Alitretinoin (9-*cis* Retinoic Acid) is Effective Against Pityriasis Rubra Pilaris: A Retrospective Clinical Study

Philipp M. AMANN^{1,2}, Marijan SUSIC¹, Franziska GLÜDER¹, Hans BERGER¹, Wolfgang KRAPF¹ and Harald LÖFFLER^{1,3}

¹Department of Dermatology, SLK Hospital Heilbronn, Heilbronn, ²Department of Dermatology and Allergology, RWTH Aachen University Hospital, Aachen, and ³Department of Dermatology and Allergology, Philipps-University, Marburg, Germany

Pityriasis rubra pilaris (PRP) is an uncommon cutaneous disease with disorder of keratinisation. Up to now, systemic retinoids like acitretin or isotretinoin seem to be the most effective therapeutic agents. However, no large trials on this rare disease have been published and no standardised treatment has been established so far. Recently, single case reports demonstrate beneficial effects of alitretinoin (9-*cis* retinoic acid) in patients with PRP. We performed a retrospective observational analysis of type I adult-onset patients with PRP ($n=5$) treated with systemic alitretinoin in our department. Alitretinoin was highly effective in the treatment of PRP in 4 of 5 cases. PASI score was reduced significantly in the alitretinoin responders. We assume that alitretinoin could serve as an additional effective systemic treatment option for type I adult-onset PRP. Key words: retinoids, vitamin A; retinoic acid; alitretinoin; pityriasis rubra pilaris; psoriasis.

Accepted Jul 1, 2014; Epub ahead of print Jul 4, 2014

Acta Derm Venereol 2015; 95: 329–331.

Philipp M. Amann, Department of Dermatology, SLK Hospital Heilbronn, DE-74078 Heilbronn, Germany. E-mail: philipp.amann@slk-kliniken.de

Vitamin A derivatives (retinoids) are considered to have a large range of biological effects (1). Due to their influence on keratinisation, epithelial differentiation and keratinocyte proliferation retinoids have found a wide application in the field of dermatopharmacology (2). Alitretinoin (9-*cis* retinoic acid) represents an endogenous retinoid serving as a pan-agonist for both nuclear retinoid receptors: retinoic acid receptor (RAR) and retinoid-X-receptor (RXR). The systemic use of alitretinoin is licensed in Europe for treatment of severe chronic hand eczema (3). In addition, in several recently published case reports alitretinoin was successfully used in the treatment of different keratinisation disorders like Darier's disease (4) and palmoplantar (pustulosis) psoriasis (5). Variable effects of alitretinoin were observed in congenital ichthyosis (6).

Pityriasis rubra pilaris (PRP) is an uncommon cutaneous disorder of unknown cause characterised by follicular and palmoplantar hyperkeratosis, desquamation and erythema. Accordingly, neither randomised control-

led trials on PRP have been published in the literature, nor standardised treatment has been established so far. Systemic retinoids like acitretin or isotretinoin seem to be the most effective therapeutic agents but satisfying clinical response does not always occur (7). Recently, 3 single case reports were published considering alitretinoin as a very successful and well-tolerated treatment option for patients with PRP (8–10).

In this work we performed a retrospective clinical analysis in a collective of 5 patients with PRP who were treated with alitretinoin in our department.

METHODS

Patients and treatment regime

Clinical reports were searched for patients with PRP diagnosed by clinical or histopathological features and alitretinoin treatment. Five individuals (2 women and 3 men, age range 55–80 years) with adult type I PRP were identified by clinical and histopathological criteria. All patients were treated orally with alitretinoin 30 mg/day after exclusion of contraindications. Laboratory blood analysis (haematological parameters, renal retention parameters like creatinine, liver enzymes, cholesterol, triglycerides, thyroid-stimulating hormone, creatine kinase) were performed under alitretinoin treatment. Details of the medical history, clinical examination and histopathology were obtained in each case. Previous treatments as well as systemic co-medication and supportive local therapy are listed in Table SI¹. This study was conducted according to Declaration of Helsinki Principles and approved by the ethical committee of the Medical Faculty of the University Heidelberg, Germany.

Clinical evaluation

Clinical evaluation was documented by photographs. In the absence of a severity assessment score for PRP and since PRP shows similar clinical features to psoriasis, PASI (Psoriasis Area and Severity Index) score was evaluated prospectively in the clinical setting before and under alitretinoin treatment. Statistical analysis was performed by paired *t*-test with significant differences determined as $p < 0.05$.

RESULTS

Five individuals were diagnosed with 'classical' type I adult-onset pityriasis rubra pilaris. Previous systemic or local treatments (see Table SI¹) were ineffective.

¹<https://doi.org/10.2340/00015555-1928>

After exclusion of contraindications all 5 patients were treated with alitretinoin 30 mg p.o./day. Patients 1–4 showed convincing clinical response already after 4–8 weeks (Fig. 1, Fig. S1¹, Fig. S2¹). Accordingly, PASI score assessed in these alitretinoin responders was on average reduced significantly about 71% ($p=0.006$) after 4–8 weeks (Fig. 2a).

In one case (patient 1) alitretinoin treatment was terminated after 22 weeks (Fig. 1c) and the patient remained free of symptoms. Alitretinoin was well tolerated in all patients except patient 3 showing an increase of creatine kinase and transaminases up to 3-fold compared to the normal level after 22 weeks of treatment.

In patient 5 the existing PRP lesions showed only slight reduction after 13-week treatment with acitretin 30 mg/day. When medication was switched to alitretinoin 30 mg/day a rapid progression and occurrence of new PRP skin lesions were observed within 3 weeks (Fig. 2b, c). Again, therapy was changed back to acitretin but in a higher dosage (75 mg/day) leading to a clear but slow improvement of skin symptoms over 15 weeks (Fig. 2d).

DISCUSSION

Pityriasis rubra pilaris is a chronic, progressive and intractable disease diagnosed by explicit clinical features supplemented by microscopic pathology. Its therapy is very challenging and clinical response is often sobering. In this retrospective report we demonstrate 5 cases

of PRP treated with systemic alitretinoin. We could demonstrate that alitretinoin 30 mg/day was highly effective in 4 of 5 cases when alitretinoin was applied to treat PRP for the first time. This observation is consistent with previous single PRP case reports (8–10).

The detailed mode of action of alitretinoin in PRP is unknown. Due to the histological and clinical overlap of PRP with psoriasis vulgaris, parallels have been drawn regarding the therapeutic options. Alitretinoin has been found to produce an anti-inflammatory response (11). *In vitro*, alitretinoin showed higher affinity to RAR than to RXR and inhibited production of nitric oxide and proinflammatory cytokines such as tumour necrosis factor (TNF)- α , interleukin (IL)-1 β and IL-12p40 (11, 12). Accordingly, efficacy of TNF- α inhibitors and the blocking IL-12/IL-23 anti-p40 monoclonal antibody ustekinumab was also shown in PRP case reports (13–15). Hence, beneficial therapeutic effects of alitretinoin in PRP might possibly be due to suppression of TNF- α and IL-12/IL-23 cytokines.

Interestingly, alitretinoin treatment failed in patient 5 but a shift to high-dose acitretin lead to partial remission of PRP lesions. Therefore, we suggest that patients with PRP could benefit from higher retinoid dosage or a shift to another retinoid if the previously chosen retinoid therapy remains unsuccessful.

In conclusion, we showed in a retrospective setting within a small collective that alitretinoin is a promising therapy for treatment of type I adult-onset PRP.

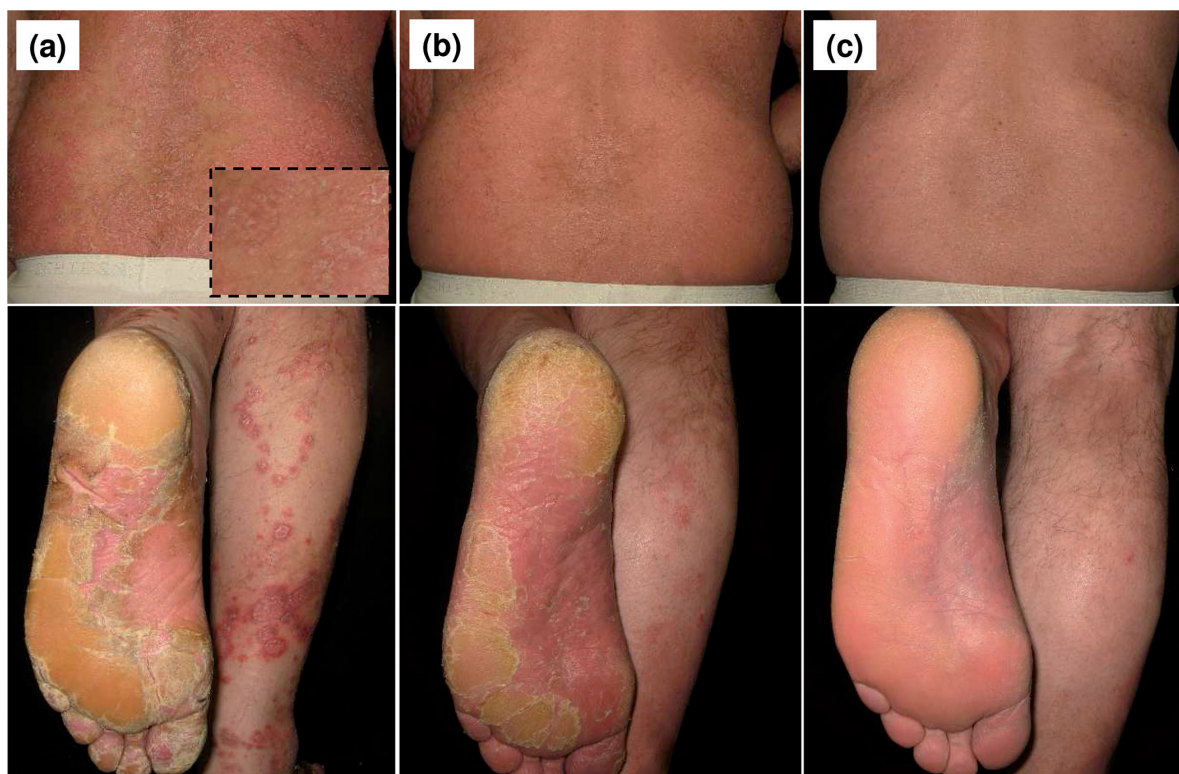


Fig. 1. Clinical appearance of patient 1 with initial squamous erythroderma and islands of non-involved skin ('nappes claires') on the trunk and palmoplantar hyperkeratosis with painful fissures (a) before, (b) after 4 weeks and (c) 22 weeks of systemic alitretinoin therapy (30 mg/day).

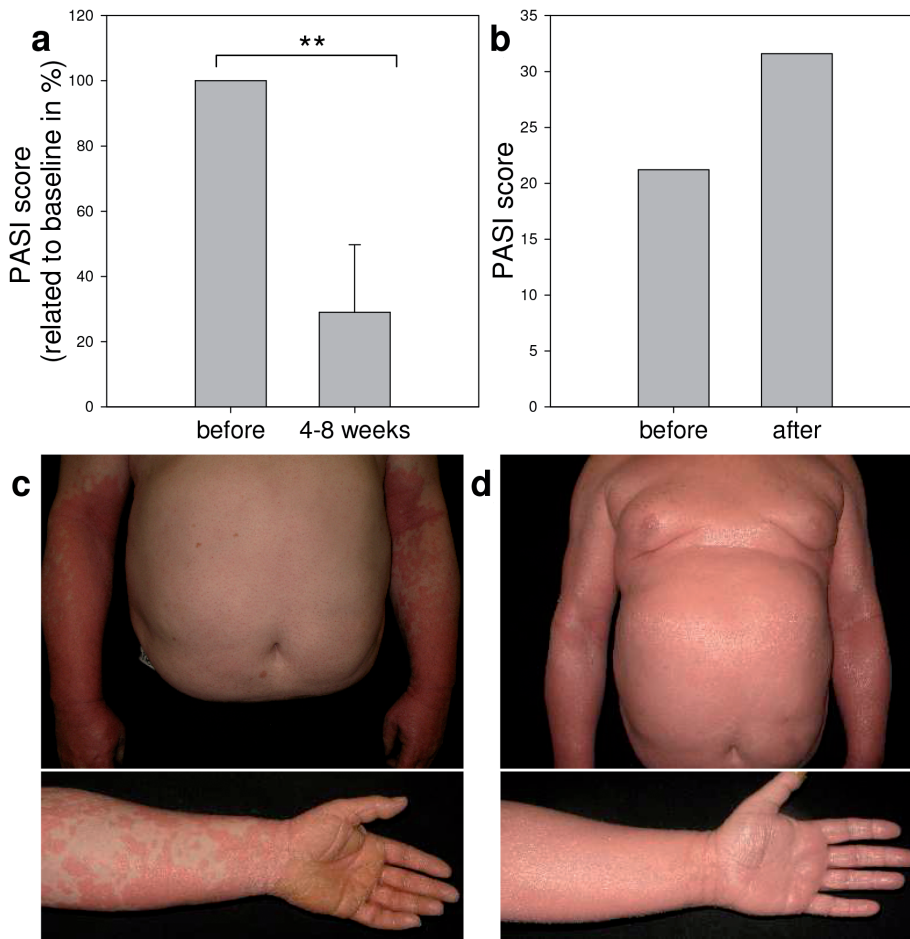


Fig. 2. (a) Significant reduction ($p=0.006$) of mean PASI score (bar represents SD) in alitretinoin responders (patients 1–4). (b, c) Patient 5 showed further PRP progress during 30 mg/day alitretinoin therapy (13 weeks). (d) Clinical appearance after 15 weeks of acitretin therapy (75 mg/day).

The authors declare no conflict of interest.

REFERENCES

- Amann PM, Eichmuller SB, Schmidt J, Bazhin AV. Regulation of gene expression by retinoids. *Curr Med Chem* 2011; 18: 1405–1412.
- Vahlquist A. Retinoids and the skin: from vitamin A in human epidermis to the pharmacology of oral retinoids in dermatology. In: Vahlquist A, Duvic M, editors. *Retinoids and carotenoids in dermatology*. London: Taylor & Francis, 2007: p. 55–68.
- Ruzicka T, Lynde CW, Jemec GB, Diepgen T, Berth-Jones J, Coenraads PJ, et al. Efficacy and safety of oral alitretinoin (9-cis retinoic acid) in patients with severe chronic hand eczema refractory to topical corticosteroids: results of a randomized, double-blind, placebo-controlled, multicentre trial. *Br J Dermatol* 2008; 158: 808–817.
- Letule V, Herzinger T, Ruzicka T, Molin S. Treatment of Darier disease with oral alitretinoin. *Clin Exp Dermatol* 2013; 38: 523–525.
- Irla N, Navarini AA, Yawalkar N. Alitretinoin abrogates innate inflammation in palmoplantar pustular psoriasis. *Br J Dermatol* 2012; 167: 1170–1174.
- Gånemo A, Sommerlund M, Vahlquist A. Oral alitretinoin in congenital ichthyosis: a pilot study shows variable effects and a risk of central hypothyroidism. *Acta Derm Venereol* 2012; 92: 256–257.
- Klein A, Landthaler M, Karrer S. Pityriasis rubra pilaris: a review of diagnosis and treatment. *Am J Clin Dermatol* 2010; 11: 157–170.
- Molin S, Ruzicka T. Treatment of refractory pityriasis rubra pilaris with oral alitretinoin: case report. *Br J Dermatol* 2010; 163: 221–223.
- Pampin A, Gomez-de la Fuente E, Caro Gutierrez MD, Lopez-Estebarez JL. Successful treatment of atypical adult pityriasis rubra pilaris with oral alitretinoin. *J Am Acad Dermatol* 2013; 69: e105–106.
- Schmitt L, Inhoff O, Dippel E. Oral alitretinoin for the treatment of recalcitrant pityriasis rubra pilaris. *Case Rep Dermatol* 2011; 3: 85–88.
- Xu J, Drew PD. 9-Cis-retinoic acid suppresses inflammatory responses of microglia and astrocytes. *J Neuroimmunol* 2006; 171: 135–144.
- Meyer V, Goerge T, Luger TA, Beissert S. Successful treatment of palmoplantar hyperkeratotic psoriasis with a combination of etanercept and alitretinoin. *J Clin Aesthet Dermatol* 2011; 4: 45–46.
- Wohlrab J, Kreft B. Treatment of pityriasis rubra pilaris with ustekinumab. *Br J Dermatol* 2010; 163: 655–656.
- Ruiz Villaverde R, Sanchez Cano D. Successful treatment of type 1 pityriasis rubra pilaris with ustekinumab therapy. *Eur J Dermatol* 2010; 20: 630–631.
- Petrof G, Almaani N, Archer CB, Griffiths WA, Smith CH. A systematic review of the literature on the treatment of pityriasis rubra pilaris type 1 with TNF-antagonists. *J Eur Acad Dermatol Venereol* 2013; 27: e131–135.