

## SHORT COMMUNICATION

# Eosinophilic Pustular Folliculitis Clinically Presenting as Orofacial Granuloma: Successful Treatment with Indomethacin, But Not Ibuprofen

Koji Ono, Takashi Hashimoto and Takahiro Satoh\*

Department of Dermatology, National Defense Medical College, 3-2 Namiki, Tokorozawa 359-8513, Japan. \*E-mail: [tasaderm@ndmc.ac.jp](mailto:tasaderm@ndmc.ac.jp)

Accepted Jun 30, 2014; Epub ahead of print Jun 30, 2014

Ofuji's disease, a classic type of eosinophilic pustular folliculitis (EPF), is an inflammatory eosinophilic disease characterised by pruritic follicular papules or pustules that tend to form in a circinate configuration. This condition often affects the face, and occasionally the trunk and extremities.

We wish to present an unusual presentation of EPF responding to indomethacin.

### CASE REPORT

A 60-year-old Japanese woman presented with a 4-month history of facial swelling. Physical examination revealed unilateral swelling of the left cheek with induration, minimal ill-defined erythema, and a slight follicular opening (Fig. 1A). Occasional itch was noted. Her past history included hypertension and myoma uteri that was treated surgically. Based on an initial clinical diagnosis of orofacial granuloma of the cheek, skin biopsy was performed. Histopathological examination showed dense dermal cellular infiltrates comprising lymphocytes and a number of eosinophils in perivascular and perifollicular areas. Eosinophils had infiltrated into the follicular epithelium and sebaceous glands (Fig. 1B). Laboratory tests showed blood eosinophilia (1,286/ $\mu$ l, normal <500  $\mu$ l). EPF was diagnosed, and treatment was started with oral ibuprofen (600 mg/day) for 3 weeks; however, facial swelling became rather more prominent with exacerbated erythema, exudates, and yellow crusting on skin surfaces (Fig. 1C). The patient was subsequently treated

with oral indomethacin farnesil (400 mg/day), achieving rapid regression of facial swelling (Fig. 1D). Blood eosinophil count decreased to 298/ $\mu$ l within 4 weeks.

### DISCUSSION

The clinical manifestation of the present case was peculiar in that skin symptoms lacked macroscopic papules and pustules, and showed orofacial granuloma-like swelling of the cheek. This caused difficulties in reaching a clinical diagnosis of EPF. Classic-type EPF uncommonly exhibits an atypical clinical appearance (1), and EPF lacking obvious pustules has also been described (2). In addition, some cases of classic EPF share morphological similarities with follicular mucinosis without macroscopic papules (3, 4).

EPF generally responds well to systemic indomethacin, a cyclooxygenase inhibitor. Indomethacin can even be used as a diagnostic tool. It has been proposed that in EPF, cyclooxygenases-dependent arachidonic acid metabolites may be responsible for eosinophil accumulation in hair follicles, explaining the therapeutic action of indomethacin by its inhibitory activity against cyclooxygenases (5). In addition, a recent finding suggested the involvement of prostaglandin (PG) D2 in the

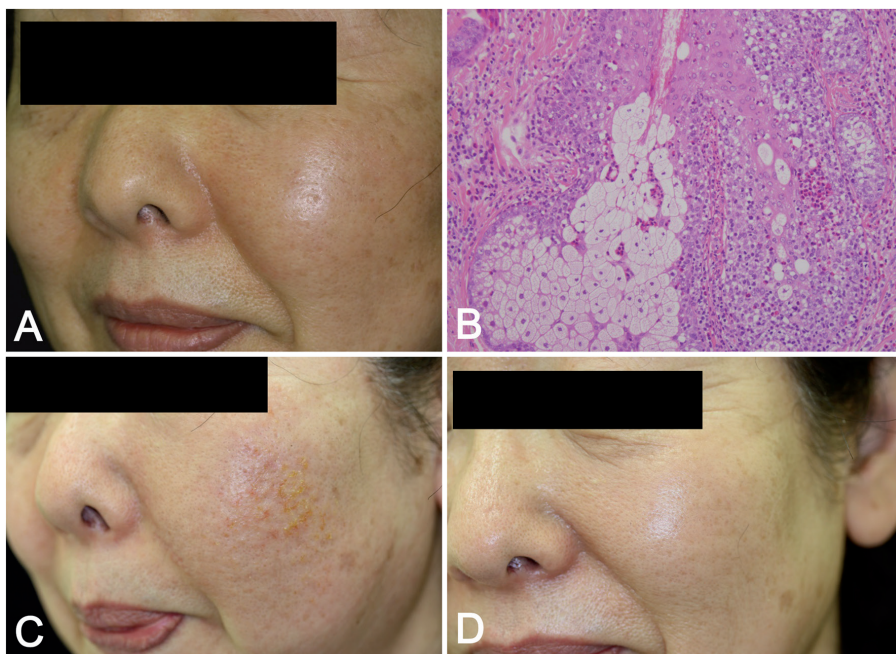


Fig. 1. Clinical and microscopic features of skin lesions. Swelling of the left cheek with minimal erythema (A). Dense cellular infiltrates comprising eosinophils and lymphocytes around hair follicles, follicular epithelium, and sebaceous glands (B). Exacerbation by ibuprofen treatment (C). Three weeks after indomethacin treatment (D).

pathogenesis of EPF (6). The present case was initially treated using ibuprofen, a cyclooxygenase inhibitor, based on the assumption that, like indomethacin, therapeutic effects should be exerted via inhibition of cyclooxygenases. However, ibuprofen aggravated rather than improved skin symptoms. This was in a sharp contrast to subsequent successful treatment with indomethacin. A prior report also described limited effects of another cyclooxygenase inhibitor, loxoprofen, against EPF (7). These findings provide intriguing clinical evidence that the therapeutic effects of indomethacin do not solely result from the inhibition of cyclooxygenases. In this regard, we have recently demonstrated a peculiar pharmacological action of indomethacin; down-modulation of the expressions and functions of CRTH2, a PGD2 receptor, and CCR3, a receptor for eotaxin-1 and -3, via homologous and cross-desensitisation, respectively, through agonistic function of indomethacin on CRTH2. This results in reduced eosinophil migration to these chemoattractants (8). Although arachidonic acid metabolites, particularly PGD2, seem to be involved in the pathogenesis of classic EPF, administration of cyclooxygenase inhibitors, i.e., non-steroidal anti-inflammatory drugs (NSAIDs), are not sufficient for effective treatment. Clinical benefits of indomethacin appear to be mediated by its unique pharmacological actions, which are not observed in other NSAIDs.

*The authors declare no conflict of interest.*

## REFERENCES

1. Matsumura Y, Miyachi Y. Atypical clinical appearance of eosinophilic pustular folliculitis of seborrheic areas of the face. *Eur J Dermatol* 2012; 22: 658–662.
2. Uchiyama M, Mitsuhashi Y, Okubo Y, Tsuboi R. Eosinophilic pustular folliculitis (Ofuji's disease) without macroscopic pustules. *Int J Dermatol* 2012; 51: 50–52.
3. Fujiyama T, Tokura Y. Clinical and histopathological differential diagnosis of eosinophilic pustular folliculitis. *J Dermatol* 2013; 40: 419–423.
4. Lee JY, Tsai YM, Sheu HM. Ofuji's disease with follicular mucinosis and its differential diagnosis from alopecia mucinosa. *J Cutan Pathol* 2003; 30: 307–313.
5. Takematsu H, Tagami H. Eosinophilic pustular folliculitis. Studies on possible chemotactic factors involved in the formation of pustules. *Br J Dermatol* 1986; 114: 209–215.
6. Nakahigashi K, Doi H, Otsuka A, Hirabayashi T, Murakami M, Urade Y, et al. PGD2 induces eotaxin-3 via PPARgamma from sebocytes: a possible pathogenesis of eosinophilic pustular folliculitis. *J Allergy Clin Immunol* 2012; 129: 536–543.
7. Fukamachi S, Kabashima K, Sugita K, Kobayashi M, Tokura Y. Therapeutic effectiveness of various treatments for eosinophilic pustular folliculitis. *Acta Derm Venereol* 2009; 89: 155–159.
8. Kataoka N, Satoh T, Hirai A, Saeki K, Yokozeki H. Indomethacin inhibits eosinophil migration to prostaglandin D2: therapeutic potential of CRTH2 desensitization for eosinophilic pustular folliculitis. *Immunology* 2013; 140: 78–86.