

SHORT COMMUNICATION

Pemphigoid Nodularis Mimicking Nodular Prurigo in an Immune-suppressed Patient with Rheumatoid Arthritis

Hui Li Kwong and Su-Ping Regina Lim

Department of Dermatology, Changi General Hospital, 2 Simei Street, 529889 Singapore, Singapore. E-mail: Huili.kwong@mohh.com.sg

Accepted Jun 3, 2014; Epub ahead of print Jun 5, 2014

Pemphigoid nodularis is a rare variant of pemphigoid. It classically presents with overlapping features of nodular prurigo and pemphigoid-like blisters which can be potentially misleading for the attending dermatologist. We present here a case of pemphigoid nodularis masquerading as nodular prurigo in an immunosuppressed patient with rheumatoid arthritis (RA).

CASE REPORT

An 80-year-old Chinese woman presented with a two-month history of a pruritic rash. The rash initially started on her arms, then gradually spread to her body and legs. She had multiple medical comorbidities which included stage II chronic renal failure, iron-deficiency anaemia, diabetes mellitus, and RA. Notably, her drug history included prednisolone (5 mg), sulphasalazine, leflunomide for her RA. Other medications included iron supplements, and medications for hypertension and peripheral vascular disease. There were no recent changes of her medications nor any traditional Chinese medicine use.

On examination, she had widespread excoriated papules and nodules mainly on the upper and lower limbs, with several on the trunk and lower back (Fig. 1). Some nodules contained a central core of keratin plugging. The rest of her skin was xerotic. Her face, groin and axillary regions were spared. There were no burrows in the web spaces of her hands and feet. Differential diagnoses initially considered included prurigo nodularis and perforating dermatoses.

Her initial pruritus screen (full blood count, liver and renal biochemistry and thyroid functions tests) was normal apart from the known iron-deficiency anaemia and chronic renal failure. A punch biopsy from a representative lesion on her right wrist showed irregular epidermal hyperplasia with slight spongiosis and confluent parakeratosis. A mild perivascular lymphocytic infiltrate was present (Fig. 2A). There were insufficient histological features to suggest perforating dermatoses and no suggestive features of pemphigoid.

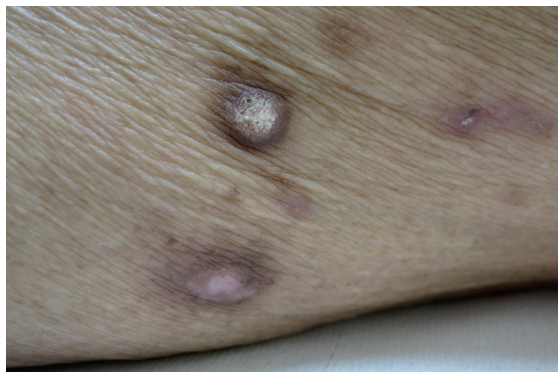


Fig. 1. Nodular prurigo on right thigh.

She was initially treated with topical betamethasone valerate 0.1% cream, emollients and antihistamines. However, this failed to alleviate her intense and troubling pruritus, and she was gradually escalated to clobetasol propionate over a period of 3 months. She was unable to undergo narrow-band UVB as she was wheelchair bound, and additional immune suppression was difficult as she was already on multiple agents for RA. Her prednisolone dose was then increased to 10 mg after a discussion with her rheumatologist.

Ten months after initial presentation, she developed 2 discrete tense blisters, one on her back and one on her left nipple. A skin punch biopsy from her back showed a spongiotic epidermis with a subepidermal blister. There was some mild perivascular lymphocytic infiltration. No eosinophils were seen (Fig. 2B). Her blood eosinophil count was normal ($0.2 \times 10^3 \mu\text{l}$; normal range: $0.0\text{--}0.4 \times 10^3 \mu\text{l}$). Direct immunofluorescence showed linear deposition of IgG and C3 at the basement membrane zone. Indirect immunofluorescence was positive with a roof pattern and titre of $> 1/160$. This was consistent with a diagnosis of pemphigoid nodularis.

Her prednisolone was further increased to 20 mg, with improvement in her symptoms and no further blister formation. At her most recent follow-up, there was improvement with reduction of the prurigo nodularis lesions, and no new blisters.

DISCUSSION

Pemphigoid nodularis is a rare and unusual clinical variant of pemphigoid. Its incidence is unknown, but it predominantly affects elderly females (1). The lesions

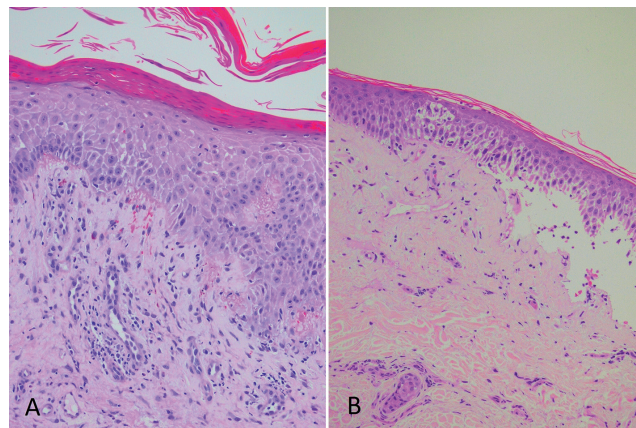


Fig. 2. A punch biopsy from a representative lesion on her right wrist showed irregular epidermal hyperplasia with slight spongiosis and confluent parakeratosis. A mild perivascular lymphocytic infiltrate is present (haematoxylin and eosin $\times 400$) (A). Spongiotic epidermis with a subepidermal blister. There is a mild perivascular lymphocytic infiltrate. Note the lack of eosinophils. (Haematoxylin and eosin $\times 200$) (B).

of nodular prurigo may precede the development of blisters by months to years, and can be recalcitrant despite the use of potent topical corticosteroids or even immunosuppressants. Some patients may not develop blisters throughout the whole course of their condition, despite demonstrating the immunohistochemical features of bullous pemphigoid (1).

A small case series comparing patients with pemphigoid nodularis and patients with nodular prurigo suggested that the nodules in pemphigoid nodularis are more erythematous, with most lesions showing larger areas of erosions and ulcerations (2). Patients may also develop large erythematous plaques with erosions and ulcerations particularly at the extremities (2). Direct immunofluorescence studies in pemphigoid nodularis demonstrate the linear deposition of IgG and C3 at the dermal–epidermal junction, while indirect immunofluorescence studies document the presence of circulating IgG to the basement membrane zone (3). These findings are also characteristic of bullous pemphigoid.

The pathogenesis of pemphigoid nodularis is unknown (4). It has been suggested that physical trauma to the skin and basement membrane from recurrent scratching induces pemphigoid autoantibodies (4). This may account for the findings of a positive direct immunofluorescence study in nodular lesions and a negative result in normal skin, as reported by Yung et al. (4). BP 180 and BP 230 are the target antigens in pemphigoid nodularis. Newer studies have shown that the BP180 NC16A domain is the target epitope of autoantibodies in some patients with pemphigoid nodularis (5).

Our patient had recalcitrant nodular prurigo despite use of superpotent topical corticosteroids. She only improved symptomatically and clinically after an increase in oral prednisolone. Other patients with pemphigoid nodularis were similarly reported to have lesions and symptoms resistant to potent topical corticosteroids (6). Control of symptoms and lesions in these patients was

only achieved with immunosuppressants such as prednisolone, dapsone and azathioprine (6). Our patient did not develop blisters until 10 months into her condition. Her histology was also lacking in eosinophils, which is in contrast to the typical eosinophilia seen in bullous pemphigoid. We believe that her long-term low dose prednisolone therapy for her RA may have contributed to this and the initial lack of blistering component, then only developing 2 isolated blisters much later. Interestingly, the intense pruritus remained constant despite the pre-existing immunosuppression.

ACKNOWLEDGEMENT

The authors would like to thank Dr Sim Chee Seng, Department of Histopathology, Changi General Hospital, Singapore, for the tissue photomicrograph.

REFERENCES

1. Powell AM, Albert S, Gratian MJ, Bittencourt R, Bhogal BS, Black MM. Pemphigoid nodularis (non-bullous): a clinicopathological study of five cases. *Br J Dermatol* 2002; 147: 343–349.
2. Ray J, Camilleri M. P2202 Pemphigoid nodularis: Two new cases demonstrating distinguishing clinical clues from prurigo nodularis. *J Am Acad Dermatol* 2009; AB104.
3. McGinness JL, Bivens MC, Greer K, Patterson J, Saulsbury F. Immune dysregulation, polyendocrinopathy, enteropathy, X-linked syndrome (IPEX) associated with pemphigoid nodularis: A case report and review of the literature. *J Am Acad Dermatol* 2006; 55: 143–148.
4. Yung C, Soltani K, Lorincz AL. Pemphigoid nodularis. *J Am Acad Dermatol* 1981; 5: 54–60.
5. Schachter M, Brieva JC, Jones JC, Zillikens D, Skrobek C, Chan LS. Pemphigoid nodularis associated with autoantibodies to the NC16A domain of BP180 and a hyperproliferative integrin profile. *J Am Acad Dermatol* 2001; 45: 747–754.
6. Cliff S, Holden CA. Pemphigoid nodularis: a report of three cases and review of the literature. *Br J Dermatol* 1997; 136: 398–401.