

CLINICAL REPORT

Immunotherapy-induced Leukoderma from Treatment of Melanoma with IL-2: A Case Report and a Review of the Literature

Robert GATHINGS¹, Robin LEWALLEN² and Gil YOSIPOVITCH³

¹School of Medicine, University of Mississippi Medical Center, Jackson, Departments of Dermatology, ²Wake Forest Baptist Medical Center, Winston-Salem, and ³Temple University, Philadelphia, USA

Melanoma-associated leukoderma (MAL) is a relatively uncommon phenomenon in the literature that can present (1) before melanoma detection, (2) after detection and before treatment, and (3) after treatment with immunotherapeutic agents. We report a case of MAL in an 83-year-old man after treatment with high dose IL-2 for metastatic melanoma and further describe the literature of the underlying mechanisms behind it that involve the immune system. Cytotoxic CD8⁺ T cells are thought to mediate the process at a cellular level. Self-antigens (e.g. MART-1/2, gp100, tyrosinase) have been presented on the surface of both normal and malignant melanocytes and mediate the development of MAL after cytotoxic CD8⁺ T cells attack both cell types. Autoimmune manifestations have a positive effect on tumor immunity, with patients at stage III and stage IV melanoma showing a better prognosis after leukoderma development. In addition, immunotherapy-induced leukoderma has been associated with a higher therapeutic response rate. Recently, newer immunotherapeutic drugs, such as vemurafenib and ipilimumab, have been associated with leukoderma as a side effect. *Key words: leukoderma; vitiligo; melanoma; immunotherapy; autoimmunity.*

Accepted May 12, 2014; Epub ahead of print May 13, 2014

Acta Derm Venereol 2015; 95: 197–200.

Gil Yosipovitch, MD, Professor and Chair, Department of Dermatology, Director Temple Itch Center, Temple University School of Medicine, 3322 North Broad Street, Medical Office Building - Suite 212, Philadelphia, PA 19140, USA. E-mail: gil.yosipovitch@tuhs.temple.edu

As immunotherapy treatments for melanoma have advanced over the last decade, it is important to re-examine the association between leukoderma and melanoma. One of the known side-effects of immunotherapeutic agents for melanoma, such as interleukin-2 (IL-2), vemurafenib, and ipilimumab, is leukoderma; however leukoderma has also been associated with higher rates of metastatic melanoma, as well as preceding the detection of melanoma (1–5). Collectively, this phenomenon is called melanoma-associated leukoderma (MAL). Understanding the temporal relationship between the onset of the leukoderma in relation to the development and treatment

of melanoma is essential and has important prognostic implications. We herein report a case of leukoderma in a patient with metastatic melanoma treated with IL-2 immunotherapy and subsequently discuss the various causes of leukoderma in melanoma patients.

CASE REPORT

An 83-year-old man presented to our dermatology clinic for a routine skin exam. He was diagnosed with Stage 2B (T3bN0M0) melanoma of the right lower extremity 7 years previously. At the time of the original diagnosis, he underwent wide local excision with 2.5 cm margins and sentinel lymph node dissection during which 3 out of 3 nodes were found to be negative. Histological features of the lesion consisted of a 3.0 mm Breslow depth and Clark level IV with architecture of this lesion suggestive of metastasis. He then developed recurrent disease in the incision site 8 months later and underwent a 2nd sentinel lymph node dissection, which was positive in 3 of 5 nodes. He was treated with localized external beam radiation. During a follow-up exam 3 months after completing external beam radiation, he was found to have enlarged lymph nodes in his left groin, which was confirmed to be metastatic melanoma by fine needle aspiration biopsy. CT scan at that time also confirmed an enlarged obturator node. He was subsequently treated with 4 courses of high dose IL-2 (600,000 IU/kg). Within one month of beginning treatment with IL-2, the patient developed widespread leukoderma of his face, trunk, back, arms, and legs (Fig. 1), which progressively worsened over the following months. At a later follow-up, the patient had been without recurrence for 5 years.

DISCUSSION

The development of leukoderma post treatment with IL-2 for melanoma has been previously reported (1–5). However the occurrence of leukoderma in association with newer immunomodulating drugs, such as vemurafenib and ipilimumab, has just recently been reported (6, 7). It is important for dermatologists to know about this potential side-effect and the underlying putative mechanisms behind it that involve the immune system.

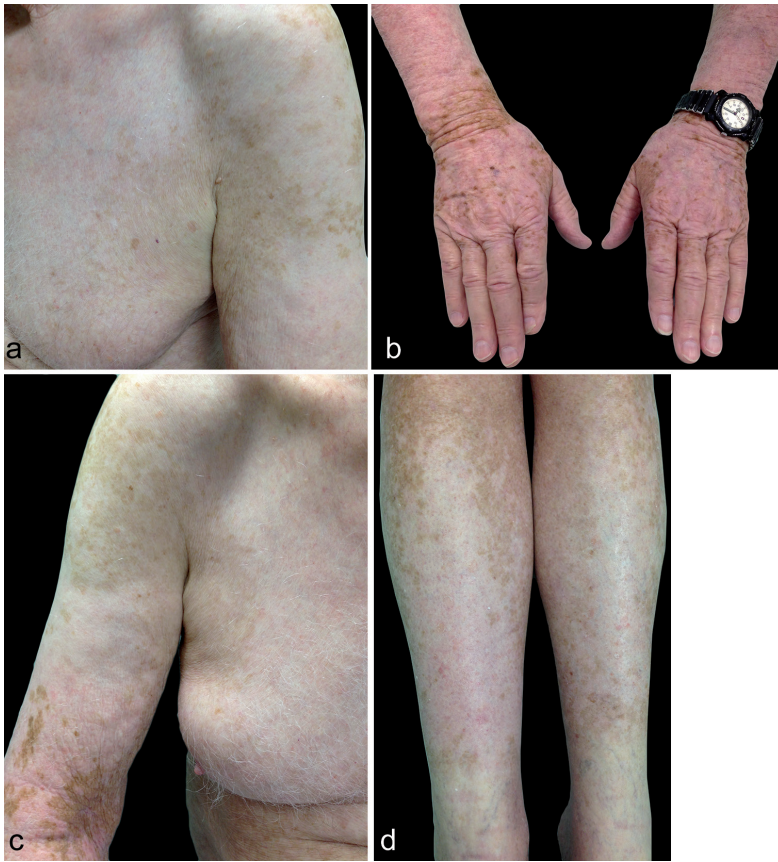

Fig. 1. Generalized vitiligo on left arm and chest (a), hands (b), right arm (c) and legs (d) after treatment with IL-2 for malignant melanoma.

IL-2 has many effects on the immune system including, but not limited to, playing a vital role in allowing cells to discriminate between “self” and “non-self” antigens (8). In a normal immune response, CD4⁺ T cells are presented an antigen; if the CD4⁺ T cell recognizes the antigen, the cell becomes activated and IL-2 is released (8). IL-2 has a positive feedback on the CD4⁺ T cell resulting in immunologic memory, as well as recruiting other immune cells including CD8⁺ T cells, also known as cytotoxic T lymphocytes (CTLs) (8) (Fig. 2). IL-2 also up-regulates the transcription of perforin and granzyme, which are essential in the cytotoxic action of activated CD8⁺ T cells (9). Thus, IL-2 promotes a robust immune response.

Similarly, ipilimumab is a fully human antibody that blocks the cytotoxic T-lymphocyte-associated antigen 4 (CTLA-4) inhibitory signal (6) (Fig. 3). Normally, melanoma cells produce antigens, which

are processed and presented on the surface of the cell to the CTLs by antigen presenting cells (APCs). If this process is carried out in the presence of CTLA-4 the interaction is inhibited, thus preventing CTLs from attacking “self” antigens (6). Ipilimumab blocks the binding of CTLA-4 while the APCs are presenting to the CTLs, allowing for a robust immune response (6). However, this is one of the important interactions that prevents the CTLs from accidentally reacting to “self” antigens, which is why there is increased likelihood for an autoimmune response in the absence of CTLA-4 interaction. Targeted therapy is a relatively new frontier, with vemurafenib and ipilimumab offering options for unresectable, stage IV metastatic melanoma disease. Vemurafenib is a *BRAF*-V600E inhibitor that is very effective for half of metastatic melanoma patients expressing an altered *BRAF* (10). However, while response is usually quick, it is typically only for a short duration with minimal long-lasting effects. Ipilimumab is a CTLA-4 blocking antibody with low rates of response (20%), but more durable effects when compared with vemurafenib (10).

CTLs are primarily thought to mediate the development of leukoderma (8). In MAL, the immune system is attacking “self-antigens” located within melanosomes of melanocytes such as MART-1/2, gp100 and tyrosinase (8, 11, 12). These “self-antigens” are processed and presented as derived peptides on the surface of the melanocyte.

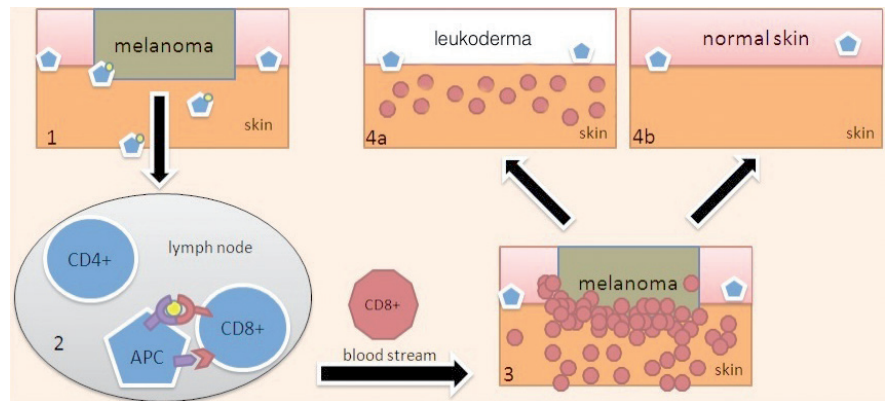


Fig. 2. Malignant melanocyte antigen on antigen presenting cell (APC) travels from the skin to the regional lymph node (1). The APC interacts with CD4⁺ and CD8⁺ cytotoxic T lymphocytes (CTLs) T cells. This interaction results in more effective immunotherapy with IL-2 as it strengthens activation of CTLs. Ipilimumab also affects activation of CTLs by blocking one of the down-regulating receptors, CTL-associated antigen 4. When this is blocked there is a strong up-regulatory interaction between the APC and the CTLs (2). The activated effector CTLs travel via the bloodstream back to the skin. The CTLs recognize the antigens present on the malignant melanocytes and attack the designated cells (3). If the antigen present on the malignant melanocytes is similar to or the same as that on native melanocytes then leukoderma occurs (4a). If the antigen is unique to the malignant melanocytes and does not cross react with native melanocytes then leukoderma does not occur (4b).

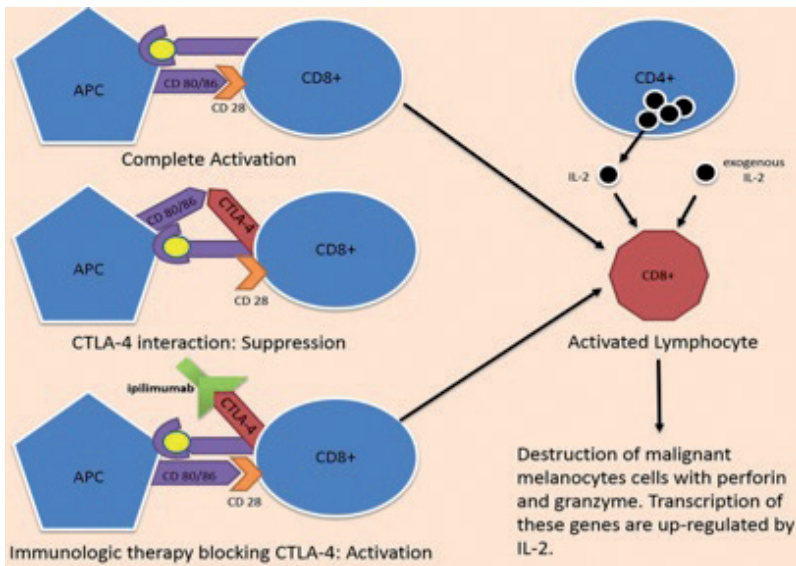


Fig. 3. Ipilimumab is a fully human antibody that blocks the cytotoxic T-lymphocyte-associated antigen 4 (CTLA-4) inhibitory signal. The CTLA-4 inhibitory signal, when present, binds cell-surface markers CD80 and CD86. In the absence of the CTLA-4 inhibitory signal binding against cell-surface markers CD80 and CD86, complete activation between an antigen presenting cell (APC) and a CD8⁺ lymphocyte occurs. An activated CD8⁺ lymphocyte is able to destroy malignant melanocytic cells with perforin and granzyme, enzymes whose transcription is up-regulated by IL-2. In the presence of the CTLA-4 inhibitory signal binding against CD80 and CD86, the APC is not able to activate the CD8⁺ lymphocyte, resulting in a suppressed immune response. Immunologic therapy with ipilimumab blocks CTLA-4 inhibitory signal resulting in a robust immune response.

Immunomodulating chemotherapeutic agents for melanoma promote activation of a cellular immune response against the malignant melanocytes. Unfortunately, there are many instances in which the immunity against the tumor cells cross-react with normal melanocytes because they express many of the same derived surface antigens (8, 11, 12).

It has previously been suggested that autoimmune destruction of normal melanocytes cross-react with immune destruction of malignant melanocytes which provides T-cell immunity against malignant melanocytes in leukoderma patients (11). The relationship is two-fold: CTLs removed from leukoderma patients have been shown to destroy malignant melanocytes *ex vivo*, while CTLs removed from tumors and peripheral blood of patients with melanoma have been shown to attack normal melanocytes (8, 12, 13). In a study by Rosenberg & White (14), 74 patients with melanoma and 104 patients with renal cell carcinoma were treated with IL-2. Eleven of the 74 patients with melanoma developed leukoderma and all of these patients showed an objective response to IL-2. Interestingly, no patients with renal cell carcinoma developed leukoderma, suggesting that a robust immune response to malignant melanocytes may cross-react with normal melanocytes resulting in leukoderma as a possible mode of pathogenesis (11).

There are several scenarios in which MAL can manifest in a melanoma patient and each has distinct ramifications. Rarely, MAL has appeared with distant melanoma metastases before the detection of a melanoma with unknown primary (MUP) (1–4), with an estimated incidence of 0.6% in a study by Quaglino et al. (5). In all of these cases, MAL preceded the detection of MUP rather than the development of MUP. In other instances, MAL has appeared after the development of melanoma but before treatment (5). Lastly, as in our case, leukoderma has been immunotherapy-induced

after treatment with IL-2, vemurafenib, or ipilimumab, and is associated with robust response to treatment and a lower risk of recurrent melanoma (11). In the latter two instances Quaglino et al. (5) found the combined occurrence of leukoderma after the development of melanoma to be 2.2%. This is why it is important to ask the patient about the temporal relationship between the onset of the melanoma and the development of leukoderma.

In our patient, after completion of immunomodulating chemotherapy with IL-2 he developed generalized leukoderma secondary to the robustly generated anti-melanocyte antigen immune response. High-dose IL-2 (720,000 IU/kg, intravenously administered every 8 hours as tolerated for 5 days) was FDA approved in 1998 for the treatment of stage IV metastatic melanoma (11). Overall, treatment of melanoma with high-dose IL-2 is associated with a 15% response rate. One-third of these patients experience a complete response, with durable and long-lasting immunity leading to an effective long-term remission (11). While a study by Phan et al. (11) suggested a higher prevalence of leukoderma development post-treatment with IL-2 (84 of 374 patients or 22%), according to the largest scale study performed to date, the estimated incidence of developing leukoderma post-treatment with IL-2 is roughly 3% (5).

Several studies have shown that melanoma patients treated with high-dose IL-2 who develop immunotherapy-induced leukoderma have a much higher chance of tumor response than patients who do not develop leukoderma (5, 11). Phan et al. (11) studied 374 patients with melanoma treated with IL-2 and found that anti-tumor response was best mounted in patients who met several criteria, one of which included the development of leukoderma after treatment with immunotherapy. Of the 84 patients with leukoderma, 33% were responders (defined as > 50% reduction of the maximum perpendicular diameters lasting at least one month with no new

or enlarging tumors) compared to 10% responders in the study participants without leukoderma (11). Recently, leukoderma was examined as an independent entity in 66 of 2,954 patients with melanoma and found to be associated with a better prognosis in stage III and stage IV melanoma (5 year survival of 65% vs. 42.5% in patients without leukoderma; mean survival time 14.4 vs. 9.6 months in patients without leukoderma). Of the 528 patients treated with immunotherapy for melanoma, only 16 (3%) developed leukoderma (5).

MAL tends to vary in presentation clinically depending on the initiating event and timing of onset. In the most prognostically concerning form of leukoderma, which can precede the detection of distant melanoma metastases with unknown primary, the distribution has been found to be more similar to the generalized form of vitiligo vulgaris. It develops in younger patients as well demarcated, oval/round shaped, hypomelanotic patches on the face, upper extremities and feet (5). It is important to note that MAL preceding detection of MUP is distinct from generalized vitiligo vulgaris, the latter of which is not associated with MUP and has recently been shown to be associated with a 3-fold decreased risk of future development of melanoma (15). Therefore, vitiligo vulgaris present in patients who later go on to develop melanoma is likely coincidental and due to random variation within a population. In immunotherapy-induced leukoderma, the literature offers contradicting evidence with regards to presentation. A study by Quaglino et al. (5) reported a more localized form of leukoderma confined to the face including perioral and periorbital areas as well as the upper trunk with irregular patches and pale (but not white) color. Previously, Hartmann et al. (16) suggested a more symmetrical, bilateral presentation with centripetal spreading to the trunk. Recently, two cases of vemurafenib-associated leukoderma were reported with almost identical clinical manifestations: symmetrical, patchy depigmentation of the face (7). In order to further clarify the clinical presentations, more large-scale investigations may be needed.

As melanoma therapy with immune modifiers is expanding, it is important to understand the varying clinical presentations of MAL. While leukoderma development secondary to immunotherapy treatment is associated with a higher response rate, not recognizing MUP before the onset of MAL can have significant prognostic consequences for the patient. While immunotherapy-induced leukoderma has been reported in the literature, our goal is to raise awareness regarding the importance of the timing of the onset of leukoderma and its prognostic implications. In addition, by understanding the pathophysiology of leukoderma, clinicians can gain better insight into the relationship between autoimmunity and tumor immunity. Understanding the development of tumor immunity can provide prognostic information for the patients and their providers.

The authors declare no conflict of interest.

REFERENCES

1. Cho EA, Lee MA, Kang H, Lee SD, Kim HO, Park YM. Vitiligo-like depigmentation associated with metastatic melanoma of an unknown origin. *Ann Dermatol* 2009; 1: 178–181.
2. Onsun N, Büyükbabani N, Ummetoğlu O, Cebeci F. Do we have to pay more attention to vitiligo patients? Peculiar histopathological features of primary cutaneous melanoma preceded by vitiligo. *J Dermatol* 2009; 36: 612–615.
3. Redondo P, Del Olmo J. Images in clinical medicine. Vitiligo and cutaneous melanoma. *N Engl J Med* 2008; 359: e3.
4. Wang JR, Yu KJ, Juan WH, Yang CH. Metastatic malignant melanoma associated with vitiligo-like depigmentation. *Clin Exp Dermatol* 2009; 34: 209–211.
5. Quaglino P, Marengo F, Osella-Abate S, Cappello N, Ortoncelli M, Salomone B, et al. Vitiligo is an independent favourable prognostic factor in stage III and IV metastatic melanoma patients: Results from a single-institution hospital-based observational cohort study. *Ann Oncol* 2010; 21: 409–414.
6. Minkis K, Garden BC, Wu S, Pulitzer MP, Lacouture ME. The risk of rash associated with Ipilimumab in patients with cancer: A systematic review of the literature and meta-analysis. *J Am Acad Dermatol* 2013; 69: e121–e128.
7. Alonso-Castro L, Ríos-Buceta L, Vano-Galvan S, Moreno C, Soria-Rivas A, Jaén P. Vitiligo in 2 patients receiving vemurafenib for metastatic melanoma. *J Am Acad Dermatol* 2013; 69: e28–e29.
8. Byrne KT, Turk MJ. New perspectives on the role of vitiligo in immune responses to melanoma. *Oncotarget* 2011; 2: 684–694.
9. Janas ML, Groves P, Kienzle N, Kelso A. IL-2 regulates perforin and granzyme gene expression in CD8+ T cells independently of its effects on survival and proliferation. *J Immunol* 2005; 175: 8003–8010.
10. Banaszynski M, Kolesar JM. Vemurafenib and ipilimumab: new agents for metastatic melanoma. *Am J Health Syst Pharm* 2013; 70: 1205–1210.
11. Phan GQ, Attia P, Steinberg SM, White DE, Rosenberg SA. Factors associated with response to high-dose interleukin-2 in patients with metastatic melanoma. *J Clin Oncol* 2001; 19: 3477–3482.
12. Yee C, Thompson JA, Roche P, Byrd DR, Lee PP, Piepkorn M, et al. Melanocyte destruction after antigen-specific immunotherapy of melanoma: direct evidence of T cell-mediated vitiligo. *J Exp Med* 2000; 192: 1637–1644.
13. Byrne KT, Côté AL, Zhang P, Steinberg SM, Guo Y, Allie R, et al. Autoimmune melanocyte destruction is required for robust CD8+ memory T cell responses to mouse melanoma. *J Clin Invest* 2011; 121: 1797–1809.
14. Rosenberg SA, White DE. Vitiligo in patients with melanoma: normal tissue antigens can be targets for cancer immunotherapy. *J Immunother Emphasis Tumor Immunol* 1996; 19: 81–84.
15. Teulings HE1, Overkamp M, Ceylan E, Nieuweboer-Krobotova L, Bos JD, Nijsten T, et al. Decreased risk of melanoma and nonmelanoma skin cancer in patients with vitiligo: a survey among 1307 patients and their partners. *Br J Dermatol* 2013; 168: 162–171.
16. Hartmann A, Bedenk C, Keikavoussi P, Becker JC, Hamm H, Bröcker EB. Vitiligo and melanoma-associated hypopigmentation (MAH): shared and discriminative features. *J Dtsch Dermatol Ges* 2008; 6: 1053–1059.