

## SHORT COMMUNICATION

## A Syndrome of Leuconychia, Koilonychia and Multiple Pilar Cysts

Mayuko Mutoh<sup>1</sup>, Shiro Niiyama<sup>1\*</sup>, Saori Nishikawa<sup>1</sup>, Toshiaki Oharaseki<sup>2</sup> and Hideki Mukai<sup>1</sup>Departments of <sup>1</sup>Dermatology and <sup>2</sup>Pathology, Toho University Ohashi Medical Center, 2-17-6 Ohashi, Meguro-ku, Tokyo, 153-8515 Japan. \*E-mail: sniiyama@aol.com

Accepted Apr 30, 2014; Epub ahead of print May 9, 2014

Familial leuconychia with pilar cysts is a rare autosomal dominant condition, previously reported in 6 families. The molecular basis of the disorder is unknown. We report a family of 5 generations with leuconychia, koilonychia and multiple pilar cysts segregating as an autosomal dominant trait.

## CASE REPORT

The patient is a 72-year-old man who, at the age of 25 years began to develop recurrent, multiple cysts localised on the scalp, back and thigh. He had undergone surgical removal of 10 lesions and was examined this time to have the residual cysts excised. Physical examination showed cysts measuring 12–65 mm, 4 in the occipital region, 1 each in both shoulder regions, and 1 in the dorsal region (Fig. 1a). He also presented leuconychia and koilonychia of fingers and toes since early infancy (Fig. 1b). Clinical examination did not reveal any other signs or associated symptoms. There was no evidence of ciliary dystrophy. Microscopically, the cysts showed typical features of the trichilemmal-pilar type. He has a past history of renal calculus, and multiple cysts with concurrent leuconychia run in the

patient's family line (Fig. 1c). Moreover, the probandus and his son have koilonychia.

## DISCUSSION

The association of familial leuconychia totalis with multiple pilar cysts is a rare condition that could represent a separate syndromic entity. Since Bauer described a family with leuconychia totalis and sebaceous cysts in 1920, only 5 other families have been reported. In 1975, Bushkell & Gorlin (1) published the association of inherited leuconychia and sebaceous cysts with a history of renal stones. In 1986, Friedel et al. (2) proposed the term of "FLOTCH syndrome" (acronym for Familial occurrence of total LeukOnychia, Trichilemmal cysts and Ciliary dystrophy with dominant autosomal Hereditary) due to members of an affected family with multiple cysts and leuconychia who also presented ciliar dystrophy. In 1997, Slee et al. (3) suggested that pancreatitis may be a complication of this syndromic entity. In 2008, Morin et al. (4) presented a family with leuconychia and recurrent sebaceous cysts. They observed an ependymoma and bilateral acoustic neuromas in an affected member and proposed that the risk for nervous tumours may be high

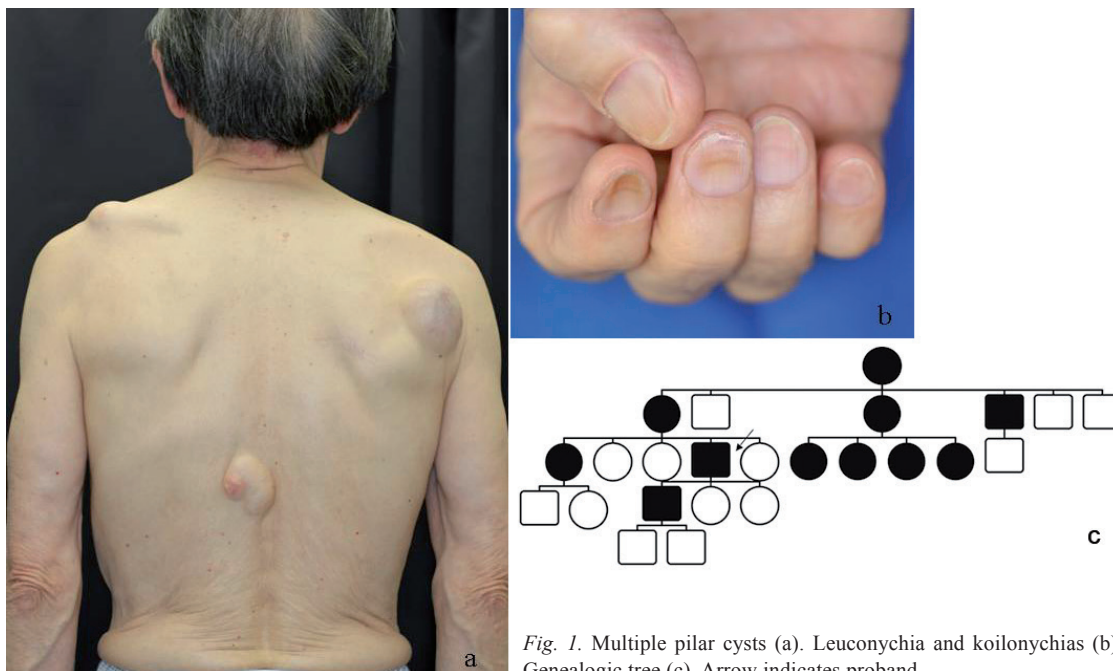


Fig. 1. Multiple pilar cysts (a). Leuconychia and koilonychias (b). Genealogic tree (c). Arrow indicates proband.

in some of these families. In 2011, Rodríguez-Lojo et al. (5) reported a 5-generation family with total leuconychia and multiple pilar cysts on scalp.

In the present case, not only leuconychia but also koilonychia was noted, and cases of patients suffering both concurrent nail manifestations have been documented (1, 3). Ciliar dystrophy was reported in a case described in (2), but no such concurrent manifestations have as yet been reported in other families. A more thorough examination might have disclosed their development; however, it cannot be conclusively stated whether koilonychia and ciliar dystrophy definitely occur as associated features. Leuconychia results from a defect in keratinisation leading to the presence of large immature nucleated cells. The keratohyaline-containing cells reflect light and prevent the visualisation of the vascular bed (6). In koilonychia, proliferation of connective tissue and sometimes increased vascular flow causes the fingernails to lift up. The depressed distal portion of the affected toenails may reflect distal connective tissue anoxia and atrophy (6). Very few cases of sporadic leuconychia totalis with koilonychia have been reported (6–8). It would be important to examine patients with both these manifestations for any pilar cysts. Whilst pilar cysts usually have a propensity for developing on the scalp, they occur also in other regions of the body in patients with pilar cysts and concurrent leuconychia.

The hypothesis of a gene deficiency affecting the structure of keratin has been postulated but the exact genetic mechanism has not yet been determined (4). This report is the first to document an affected family of the Asian race.

## ACKNOWLEDGEMENTS

The authors are indebted to the proband and his family members for their cooperation in securing the required information.

*The authors declare no conflict of interest.*

## REFERENCES

1. Bushkell LL, Gorlin RJ. Leukonychia totalis, multiple sebaceous cysts, and renal calculi. *Arch Dermatol* 1975; 111: 899–901.
2. Friedel J, Heid E, Grosshans E. The FLOTCH syndrome. Familial occurrence of total LeukOnychia, Trichilemmal cysts and Ciliary dystrophy with dominant autosomal Heredity. *Ann Dermatol Venereol* 1986; 113: 549–553.
3. Slee JJ, Wallman IS, Goldblatt J. A syndrome of leukonychia totalis and multiple sebaceous cysts. *Clin Dysmorphol* 1997; 6: 229–233.
4. Morin G, Desenclos C, Jeanpetit C, Lévy N, Deramond H, Mathieu M. Additional familial case of subtotal leukonychia and sebaceous cysts (Bauer syndrome): belong the nervous tumours to the phenotype? *Eur J Med Genet* 2008; 51: 436–443.
5. Rodríguez-Lojo R, Del Pozo J, Sacristán F, Barja J, Piñeyro-Molina F, Pérez-Varela L. Leukonychia totalis associated with multiple pilar cysts: report of a five-generation family: FLOTCH syndrome? *Eur J Dermatol* 2011; 21: 484–486.
6. Kwon NH, Kim JE, Cho BK, Jeong EG, Park HJ. Sporadic congenital leukonychia with koilonychia. *Int J Dermatol* 2012; 51: 1400–1402.
7. Baran R, Martinon J. Association of total leukonychia and koilonychia. *Bull Soc Fr Dermatol Syphiligr* 1967; 74: 571–572.
8. Brown PJ, Padgett JK, English JC III. Sporadic congenital leukonychia with partial phenotype expression. *Cutis* 2000; 66: 117–119.