

SHORT COMMUNICATION

DIHS/DRESS with Remarkable Eosinophilic Pneumonia Caused by Zonisamide

Rintaro Shibuya¹, Hideaki Tanizaki¹, Saeko Nakajima¹, Itsuko Koyanagi², Tatsuki R. Kataoka², Yoshiki Miyachi¹ and Kenji Kabashima^{1*}¹Department of Dermatology, Kyoto University Graduate School of Medicine, 54 Shogoin, Kawahara-cho, Sakyo-ku, Kyoto 606-8507, and ²Department of Diagnostic Pathology, Kyoto University Hospital, Kyoto, Japan. *E-mail: kaba@kuhp.kyoto-u.ac.jp

Accepted Apr 1, 2014; Epub ahead of print Apr 3, 2014

Drug-induced hypersensitivity syndrome (DIHS), also known as drug reaction with eosinophilia and systemic symptoms (DRESS), is a rare and severe skin disease associated with systemic findings, such as fever, eosinophilia, lymphadenopathy, and internal organ involvement that typically develops 2 to 6 weeks after the drug intake, following a prolonged course with frequent flare-ups and relapses over weeks or even months after discontinuing the drug. This syndrome has been reported to be associated with the intake of anticonvulsants, sulfonamides and allopurinol (1). Several mechanisms are involved in its pathophysiology, such as drug toxicity, immunological imbalance and reactivation of the herpes virus family members. Recently, a certain type of human leucocyte antigen (HLA) was identified as a predisposing factor in DIHS/DRESS. Here, we describe a case of DIHS/DRESS with remarkable eosinophilic pneumonia caused by zonisamide.

CASE REPORT

A 46-year-old woman was referred to our hospital with a spiking fever, dry cough and skin rash. She had a past medical history of subarachnoid haemorrhage due to hereditary haemorrhagic telangiectasia (HHT) and had commenced zonisamide 8 months before. She had been administered with zonisamide for 2 months, and followed by a washout period of 4 months. On the 41st day of the second course of treatment, she developed fever with chills, dry cough, and progressive non-pruritic maculopapular eruption with mucosal involvement (Fig. 1 a, b).

She was hospitalised for further evaluation. Blood tests revealed white blood cell count 8,800/mm³ (11% eosinophils, 49% neutrophils and 27% lymphocytes) and platelet count 227,000/mm³. Liver function test results were elevated: aspartate aminotransferase (AST) 67 U/l, alanine aminotransferase (ALT) 133 U/l; alkaline phosphatase (ALP) 220 U/l. Serologic tests for viral infections, including hepatitis B, hepatitis C, Epstein-Barr virus (EBV), cytomegalovirus, and human herpes virus 6 (HHV6) were negative. A chest radiograph did not reveal a pulmonary infiltration. A skin biopsy of the erythematous eruption on her abdomen exhibited spongiosis and vacuolar degeneration of epidermal basal keratinocytes. Lymphocytic perivascular infiltration was present in the dermis (Fig. 1 c, d). Immunohistochemical staining showed that lymphocytes were CD8⁺ lymphocytes with sparse Foxp3 positive lymphocytes in the upper dermis (Fig. 1 e, f).

Based upon the patient's clinical, laboratory, and pathological findings, DIHS/DRESS was suspected. Zonisamide was discontinued immediately and topical steroids were initiated. On the 11th day of hospitalisation, however, her dry cough was exacerbated. Laboratory tests revealed leucocytosis (11,800/μl)

with eosinophilia (3,800/μl) and atypical lymphocytosis. HHV6 IgG titre was increased from ×20 (at day 4) to ×120 (at day 17), confirming a reactivation of HHV6. Drug-induced lymphocyte stimulation test (DLST) for zonisamide was positive (a stimulation index of 338.2 %). Chest computed tomography (CT) showed multiple bilateral nodular lesions with surrounding ground-glass-opacity halo (Fig. 1g). Eosinophilic pneumonia (EP) due to zonisamide was suspected and systemic steroid therapy (0.5 mg/kg/day of prednisolone) was commenced. Peripheral eosinophils decreased and her pulmonary lesions improved after one week. Oral prednisolone was tapered and she was discharged on the 35th day of hospitalisation.

DISCUSSION

The diagnosis of DIHS/DRESS is based upon clinical and laboratory findings. The European Registry of Severe Cutaneous Adverse Reaction (RegiSCAR) study group has devised a scoring system (2). Our case was scored as “7” which is classified as a “definite” case (Table S1¹). Although, bronchoscopy was not successfully performed due to cardiopulmonary arrest during the procedure, the findings of high eosinophil counts and pneumonia developing 2 weeks after the onset of DRESS, along with the dramatic clinical response to glucocorticoids, strongly suggest that EP was a part of DRESS/DIHS rather than a separate adverse effect of zonisamide. Although pulmonary involvement is rarely reported, it may lead to life threatening adult respiratory distress syndrome (3, 4).

The pathogenesis of DIHS/DRESS remains unclarified, but reactivation of the herpes virus family has been reported at the onset of DIHS/DRESS (5). Tumour necrosis factor alpha (TNF-α) and interferon gamma (IFN-γ) secreted by the anti-EBV CD8⁺ T lymphocytes in cutaneous and visceral lesions may contribute to the development of DIHS/DRESS at the early stage (6). One study has demonstrated a switch in the predominant drug-specific proliferating T-cell population in the course of DIHS/DRESS; CD8⁺ lymphocytes were predominant initially, whereas CD4⁺ lymphocytes and regulatory T (Treg) cells (CD4⁺CD25⁺Foxp3⁺) proliferated at the recovery stage (7). In our case, immunohistochemical staining showed abundant CD8⁺ lymphocytes and few Treg cells infiltration in the upper dermis, reflecting the acute phase of DIHS/DRESS.

¹<https://doi.org/10.2340/00015555-1863>

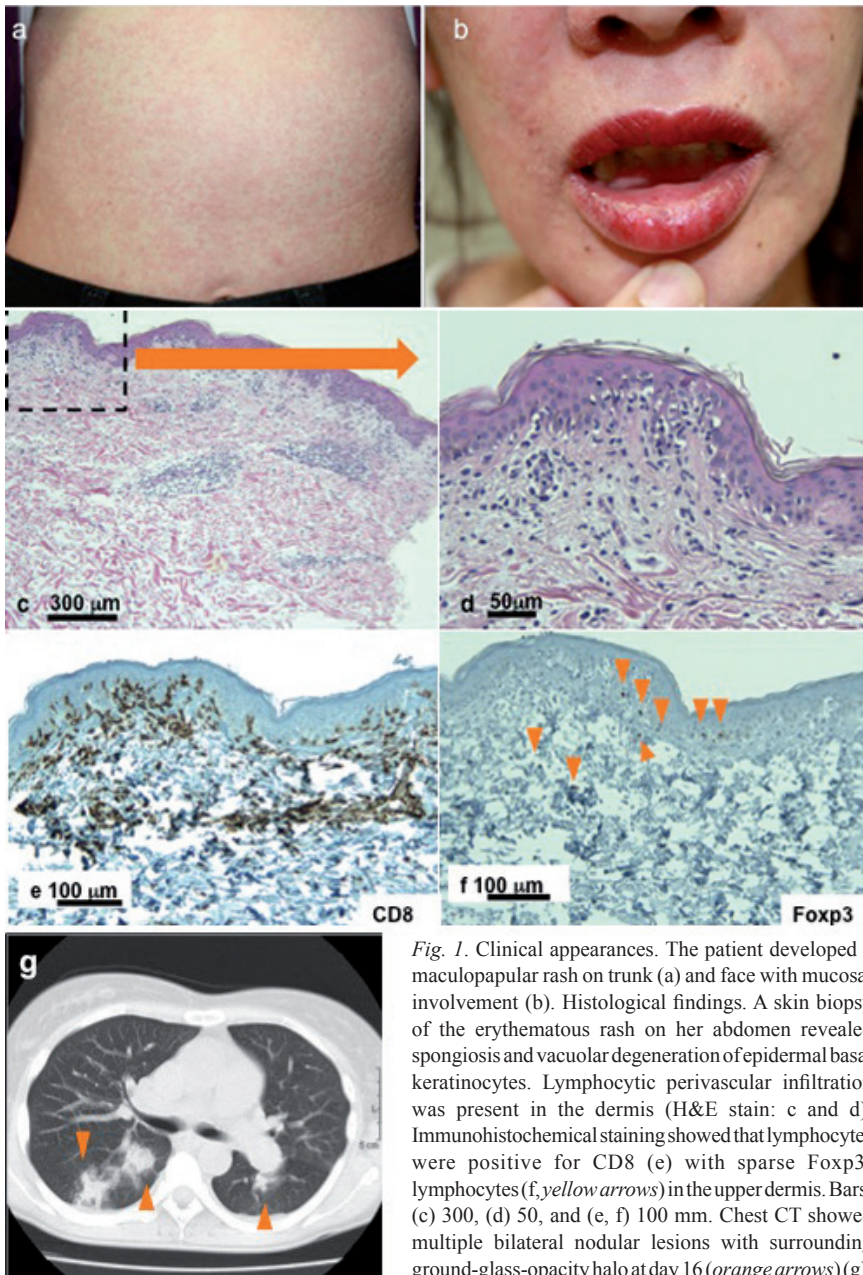


Fig. 1. Clinical appearances. The patient developed a maculopapular rash on trunk (a) and face with mucosal involvement (b). Histological findings. A skin biopsy of the erythematous rash on her abdomen revealed spongiosis and vacuolar degeneration of epidermal basal keratinocytes. Lymphocytic perivascular infiltration was present in the dermis (H&E stain: c and d). Immunohistochemical staining showed that lymphocytes were positive for CD8 (e) with sparse Foxp3⁺ lymphocytes (f, yellow arrows) in the upper dermis. Bars: (c) 300, (d) 50, and (e, f) 100 μ m. Chest CT showed multiple bilateral nodular lesions with surrounding ground-glass-opacity halo at day 16 (orange arrows) (g).

At present, we do not have clear evidence how EP was induced by zonisamide in DRESS/DIHS. Pulmonary involvement in DIHS/DRESS is known to be induced by a certain drug (3, 4). We consider that pulmonary involvement in DIHS/DRESS is not related to specific drugs only but may be related to the patient's underlying condition, such as HHT. Antigen-presenting cells (e.g. alveolar macrophages) are known to ingest drugs and present them to T helper cells to release interleukin-5, resulting in eosinophil proliferation (8). Therefore, in patients with HHT, blood vessels tend to be fragile and prone to bleeding (9), which may cause the accumulation of zonisamide into the lung and stimulate macrophages to initiate the immunologic cascade.

Clinicians should be aware of the possible involvement of the lung in the course of DIHS/DRESS.

ACKNOWLEDGEMENTS

This work was supported in part by "Research on Measures for Intractable Diseases" Project: matching fund subsidy from Ministry of Health and Welfare, Japan.

The authors declare no conflict of interest.

REFERENCES

- Romano A, Torres MJ, Castells M, Sanz ML, Blanca M. Diagnosis and management of drug hypersensitivity reactions. *J Allergy Clin Immunol* 2011; 127: 67–73.
- Kardaun SH, Sidoroff A, Valeyrie-Allanore L, Halevy S, Davidovici BB, Mockenhaupt M, et al. Variability in the clinical pattern of cutaneous side-effects of drugs with systemic symptoms: does a DRESS syndrome really exist? *Br J Dermatol* 2007; 156: 609–611.
- Kano Y, Ishida T, Hirahara K, Shiohara T. Visceral involvements and long-term sequelae in drug-induced hypersensitivity syndrome. *Med Clin North Am* 2010; 94: 743–759.
- Kosseifi SG, Guha B, Nassour DN, Chi DS, Krishnaswamy G. The Dapsone hypersensitivity syndrome revisited: A potentially fatal multisystem disorder with prominent hepatopulmonary manifestations. *J Occup Med Toxicol* 2006; 1: 9.
- Seishima M, Yamanaka S, Fujisawa T, Tohyama M, Hashimoto K. Reactivation of human herpesvirus (HHV) family members other than HHV-6 in drug-induced hypersensitivity syndrome. *Br J Dermatol* 2006; 155: 344–349.
- Picard D, Janela B, Descamp V, D'Incan M, Courville P, Jacquot S et al. Drug Reaction with eosinophilia and systemic symptoms (DRESS): A multiorgan antiviral T cell response. *Sci Transl Med* 2010; 46–62.
- Hanafusa T, Azukizawa H, Matsumura S, Katayama I. The predominant drug-specific T-cell population may switch from cytotoxic T cells to regulatory T cells during the course of anticonvulsant-induced hypersensitivity. *J Dermatol Sci* 2012; 65: 213–219.
- Nishio D, Izu K, Kabashima K, Tokura Y. T cell populations propagating in the peripheral blood of patients with drug eruptions. *J Dermatol Sci* 2007; 48: 25–33.
- Faughnan ME, Palda VA, Garcia-Tsao G, Geisthoff UW, McDonald J, Proctor DD, et al. International guidelines for the diagnosis and management of hereditary hemorrhagic telangiectasia. *J Med Genet* 2011; 48: 73–87.