

## CLINICAL REPORT

# Palmoplantar Keratoderma of the Gamborg-Nielsen Type is Caused by Mutations in the *SLURP1* Gene and Represents a Variant of Mal de Meleda

Linshu ZHAO<sup>1</sup>, Anders VAHLQUIST<sup>2\*</sup>, Marie VIRTANEN<sup>2</sup>, Lena WENNERSTRAND<sup>3</sup>, Lisbet K. LIND<sup>3</sup>, Anita LUNDSTRÖM<sup>4</sup> and Maritta HELLSTRÖM PIGG<sup>1</sup>

Departments of <sup>1</sup>Immunology, Genetics and Pathology and <sup>2</sup>Medical Sciences, Uppsala University, Uppsala, and <sup>3</sup>Departments of Medical Biosciences, Medical and Clinical Genetics and <sup>4</sup>Public Health and Clinical Medicine, Umeå University, Umeå, Sweden

**Palmoplantar keratoderma of the Gamborg-Nielsen type (PPK-GN) is a rare autosomal recessive skin disorder described in patients from Sweden. Mal de Meleda (MDM) is also a rare autosomal recessive inherited PPK first reported in 5 families from the island of Meleda. The 2 conditions phenotypically overlap and are characterised by palmoplantar erythematous hyperkeratotic plaques. The genetic background giving rise to PPK-GN has hitherto been unknown, whereas MDM is known to be caused by mutations in the gene encoding secreted Ly-6/uPAR-related protein 1, *SLURP-1*. In the present study we scrutinised individuals affected by PPK-GN for mutations in the *SLURP1* gene and identified 2 different mutations. Fourteen Swedish patients were homozygous for a previously described mutation, c.43T>C, while one individual was a compound heterozygote with one copy of a novel mutation, c.280T>A, in addition to one copy of the c.43T>C mutation. Hereby we confirm that PPK-GN is an allelic variant of MDM. Key words: *SLURP1*; mal de Meleda; palmoplantar keratoderma; Gamborg-Nielsen; missense mutation.**

Accepted Mar 5, 2014; Epub ahead of print Mar 7, 2014

Acta Derm Venereol 2014; 94: 707–710.

Maritta Hellström Pigg, Department of Immunology, Genetics and Pathology, Clinical Genetics, University Hospital, Uppsala University, SE-751 85 Uppsala, Sweden. E-mail: maritta.hellstrom.pigg@akademiska.se

Palmoplantar keratoderma of the Gamborg-Nielsen type (PPK-GN) or PPK of Norrbotten recessive type (OMIM 244850) was described as a diffuse PPK with autosomal recessive inheritance in patients from the northernmost county of Sweden by Gamborg Nielsen in 1985 (1). PPK-GN manifests with pronounced, often transgressive hyperkeratosis of palms and soles and an erythematous border next to the hyperkeratotic skin, tapered fingers are

also observed. Mal de Meleda (MDM; OMIM 248300) or keratosis palmoplantaris transgradiens of Siemens is an autosomal recessive skin disorder first described in 1898 by Neumann (2) in patients from the island of Mljet (Meleda) in Dalmatia, Croatia. MDM is clinically characterised by symmetric transgressive PPK, and sometimes associated with lichenoid or keratotic plaques over joints, redness in the palms and soles, brachydactyly, cone-shaped fingers, pseudoainhum and nail abnormalities with pachyonychia. The progressive lesions can lead to reduced mobility of hands and feet because of contractions (2–8).

PPK-GN shows a similar, but less severe phenotype than most often seen in MDM, i.e. milder hyperkeratosis and no nail dystrophies or lichenoid plaques and no pachydermia or distant keratosis except for knuckle pads in some affected individuals (9). Histological features of PPK-GN are prominent hyperkeratosis and a transit region with a broadened granular layer. However, morphologically this transformation delay is less pronounced in PPK-GN than in MDM. Ultrastructural analyses also showed differences between MDM and PPK-GN in the affected epidermis suggesting the 2 disorders are not identical (9).

Linkage of MDM to the distal long arm of chromosome 8 was found in 1998 (3) and in 2001 it was established that individuals affected by MDM were found to carry mutations in the *SLURP1* gene (10) that encodes secreted lymphocyte antigen 6/urokinase-type plasminogen activator receptor related protein-1.

A Dutch patient with a MDM phenotype but lacking mutations in the *SLURP1* gene was described in 2002 (11) and an individual with PPK of the Nagashima-type was also found to be devoid of mutations in the *SLURP1* gene in 2008 (12). The Nagashima-type of keratoderma is characterised by a transgressive and non-progressive PPK inherited in an autosomal recessive manner but with a milder phenotype than seen in classical MDM (12).

The aim of this study was to investigate if 15 Swedish patients affected by PPK-GN carry mutations in the *SLURP1* gene.

\*The Editor-in-Chief has not had responsibility for this article; it has been handled fully by the Co-Editor, who made the decision to accept it.

## METHODS

### Patients and material

Fifteen individuals with PPK from 9 families were included in this study, 14 were born in Norrbotten or Västerbotten, the 2 northernmost counties of Sweden, and one person was born in the south of Sweden. The presentation of PPK was very similar in all affected individuals and no keratoderma was present in any of the parents. These observations fitted an autosomal recessive mode of inheritance that was verified by the observation of identical homozygous haplotypes in the 8qter region in affected individuals from 7 of the families (data not shown). Clinical and ultrastructural characteristics of the patients from the northernmost county of Sweden were previously described by Kastl et al. in 1990 (9).

Venous blood samples were obtained from the patients, their siblings and parents.

This study was approved by the ethics committees of Uppsala and Umeå University. Informed consent was obtained from all individuals involved.

### Mutation screening and sequence alignments

Genomic DNA was extracted from peripheral blood using standard procedures. PCR primers to amplify the coding regions and flanking exon-intron sequences of *SLURP1* (NM\_020427.2) were designed by the use of Primer3 (13). PCR products were purified using EXOSAPIT (Fermentas, ThermoFisher). Bidirectional sequencing was performed using ABI Prism Big Dye termination V3.1 cycle sequencing kit and an ABI3130XL machine (Applied Biosystems). Sequences were analysed with SeqScape V.2.5 (Applied Biosystems). Exon 3 of *SLURP1* was sequenced in 50 control samples (100 chromosomes) to evaluate the novel mutation found.

Multiple sequence alignments of the SLURP-1 protein were performed using the alignment programme ClustalW2 (European Bioinformatics Institute) and the Alamut software 2.0 (Interactive Biosoftware, France).

## RESULTS

### Mutation analyses and clinical characteristics

Fourteen of the 15 individuals affected by PPK-GN were homozygous for a previously described mutation in exon 1 of *SLURP1*, c.43T>C, that results in a change of tryptophan to arginine, p.Trp15Arg (14). The parents of the affected individuals were all heterozygous carriers of this mutation (data not shown). The 14 affected individuals showed a marked, sharply demarcated, and waxy, usually yellowish PPK. Hyperkeratosis was also present on the back of fingers and toes, especially distally and around the joints. The hyperkeratosis was surrounded by erythema and patches of thinner erythematous skin were often interspersed in the hyperkeratotic skin. Fingers were often tapered towards the tips and occasionally constricting bands were present on the fingers. Maceration between toes was frequent and in some cases interdigital maceration was also observed. Complaints of painful fissures and foul-smelling hyperhidrosis among the patients were common. Most affected individuals had on-going or past histories of

complicating fungal infections. Generally, the initial manifestation of PPK appeared during the first year of life, the skin changes then progressed until adulthood, sometimes with continuing progression during adult life but rare occasions of regression were also noted (Fig. 1).

In one of the 15 investigated patients, a novel missense mutation, c.280 T>A in exon 3 of *SLURP1* (Fig. S1<sup>1</sup>) was found in one allele. This transversion causes a change of the amino acid cysteine in position 94 to serine, p.Cys94Ser. None of the 100 control alleles sequenced harboured the C.280T>A mutation. The other *SLURP1* allele in the patient with the novel mutation carried the same recurrent missense mutation as the other patients, c.43T>C (Fig. S1<sup>1</sup>). One parent of the patient was shown to carry the mutation c.280T>A (Fig. S1<sup>1</sup>) and the other parent the c.43T>C mutation (Fig. S1<sup>1</sup>). The patient is a 2-year-old boy, the only child of unrelated parents from the southern part of Sweden with no family history of skin disease. The boy was born at term after an uneventful pregnancy. Dry palms and soles were noted at birth, and at 4 months definite thickness, scaling and redness had developed and progressed. When immersed in water the skin became "spongy" and whitish. Pruritus often developed at night-time but there were no blisters and no skin lesions were observed elsewhere. He was referred to the Genodermatosis Clinic of Uppsala University Hospital under the diagnosis of epidermolysis bullosa simplex or keratoderma. He showed massive keratoderma, hyperhidrosis and focal peeling, but no blisters (Fig. 2) and had no specific treatment. A tentative diagnosis of recessive PPK-GN or epidermolytic keratoderma was made, but analysis of

<sup>1</sup><http://www.medicaljournals.se/acta/content/?doi=10.2340/00015555-1840>

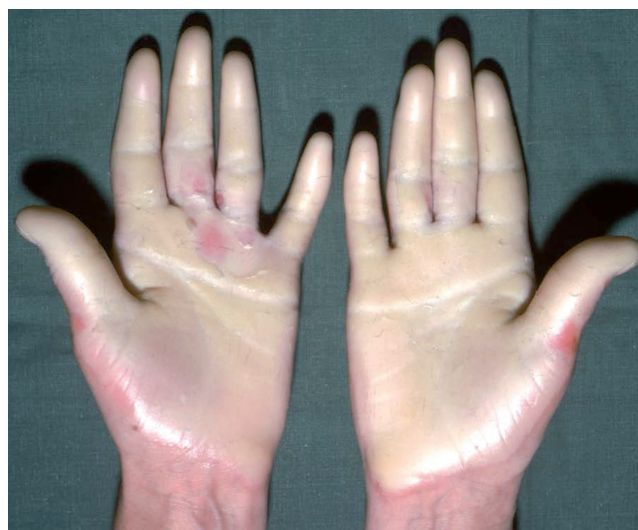

Fig. 1. The palms of a 43-year-old woman with palmoplantar keratoderma of the Gamburg-Nielsen type homozygous for the recurrent c.43T>C mutation in the *SLURP1* gene. The picture shows a marked, sharply demarcated palmar keratoderma with a waxy appearance.

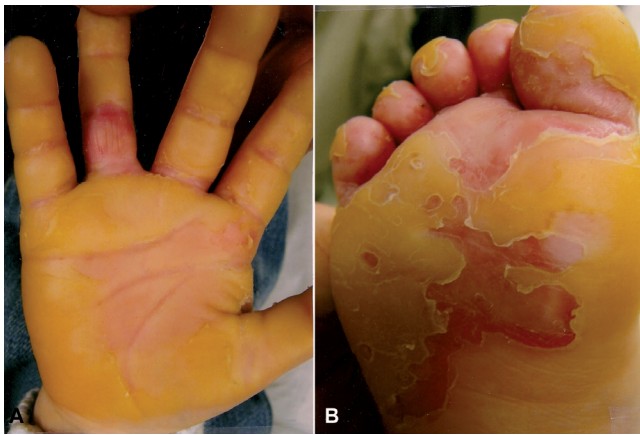


Fig. 2. Palm (A) and sole (B) in the 2-year-old boy with the compound heterozygous missense mutations c.43T>C and c.280T>A, showing massive keratoderma and focal peeling possibly associated with bacterial superinfection.

the *KRT9* gene did not reveal any mutation and thereby excluded the latter diagnosis.

#### Sequence alignments

Multiple sequence alignment of the SLURP-1 protein was performed in order to estimate inter-species conservation of certain segments and to identify regions shared by other members of the Ly-6/uPAR family of proteins. The members of the uPAR family of proteins were not identical excluding the conserved cysteines that participate in disulphide bonds. Alignment of the human SLURP-1 sequence to other members of the Ly-6/uPAR protein family (hPSCA, hCD59, hE48 and huPAR) showed that the amino acid corresponding to the position of the novel p.Cys94Ser alteration is conserved in the vast majority of proteins (data not shown). Alignment of the human SLURP-1 sequence to 10 other species (Chimp., Macaque, Rat, Mouse, Dog, Cat, Cow, Opossum, Chicken and Tetraodon) also showed conservation of the cysteine corresponding to position 94 in the human SLURP-1 (data not shown).

## DISCUSSION

SLURP-1 protein is involved in keratinocyte differentiation (15) and alterations of the protein can disturb normal skin development as has been found in patients with MDM (8, 10, 14, 16–22). The SLURP-1 protein is encoded by the 3 exons of the *SLURP1* gene (previously *ARS*) and contains a signal peptide as well as conserved cysteines important in forming disulphide bonds that are critical for the function of the protein. Human SLURP-1 is a member of the large Ly-6/uPAR protein superfamily; proteins that contain 8–10 highly conserved cysteines that form disulphide bonds.

In this study we have genotyped 15 Swedish individuals from families with autosomal recessive PPK-GN.

Fourteen persons were found to be homozygous for a c.43T>C (p.Trp15Arg) mutation in the *SLURP1* gene and as expected all parents of the affected individuals were heterozygous carriers. Since 13 affected individuals from 7 families originating from the 2 northernmost counties of Sweden have been found to carry identical homozygous haplotypes around the *SLURP1* gene loci on chromosome 8qter (data not shown) a common founder for the mutation in this population is very probable. The c.43T>C mutation has been described previously in several different populations (8, 14, 16). The T to C transition introduces a positively charged arginine residue into the conserved non-polar signal sequence and the altered protein is predicted to have a shortened signal sequence and a weaker cleavage site at position 18 (14).

One of the 15 persons affected by PPK-GN was found to have compound heterozygous mutations in the *SLURP1* gene, a novel c.280T>A mutation (p.Cys94Ser) in addition to the recurrent c.43T>C mutation; c.280T>A was not detected in 100 control alleles strengthening the assumption that this is a mutation causing disease and not a polymorphism. Moreover this mutation affects one of the conserved cysteine residues in the SLURP-1 protein that are essential in forming disulphide bridges within the protein, bridges that are critical for normal function of the protein.

So far, 16 distinct *SLURP1* gene mutations have been reported in MDM (Table I). The PPK-GN patients in our study appears to have a milder phenotype than described in classical MDM and the mutations found are not identical with those described in the families from the Mljet island by Fischer et al. 2001 (10). However, our findings confirm that mutations in the *SLURP1* gene are responsible also for the milder type of autosomal recessive PPK encountered in Sweden, and that PPK-GN and MDM indeed are allelic disorders.

Table I. Mutations in the *SLURP1* gene known to cause Mal de Meleda or palmoplantar keratoderma of the Gamborg-Nielsen type

Mutation	Consequence of mutation	Reference
c.1A>C	p.Met1Leu	Eckl et al. 2003 (14)
c.43T>C	p.Trp15Arg	Eckl et al. 2003 (14)
IVS1 ds G-A +1	Altered splice site	Wajid et al. 2009 (19)
c.82delT	p.Cys28fs32Term	Fischer et al. 2001 (10)
c.129C>A	p.Cys43Term	Musulmanoglu et al. 2006 (20)
c.212G>A	p.Arg71His	Favre et al. 2007. (17)
c.212G>C	p.Arg71Pro	Nellen et al. 2009 (8)
IVS2 ds G-A +1	Altered splice site	Fischer et al. 2001 (10)
c.229T>C	p.Cys77Arg	Charfeddine et al. 2003 (18)
c.244C>T	p.Pro82Ser	Gruber et al. 2011 (21)
c.256G>A	p.Gly86Arg	Eckl et al. 2003 (14)
c.256G>C	p.Gly86Arg	Eckl et al. 2003 (14)
c.280T>A	p.Cys94Ser	Present study
c.286C>T	p.Arg96Term	Fischer et al. 2001 (10)
c.293T>C	p.Leu98Pro	Yerebakan et al. 2003 (22)
c.296G>A	p.Cys99Tyr	Marrakchi et al. 2003 (16)

## ACKNOWLEDGEMENTS

The authors thank the patients and their relatives for participating in this study. We thank Povl Gamborg Nielsen for generous sharing of patient data. We also thank Sara Ekvall and Marie-Louise Bondeson for technical support. This study was supported by grants from the Faculty of Medicine, Umeå University, Uppsala University Hospital, the Magn. Bergvall's Foundation, the Joint Committee of County Councils of Northern Sweden and the Welander Finsen Foundation.

## REFERENCES

- Gamborg Nielsen P. Two different clinical and genetic forms of hereditary palmoplantar keratoderma in the northernmost county of Sweden. *Clin Genet* 1985; 28: 361–366.
- Neumann I. Ueber Keratoma Hereditarium. *Arch Derm Syphilol* 1898; 42: 163–174.
- Fischer J, Bouadjar B, Heilig R, Fizames C, Prud'homme JF, Weissenbach J. Genetic linkage of Meleda disease to chromosome 8qter. *Eur J Hum Genet* 1998; 6: 542–547.
- Bouadjar B, Benmazouzia S, Prud'homme JF, Cure S, Fischer J. Clinical and genetic studies of 3 large, consanguineous, Algerian families with Mal de Meleda. *Arch Dermatol* 2000; 136: 1247–1252.
- Patel H, Nardelli M, Fenn T, Houlston R, Coonar A, Patton MA, Crosby AH. Homozygosity at chromosome 8qter in individuals affected by mal de Meleda (Meleda disease) originating from the island of Meleda. *Br J Dermatol* 2001; 144: 731–734.
- Bakija-Konsuo A, Basta-Juzbasic A, Rudan I, Situm M, Nardelli-Kovacic M, Levanat S, et al. Mal de Meleda: genetic haplotype analysis and clinicopathological findings in cases originating from the island of Mljet (Meleda), Croatia. *Dermatology* 2002; 205: 32–39.
- Chao SC, Huang CY, Lai FJ, Yang MH. Pseudodominant inheritance with the G86R mutation in the ARS gene in Mal de Meleda. *Int J Dermatol* 2006; 45: 1456–1458.
- Nellen RG, van Geel M, Steijlen PM, van Steensel MA. Compound heterozygosity for ARS component B mutations in a Dutch patient with mal de Meleda. *Br J Dermatol* 2009; 160: 878–880.
- Kastl I, Anton-Lamprecht I, Gamborg Nielsen P. Hereditary palmoplantar keratosis of the Gamborg Nielsen type. Clinical and ultrastructural characteristics of a new type of autosomal recessive palmoplantar keratosis. *Arch Dermatol Res* 1990; 282: 363–370.
- Fischer J, Bouadjar B, Heilig R, Huber M, Lefèvre C, Jobard F, et al. Mutations in the gene encoding SLURP-1 in Mal de Meleda. *Hum Mol Genet* 2001; 10: 875–880.
- van Steensel MA, van Geel MV, Steijlen PM. Mal de Meleda without mutations in the ARS coding sequence. *Eur J Dermatol* 2002; 12: 129–132.
- Kabashima K, Sakabe JI, Yamada Y, Tokura Y. “Nagashima-Type” keratosis as a novel entity in the palmoplantar keratoderma category. *Arch Dermatol* 2008; 144: 375–379.
- Rozen S, Skaletsky H. Primer3 on the WWW for general users and for biologist programmers. *Methods Mol Biol* 2000; 132: 365–386.
- Eckl KM, Stevens HP, Lestringant GG, Westenberger-Treumann M, Traupe H, Hinz B, et al. Mal de Meleda (MDM) caused by mutations in the gene for SLURP-1 in patients from Germany, Turkey, Palestine, and the United Arab Emirates. *Hum Genet* 2003; 112: 50–56.
- Mastrangeli R, Donini S, Kelton CA, He C, Bressan A, Milazzo F, et al. ARS Component B: structural characterization, tissue expression and regulation of the gene and protein (SLURP-1) associated with Mal de Meleda. *Eur J Dermatol* 2003; 13: 560–570.
- Marrakchi S, Audebert S, Bouadjar B, Has C, Lefèvre C, Munro C, et al. Novel mutations in the gene encoding secreted lymphocyte antigen-6/urokinase-type plasminogen activator receptor-related protein-1 (SLURP-1) and description of five ancestral haplotypes in patients with Mal de Meleda. *J Invest Dermatol* 2003; 120: 351–355.
- Favre B, Plantard L, Aeschbach L, Brakch N, Christen-Zaech S, de Viragh PA, et al. SLURP1 is a late marker of epidermal differentiation and is absent in Mal de Meleda. *J Invest Dermatol* 2007; 127: 301–308.
- Charfeddine C, Mokni M, Ben Mousli R, Elkares R, Bouchlaka C, Boubaker S, et al. A novel missense mutation in the gene encoding SLURP-1 in patients with Mal de Meleda from northern Tunisia. *Br J Dermatol* 2003; 149: 1108–1115.
- Wajid M, Kurban M, Shimomura Y, Christiano AM. Mutations in the SLURP-1 gene underlie Mal de Meleda in three Pakistani families. *J Dermatol Sci* 2009; 56: 27–32.
- Musulmanoglu MH, Saracoglu N, Cilingir O, Basmaci T, Urer S, Sabuncu I, et al. A novel mutation in the ARS (component B) gene encoding SLURP-1 in a Turkish family with mal de Meleda. *Br J Dermatol* 2006; 155: 467–469.
- Gruber R, Hennies HC, Romani N, Schmuth M. A novel homozygous missense mutation in SLURP1 causing Mal de Meleda with an atypical phenotype. *Arch Dermatol* 2011; 147: 748–750.
- Yerebakan O, Hu G, Yilmaz E, Celebi JT. A novel mutation in the ARS (component B) gene encoding SLURP-1 in a family with Mal de Meleda. *Clin Exp Dermatol* 2003; 28: 542–544.