

QUIZ SECTION

Arc-shaped Plaque on the Forehead: A Quiz

Yukari Kawakami, Makoto Kunisada*, and Chikako Nishigori

Division of Dermatology, Department of Internal Related, Kobe University Graduate School of Medicine, Kobe 650-0017, Japan. *E-mail: kunisada@med.kobe-u.ac.jp

A 20-year-old woman presented with a 2-year history of a plaque growing in a centrifugal manner on the left side of her forehead (Fig. 1a). The initial lesion developed at the centre of her left eyebrow, which resulted in slight hair loss. Topical glucocorticoids caused no improvement. The plaque was asymptomatic and she was otherwise healthy and revealed no history of photosensitivity or smoking habit. Serological analysis of autoantibodies, including

anti-SSA/Ro and anti-SSB/La antibodies together with ophthalmological and otological examinations were unremarkable. Microbiological examinations of the skin yielded negative results. A skin biopsy specimen was obtained with haematoxylin and eosin (Fig. 1 b–d). A positive staining of Alcian blue in the interstitial components in the dermis was demonstrated (not shown).

What is your diagnosis? See next page for answer.

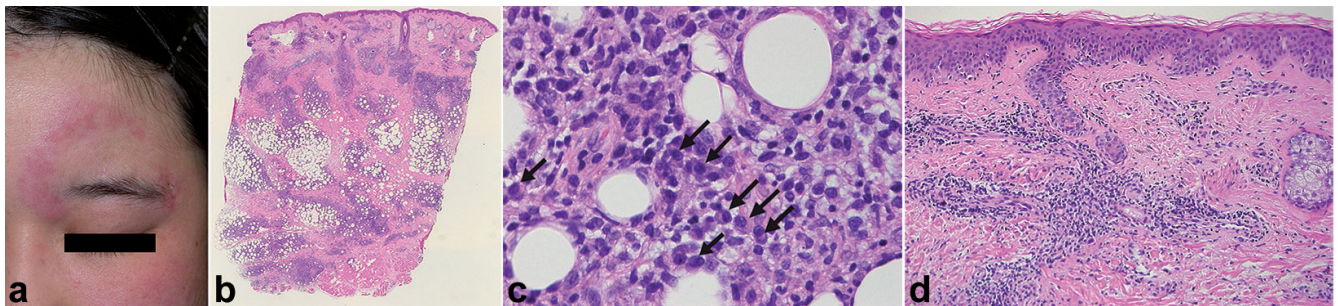


Fig. 1. A hard arc-shaped erythematous plaque on the left side of her forehead (a). Histopathologically, extensively degenerated adipose tissue accompanied by fibrotic changes (b). Dense infiltrative mixture of plasma and mononuclear cells in the degenerated adipose tissue (c). Perivascular lymphocytic infiltration in the dermis and no remarkable change in the dermoepidermal junction (d). Arrows; plasma cells are indicated.

ANSWERS TO QUIZ

Arc-shaped Plaque on the Forehead: A Commentary

Acta Derm Venereol 2014; 747–749.

Diagnosis: Lupus erythematosus profundus

Lupus erythematosus profundus (LEP) was first described as a distinct entity of cutaneous lupus erythematosus (LE), and is characterised by the development of erythematous deep nodules and plaques predominantly on the face and upper and lower extremities (1). LEP occurs in approximately 3% of all patients with LE (2). Histologically, adipose tissue is severely affected with dense lymphocytic infiltration that usually includes abundant plasma cells, revealing intensive lobular panniculitis. Mucin accumulations are usually observed in interstitial dermal spaces stained with Alcian blue. IgM and C3 are deposited in the basement membrane of the epidermis and the perivascular or perifollicular component in the dermis during the active stage, which can be identified via a direct immunofluorescence (IF) study. The configuration of LEP eruptions usually shows a plaque with an ill-defined border and very rarely exhibits an arc-shaped pattern. Tsuzaka et al. (3) reviewed LEP with an arc- or annular-shaped pattern and reported that only 2 arc-shaped cases were identified in the literature since 1983. In both cases, the plaques were distributed on the scalp or forehead after a 2-year duration from clinical onset and shared histological features of lymphocytic panniculitis, dermal mucin accumulation, and immunoglobulin deposition in the basement membrane (4). The mechanism specific to arc-shaped LEP development is unknown, although the linear-shaped LEP often follows Blaschko's lines (5, 6). The differential diagnoses of arc-shaped LEP are annular erythema associated with lupus erythematosus tumidus (LET), Sjögren's syndrome, Jessner's lymphocytic infiltration of the skin, erythema nodosum, erythema induratum, and subcutaneous panniculitic-like T-cell lymphoma. The combination of histopathological features, serological study including anti-SSA and SSB antibody titres, and genetic analysis for T-cell receptor rearrangement is necessary for the diagnosis of LEP. The most probable differential diagnosis of LEP is LET, which is characterised by erythematous, succulent and non-scarring plaques with smooth surface in sun-exposed areas, frequently concomitant with photosensitivity. LET shares histological findings with LEP,

showing perivascular and periadnexal lymphocytic infiltration with interstitial mucin deposit. Direct IF study of LET usually turns out negative (7). In our patient, direct IF study showed immunoglobulin M (IgM) and C3 depositions in the basement membrane, perivascular, and perifollicular sites but not in the abdominal skin (lupus band test). Infiltrative cells revealed no atypia and genetic analysis of the skin sample demonstrated no T-cell receptor rearrangement. The treatment of LEP, particularly in cases with arc- and linear-shaped configurations, reportedly include topical glucocorticoids, intralesional glucocorticoids injections, oral hydroxychloroquine, and oral prednisolone (2). LEP usually leaves a disfiguring scar due to atrophy of the adipose tissue in cases where treatment is not provided for a long duration; however, in certain cases, this disfiguring scar is noted irrespective of whether prompt diagnosis and treatment are provided. Although oral hydroxychloroquine is generally beneficial treatment for LEP, it is not covered by insurance in Japan. Prednisolone (20 mg/day) therapy was initiated with tapering for 5 months, and the plaque disappeared without any scarring or depression. The prednisolone treatment was discontinued and the plaque has not reoccurred.

REFERENCES

1. Irang S. Lupus erythematosus profundus. Arch Dermatol Syphilol 1940; 42: 97–102.
2. Tuffanelli DL. Lupus erythematosus panniculitis (profundus). Arch Dermatol 1971; 103: 231–242.
3. Tsuzaka S, Ishiguro N, Akashi R, Kawashima M. A case of lupus erythematosus profundus with multiple arc-shaped erythematous plaques on the scalp and a review of the literature. Lupus 2012; 21: 662–665.
4. Bacanlı A, Uzun S, Ciftcioglu MA, Alpsoy E. A case of lupus erythematosus profundus with unusual manifestations. Lupus 2005; 14: 403–405.
5. Green JJ, Baker DJ. Linear childhood discoid lupus erythematosus following the lines of Blaschko: a case report with review of the linear manifestations of lupus erythematosus. Pediatr Dermatol 1999; 16: 128–133.
6. Nagai Y, Ishikawa O, Hattori T, Ogawa T. Linear lupus erythematosus profundus on the scalp following the lines of Blaschko. Eur J Dermatol 2003; 13: 294–296.
7. Kuhn A, Richter-Hintz D, Oslislo C, Ruzicka T, Megahed M, Lehmann P. Lupus erythematosus tumidus. Arch Dermatol 2000; 136: 1033–1041.