

SHORT COMMUNICATION

IgA/IgG Pemphigus with Infiltration of Neutrophils and Eosinophils in an Ulcerative Colitis Patient

Ryuhei Uchiyama¹, Norito Ishii², Fuyuko Arakura³, Yukiko Kiniwa¹, Koh Nakazawa⁴, Hisashi Uhara¹, Takashi Hashimoto² and Ryuhei Okuyama¹

Departments of Dermatology, ¹Shinshu University School of Medicine, 3-1-1 Asahi, Matsumoto, Nagano 390-8621 and ²Kurume University School of Medicine, and Kurume University Institute of Cutaneous Cell Biology, Fukuoka ³Division of Dermatology, NHO Matsumoto Medical Center, and ⁴Division of Pathology, Matsumoto Medical Center, Matsumoto, Nagano, Japan. E-mail: rokyama@shinshu-u.ac.jp

Accepted Mar 3, 2014; Epub ahead of print Mar 7, 2014

Pemphigus is an intraepidermal blistering disease characterised by autoantibodies (mainly IgG class) to desmosomes. While autoantibodies usually target desmoglein 1 (Dsg1) and/or Dsg3, some patients have antibodies to other molecules, including desmocollins (Dscs) (1–3). Here, we report a case of IgA/IgG pemphigus with infiltration of neutrophils and eosinophils which developed in an ulcerative colitis (UC) patient. Various serological tests showed clear IgA reactivity with Dsc1, as well as weak IgA/IgG reactivity with Dsc2/3 and weak IgG reactivity with Dsc1, Dsg1/3 and BP180.

CASE REPORT

A 78-year-old Japanese woman, treated with mesalazine for UC, was complaining of muco-cutaneous lesions that had persisted for several weeks. Physical examination revealed punctate erythemas on the lower extremities and erosive lesions on the oral, vulval, and perianal mucosae. Various laboratory tests yielded normal findings, except for antinuclear antibodies with homogenous and speckled pattern (1:160; ref < 1:40). Malignancy surveys, including whole-body CT and soluble IL-2 receptor, revealed no abnormalities.

First skin biopsy taken from the erythema showed intraepidermal vesicular dermatitis with neutrophilic infiltration. Direct immunofluorescence (IF) revealed weak IgG and IgA deposits to the keratinocyte cell surface, as well as C3 deposit on the cell surface and the epidermal basement membrane zone (BMZ).

IgG enzyme-linked immunosorbent assays (ELISAs) revealed positive results for BP180, but not for Dsg1 or Dsg3. IgA ELISAs (4) revealed negative results for Dsg1 and Dsg3. Furthermore, we performed newly developed ELISAs for Dsc1–Dsc3 (Ishii et al., submitted). IgG ELISAs indicated slightly positive results for all Dsc1, Dsc2, and Dsc3. IgA ELISAs showed high reactivity with Dsc1, weak reactivity with Dsc2 and negative reactivity with Dsc3. The immunological study results are summarised in Table I.

Treatment with oral prednisolone at 1 mg/kg/day improved the erosive lesions. Prednisolone dose was then tapered to 0.125 mg/kg/day. Four months later, concomitant with relapse of oral, anal and vulval mucosal lesions, blistering skin lesions developed on the abdomen and buttock (Fig. 1a).

Second skin biopsy obtained from a blister on the abdomen revealed acantholytic intraepidermal blisters with mixed infiltration of neutrophils and eosinophils (Fig. 1b). Direct IF

showed deposits of IgA (Fig. 1c) and IgG (Fig. 1d) on the cell surfaces, and C3 deposit on the cell surfaces and BMZ.

Indirect IF of normal human skin, 1M NaCl-split human skin and monkey oesophagus revealed no positive staining. Immunoblotting using EDTA-separated normal human epidermal and dermal extracts, recombinant proteins of BP180 NC16a and C-terminal domains, and concentrated HaCaT cell culture supernatant (5) showed no positive reactivity.

IgG ELISAs indicated slightly positive reactivity with all Dsg1, Dsg3, BP180, Dsc1, Dsc2, and Dsc3. IgA ELISAs indicated strongly positive reactivity with Dsc1, slightly positive reactivity with Dsc2 and Dsc3, but no reactivity with Dsg1 and Dsg3.

Furthermore, we performed indirect IF of Dsc-transfected COS-7 cells, as described previously (6). IgA autoantibodies from the patient's serum reacted slightly with COS-7 cells transfected with Dsc1, but not with Dsc2 or Dsc3.

Prednisolone at 1 mg/kg/day resulted in complete clearance of cutaneous lesions. Prednisolone was tapered to 0.375 mg/kg/day without any recurrence of skin lesions during one year.

DISCUSSION

Based on the cell surface deposition of IgA and IgG in direct IF, we made a diagnosis of IgA/IgG pemphigus. Our patient had a high titre of IgA anti-Dsc1 antibodies with low titres of other autoantibodies. IgA pemphigus is subdivided into subcorneal pustular dermatosis (SPD) type, the target antigen of which is Dsc1, and intraepidermal neutrophilic IgA dermatosis (IEN)-type, the target antigen of which is unknown (7). As Dsc1 is strongly expressed in the superficial epidermis, SPD-type IgA pemphigus shows acantholysis/pustules and IgA deposit in the upper epidermis.

Despite the high titre of IgA antibodies to Dsc1, our patient showed IgA deposit in the entire epidermis and acantholysis in the lower epidermis. Furthermore, unlike SPD-type IgA pemphigus, our patient showed various mucosal lesions. Dsc1 is expressed specifically in the epidermis, while Dsc2/3 and Dsg3 are present in both epidermis and mucosal epithelia (8). Therefore, the acantholytic blisters in the lower epidermis and mucosal lesions of our patient are considered to be caused by antibodies to other Dscs or Dsgs. In addition, intraepidermal neutrophilic infiltration is

Table I. The findings of IgG and IgA enzyme-linked immunosorbent assay (ELISA) in our patient. *positive values

	IgG					IgA					
	Dsg1 (Index) (<14)	Dsg3 (Index) (<7)	BP180 (Index) (<9)	Dsc1 optical density (OD) (<0.200)	Dsc2 (OD) (<0.070)	Dsc3 (OD) (<0.120)	Dsg1 (OD) (<0.150)	Dsg3 (OD) (<0.150)	Dsc1 (OD) (<0.091)	Dsc2 (OD) (<0.020)	Dsc3 (OD) (<0.026)
1 st biopsy	4.42	2.56	26.08*	0.224*	0.230*	0.217*	0.018	0.017	1.259*	0.026*	0.018
2 nd biopsy	14.60*	15.14*	22.06*	0.299*	0.279*	0.347*	0.030	0.039	1.431*	0.046*	0.040*

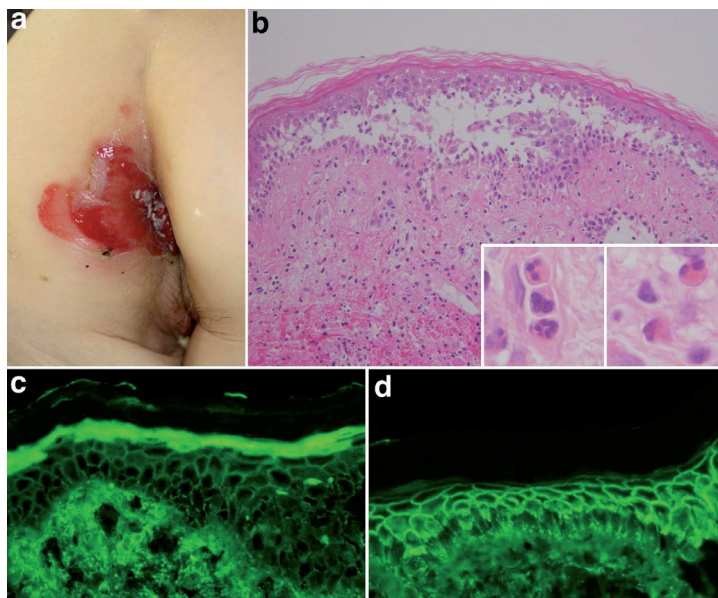


Fig. 1. Clinical and histopathological features. (a) Well-demarcated erosion on the buttock and perianal region. (b) Histopathological features of lesional skin biopsy from the abdomen. Insets: Infiltration of neutrophils and eosinophils (haematoxylin-eosin staining. Original magnification $\times 100$ [main panel] and $\times 400$ [insets]). (c,d) Direct immunofluorescence for IgA (c) and IgG (d) (original magnification $\times 200$).

a characteristic histopathological feature in IgA pemphigus (7). Therefore, massive neutrophilic infiltration seen in our patient was induced probably by IgA autoantibodies.

Indirect IF using human skin and monkey oesophagus did not detect autoantibodies in our patient, suggesting that indirect IF is less sensitive than direct IF and ELISA. In addition, indirect IF of monkey oesophagus may not be suitable for detection of anti-Dsc1 antibodies, because oesophagus expresses undetectable levels of Dsc1 (8).

Simultaneous occurrence of anti-cell-surface and anti-BMZ antibodies, as well as various mucosal lesions, suggested paraneoplastic pemphigus (9). However, no malignancy was found either by initial extensive screenings or by subsequent follow-up studies. The oral mucosal lesion in our patient was relatively mild and responded well to low dose of prednisolone. Furthermore, immunoblotting of epidermal extracts did not show dual reactivity with envoplakin and periplakin, diagnostic hallmark of paraneoplastic pemphigus. These features excluded the possibility of paraneoplastic pemphigus.

In some IgA pemphigus patients, multiple target antigens have been identified (10–12). Multiple autoantibodies in our patient might be produced via epitope spreading phenomenon. In this concept, an inflammatory event exposes new target antigens to the immune system, and then induces subsequent autoimmunity to new related antigens (13).

A few pemphigus patients were reported to be associated with UC (11, 14), and one patient showed IgA autoantibodies to several antigens (11). Mucosal immune response is IgA predominant. In addition, the colonic epithelium expresses Dsg1/3, BP180 and Dsc1/2, but not Dsc3 (<http://www.proteinatlas.org/>). Therefore, it is speculated that colonic

inflammation exposed these epidermal autoantigens to IgA mucosal immune system, leading to the development of IgA antibodies in genetically susceptible individuals. Careful screening for autoreactivity to multiple antigens should be considered in patients with autoimmune bullous diseases associated with UC.

The authors declare no conflict of interest.

REFERENCES

- Hisamatsu Y, Amagai M, Garrod DR, Kanzaki T, Hashimoto T. The detection of IgG and IgA autoantibodies to desmocollins 1–3 by enzyme-linked immunosorbent assays using baculovirus-expressed proteins, in atypical pemphigus but not in typical pemphigus. *Br J Dermatol* 2004; 151: 73–83.
- Mao X, Nagler AR, Farber SA, Choi EJ, Jackson LH, Leiferman KM, et al. Autoimmunity to desmocollin 3 in pemphigus vulgaris. *Am J Pathol* 2010; 177: 2724–2730.
- Zaraa I, Kerkeni N, Sellami M, Chelly I, Zitouna M, Makni S, et al. IgG/IgA pemphigus with IgG and IgA antidesmoglein 3 antibodies and IgA antidesmoglein 1 antibodies detected by enzyme-linked immunosorbent assay: a case report and review of the literature. *Int J Dermatol* 2010; 49: 298–302.
- Oiso N, Yamashita C, Yoshioka K, Amagai M, Komai A, Nagata Y, et al. IgG/IgA pemphigus with IgG and IgA antidesmoglein 1 antibodies detected by enzyme-linked immunosorbent assay. *Br J Dermatol* 2002; 147: 1012–1017.
- Hashimoto T, Kiyokawa C, Mori O, Miyasato M, Chidgey MA, Garrod DR, et al. Human desmocollin 1 (Dsc1) is an autoantigen for the subcorneal pustular dermatosis type of IgA pemphigus. *J Invest Dermatol* 1997; 109: 127–131.
- Hashimoto T, Amagai M, Watanabe K, Chorzelski TP, Bhogal BS, Black MM, et al. Characterization of paraneoplastic pemphigus autoantigens by immunoblot analysis. *J Invest Dermatol* 1995; 104: 829–834.
- Tsuruta D, Ishii N, Hamada T, Ohyama B, Fukuda S, Koga H, et al. IgA pemphigus. *Clin Dermatol* 2011; 29: 437–442.
- King IA, Sullivan KH, Bennett R, Jr., Buxton RS. The desmocollins of human foreskin epidermis: identification and chromosomal assignment of a third gene and expression patterns of the three isoforms. *J Invest Dermatol* 1995; 105: 314–321.
- Anhalt GJ, Kim SC, Stanley JR, Korman NJ, Jabs DA, Kory M, et al. Paraneoplastic pemphigus. An autoimmune mucocutaneous disease associated with neoplasia. *N Engl J Med* 1990; 323: 1729–1735.
- Duker I, Schaller J, Rose C, Zillikens D, Hashimoto T, Kunze J. Subcorneal pustular dermatosis-type IgA pemphigus with autoantibodies to desmocollins 1, 2, and 3. *Arch Dermatol* 2009; 145: 1159–1162.
- Kern JS, Gehring W, Kreisel W, Hertl M, Technau-Hafsi K, Bruckner-Tuderman L, et al. Overlap of IgA pemphigus and linear IgA dermatosis in a patient with ulcerative colitis: A mere coincidence? *Acta Derm Venereol* 2014; 94: 228–230.
- Muller R, Heber B, Hashimoto T, Messer G, Mullegger R, Niedermeier A, et al. Autoantibodies against desmocollins in European patients with pemphigus. *Clin Exp Dermatol* 2009; 34: 898–903.
- Chan LS, Vanderlugt CJ, Hashimoto T, Nishikawa T, Zone JJ, Black MM, et al. Epitope spreading: lessons from autoimmune skin diseases. *J Invest Dermatol* 1998; 110: 103–109.
- Kacar S, Sezgin O, Sahin T. Pemphigus vulgaris and ulcerative colitis. *Am J Gastroenterol* 2002; 97: 507–508.