

QUIZ SECTION

Periungual Swelling and Nail Dystrophy in a Healthy Male: A Quiz

Heather M. Holahan, Ronda S. Farah*, Gary E. Quinby and Mary Seabury Stone

Department of Dermatology, University of Iowa Hospitals and Clinics, 200 Hawkins Drive, 40025 PFP, Iowa City, IA 52242, USA. *E-mail: ronda-farah@uiowa.edu

A 47-year-old man presented with a 3-year history of a gradually enlarging lesion on the proximal nail fold of his right index finger. He reported tenderness with occasional nail splitting. There was no history of prior trauma. Treatment included intermittent application of topical neomycin, bacitracin, and polymixin B without significant improvement. Past medical history was unremarkable. Physical examination revealed a pink scaly papule at the proximal nail fold with adjacent yellow-brown thickening of the lateral nail plate (Fig. 1a). There was full range of motion of the inter-

phalangeal joint. The patient's other fingernails and toenails were within normal limits. The differential diagnosis at the time of biopsy included: glomangioma, matrix nevus, digital mucous cyst, and squamous cell carcinoma.

A punch biopsy of the medial nail fold was performed. The plate demonstrated longitudinal channels with areas of abrupt parakeratotic keratinization. There was an associated deep fibrous proliferation with papillations lined by thin epithelium (Fig. 1b and c).

What is your diagnosis? See next page for answer.

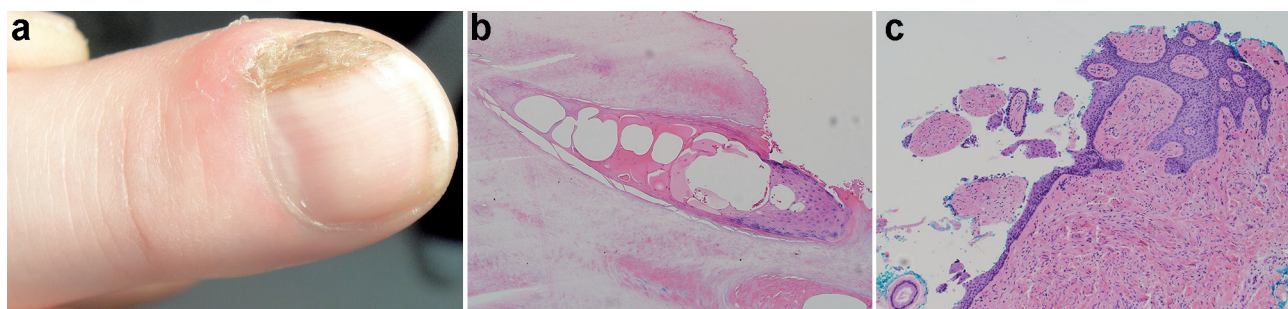


Fig. 1. (a) Longitudinal thickening of the medial nail plate with yellow-brownish discoloration and pink, edematous, scaly papule of the medial nail fold. (b) Cavity within the nail plate filled with serous fluid and onychocytic epithelium (c) Lobulated fibrous proliferation topped by bland epithelium without a granular layer. (H&E; original magnification $\times 20$ and $\times 10$, respectively).

ANSWERS TO QUIZ

Periungual Swelling and Nail Dystrophy in a Healthy Male: A Comment

Acta Derm Venereol 2014; 94: 747–749.

Diagnosis: Onychomatricoma

Onychomatricoma is a rare, benign, subungual tumor of the nail matrix. It most commonly affects middle-aged patients, with presentation more commonly on fingernails than toenails (1, 2). There have been approximately 37 reported cases to date (3, 4). Clinical characteristics include longitudinal thickening of the nail plate with transverse over-curvature, yellow-white discoloration, splinter hemorrhages, nail ridging, and multiple longitudinal hollows (1, 3). Secondary fungal infection can occur in the dystrophic nail and may make diagnosis difficult (1, 2). Radiographic evaluation reveals a lack of osseous involvement (1). Patients generally present due to aesthetic displeasure or functional impairment rather than due to pain (1). The differential diagnosis includes: glomus tumor, subungual verruca vulgaris, subungual exostosis, acral fibrokeratoma, pyogenic granuloma, malignant melanoma, and squamous cell carcinoma (2, 3).

Biopsy shows a fibro-epithelial tumor originating from the nail matrix (3). The tumor exhibits both distal and proximal involvement with each demonstrating stromal and epithelial components (3). The distal area of growth extends from the lunula, and contains many, papillary protrusions with a fibrous center and overlying epithelium (1). These protrusions extend into tiny cavities in the nail plate, appreciated as transparent channels on transverse sectioning of the nail plate (1, 2). Both distal and proximal areas contain keratogenous areas manifested by “ungal spurs” in the proximal area and thickening of the underside

of the nail plate distally (5). Immunoperoxidase staining shows the matrical tumor to be CD34 positive. S100 antibody, epithelial membrane antigen, desmin, smooth muscle actin, and nuclear beta catenin are negative (6).

Excision of the nail matrix incorporating uninvolved areas proximal to the tumor is advised for complete histopathological examination of the nail plate and to avoid potential return of the lesion (2, 3, 6, 7). Post-treatment clinical monitoring is recommended given the possibility of recurrence. Malignant transformation has not been reported.

REFERENCES

1. Gaertner EM, Gordon M, Reed T. Onychomatricoma: case report of an unusual subungual tumor with literature review. *J Cutan Pathol* 2009; 36: Suppl 1: 66–69.
2. Goutos I, Furniss D, Smith GD. Onychomatricoma: an unusual case of unguis pathology. Case report and review of the literature. *J Plast Reconstr Aesthet Surg* 2010; 63: e54–57.
3. Mueller JL, Mohr MR, Fair KP, Frazier RA, Hood AF. Subungual tumor in a 66-year old woman. *Arch Dermatol* 2010; 146: 911–916.
4. Perrin C, Langbein L, Schweizer J, Cannata GE, Balaguer T, Chignon-Sicart B, et al. Onychomatricoma in the light of the microanatomy of the normal nail unit. *Am J Dermatopathol* 2011; 33: 131–139.
5. Perrin C, Goettmann S, Baran R. Onychomatricoma: clinical and histopathologic findings in 12 cases. *J Am Acad Dermatol* 1998; 39: 560–564.
6. Tallon B, Strydom F, Emanuel PO. Nail plate clues to a remote diagnosis. *J Cutan Pathol* 2012; 40: 2–3.
7. Khelifa E, Tschanz C, Masouyé I, Kerl K, Borradori L. A rare tumor of the nail apparatus: onychomatricoma. *J Eur Acad Dermatol Venereol* 2008; 22: 1127–1128.