

CLINICAL REPORT

Early Immunopathological Diagnosis of Ichthyosis with Confetti in Two Sporadic Cases with New Mutations in Keratin 10

Andrea DIOCIAIUTI¹, Paola FORTUGNO¹, May EL HACHEM¹, Corrado ANGELO², Vittoria PROTO³, Naomi DE LUCA³, Diego MARTINELLI⁴, Renata BOLDRINI⁵, Daniele CASTIGLIA³ and Giovanna ZAMBRUNO³

¹Dermatology Unit, ⁴Unit of Metabolism, ⁵Department of Pathology, Bambino Gesù Children's Hospital-IRCCS, ²Dermatology Division, and ³Laboratory of Molecular and Cell Biology, Istituto Dermatologico dell'Immacolata-IRCCS, Rome, Italy

Ichthyosis with confetti (IC) is a severe non-syndromic ichthyosis due to heterozygous mutations in the *KRT10* gene. The disease manifests at birth with erythroderma and scaling and is characterised by the gradual development of numerous confetti-like spots of normal skin. Diagnosis of IC is frequently delayed until adolescence or even adulthood. We report 2 young children who were first diagnosed as having congenital ichthyosiform erythroderma. However, the development of thick, confluent hyperkeratotic plaques together with the histopathological finding of keratinocyte vacuolisation in the suprabasal epidermis evoked IC. Immunofluorescence analysis showed a highly reduced keratin 10 expression within the cytoplasm of suprabasal keratinocytes and its characteristic mislocalisation to the nuclei. The diagnosis was confirmed by the identification of 2 previously unreported mutations in intron 6 and exon 7 of *KRT10*. Careful clinical examination then showed the presence of the first spots of normal skin in both patients at the age of 2.5 and 5 years, respectively. These cases point to the usefulness of immunofluorescence analysis of keratin 10 expression for an early diagnosis of IC. Key words: congenital reticular ichthyosiform erythroderma; ichthyosis variegata; *KRT10*; de novo mutations.

Accepted Dec 5, 2013; Epub ahead of print Mar 13, 2014

Acta Derm Venereol 2014; 94: 579–582.

Andrea Diociaiuti, MD, Dermatology Division, Ospedale Pediatrico Bambino Gesù-IRCCS, P.zza St. Onofrio 4, IT-00165 Rome, Italy. E-mail: andrea.diociaiuti@opbg.net

Ichthyosis with confetti (IC) is a severe autosomal dominant non-syndromic ichthyosis characterised by the onset during childhood of confetti-like spots of normal skin which increase in number and size with time (1, 2). The disease is also known as ichthyosis variegata (3) or congenital reticular ichthyosiform erythroderma (1), which is the name chosen by the international ichthyosis classification (4). Patients affected with IC show erythroderma and scaling since birth, often associated to palmoplantar keratoderma. Due to this presentation, most cases are initially considered as having congenital ichthyosiform erythroderma (CIE) (2, 5, 6). The diagno-

sis of IC is usually delayed until several years after the development of the normal appearing skin spots (3, 7).

Histopathologically the ichthyotic skin shows hyperkeratosis with parakeratosis, a reduced granular layer, and focal perinuclear vacuolisation of suprabasal keratinocytes, while revertant skin displays normal architecture.

Recently it has been demonstrated that the disease is caused by heterozygous frameshift mutations typically localised in exon 6, intron 6 and exon 7 of the *KRT10* gene encoding keratin 10 (8). All identified mutations result in mutant mRNA transcripts encoding polypeptides that are arginine-enriched in their C-terminus and that abnormally accumulate within the nucleolus (8, 9). Of note, IC represents the most impressive example of revertant mosaicism as each normal appearing skin patch corresponds to an independent event of somatic reversion. The mechanism of reversion is mitotic recombination leading to loss of heterozygosity (8, 9).

We report 2 children affected by IC who were first diagnosed as having CIE. However, some atypical clinical features together with the histopathological finding of keratinocyte vacuolisation in the suprabasal epidermis instead suggested the diagnosis of IC. Immunofluorescence analysis for keratin 10 expression and subsequent mutation screening confirmed the diagnosis at the age of 2.5 and 5 years, respectively.

MATERIAL AND METHODS

Skin biopsies and blood samples were obtained after written informed consent of the patients' parents. The study was conducted in compliance with the Declaration of Helsinki principles.

Immunofluorescence labelling for keratin 10 was performed on formalin-fixed, paraffin-embedded 4 µm thick skin sections which were deparaffinised and rehydrated. Sections were heated in citrate buffer pH 7.8 (UCS Diagnostic, Morlupo, Rome, Italy) for antigen retrieval, followed by 5 min incubation in 0.2% Triton X-100 in phosphate-buffered saline (PBS). After blocking with 3% bovine serum albumin and washing in PBS, sections were incubated overnight at 4°C with the primary mouse antibody to cytokeratin 10 (dilution 1:50, clone LH2, Santa Cruz Biotechnology, Santa Cruz, CA), followed by washing and incubation with fluorescein-conjugated rabbit anti-mouse antibody for 1 h at room temperature (Dako, Glostrup, Denmark). 4',6-diamidino-2-phenylindole (DAPI) was used for nuclear counterstaining (Vector Laboratories,

Burlingame, CA). Genomic DNA was extracted from peripheral blood of the patients and the healthy parents and screened for the presence of *KRT10* mutations, as previously described by Covaciu et al. (10).

CASE REPORTS

Case 1

A 3-month-old female infant affected with ichthyosiform erythroderma was addressed to our Dermatology Unit. The patient was born as a collodion baby on the 36th week of pregnancy for premature spontaneous rupture of membranes. She was the third child of healthy non-consanguineous parents who came from the same small town (4,000 inhabitants) in Sardinia. The collodion rapidly disappeared with improvement of eclabion, ectropion and ear deformities. Within the first 2 weeks of life the patient developed sepsis complicated by an intravascular disseminated coagulopathy with portal vein thrombosis and was transferred to the intensive care unit of a University hospital where she also presented a portal cavernoma consequent to the portal thrombosis. Following resolution of the coagulopathy, the patient was discharged at the age of 2 months in good general condition.

Physical examination showed a diffuse erythroderma with thick, yellowish scales coalescing into large adherent plaques with an orange hue on the extensor surfaces of the limbs (Fig. 1a). Yellowish confluent scales were also present on the scalp, while they were whitish and thinner on the trunk. Folds and palmoplantar skin were hyperkeratotic, while hair and nails were normal.

The patient was considered having a CIE. However, during the following 2 years the limb hyperkeratosis worsened progressively especially over the joints and extremities where the plaques became particularly thick with a cobblestone appearance suggestive of a keratinopathic ichthyosis (Fig. 1b, c). In addition, a generalised hypertrichosis with dark long hair particularly evident on the trunk developed gradually (Fig. 1d). The patient also presented failure to thrive (weight and height below the 3rd percentile) and psychomotor retardation (motor skills and language).

A skin biopsy showed an acanthotic epidermis with marked hyperkeratosis, focal parakeratosis, a reduced granular layer and perinuclear vacuolisation of several spinous and granular layer keratinocytes (Fig. 2a). These findings were suggestive of IC. Immunofluorescence labelling for keratin 10 showed a marked reduction of cytoplasmic staining in all epidermal suprabasal cell layers (Fig. 2b, c) compared to normal control skin (Fig. S1c¹). In addition, numerous

suprabasal keratinocytes showed a bright nucleolar staining (Fig. 2b, c). These findings, similar to those recently reported in IC patients, were considered highly suggestive for IC (6, 9). Furthermore, molecular analysis of *KRT10* gene in the patient and her parents identified a *de novo* deletion, c.1383_1414del32 (p.Gly462_Gly472>Glyfs109), in exon 7, in linkage with the c.1468_1479del12 (p.Gly490_Gly493del) in-frame variant inherited from the father (Fig. S2a¹). The c.1383_1414del32 mutation causes a frameshift that results in the translation of a C-terminal region enriched with 50 arginine residues.

In addition to physical therapy, moisturisers and mild keratolytics containing 5% urea and 1% lactic acid, acitretin 0.2 mg/

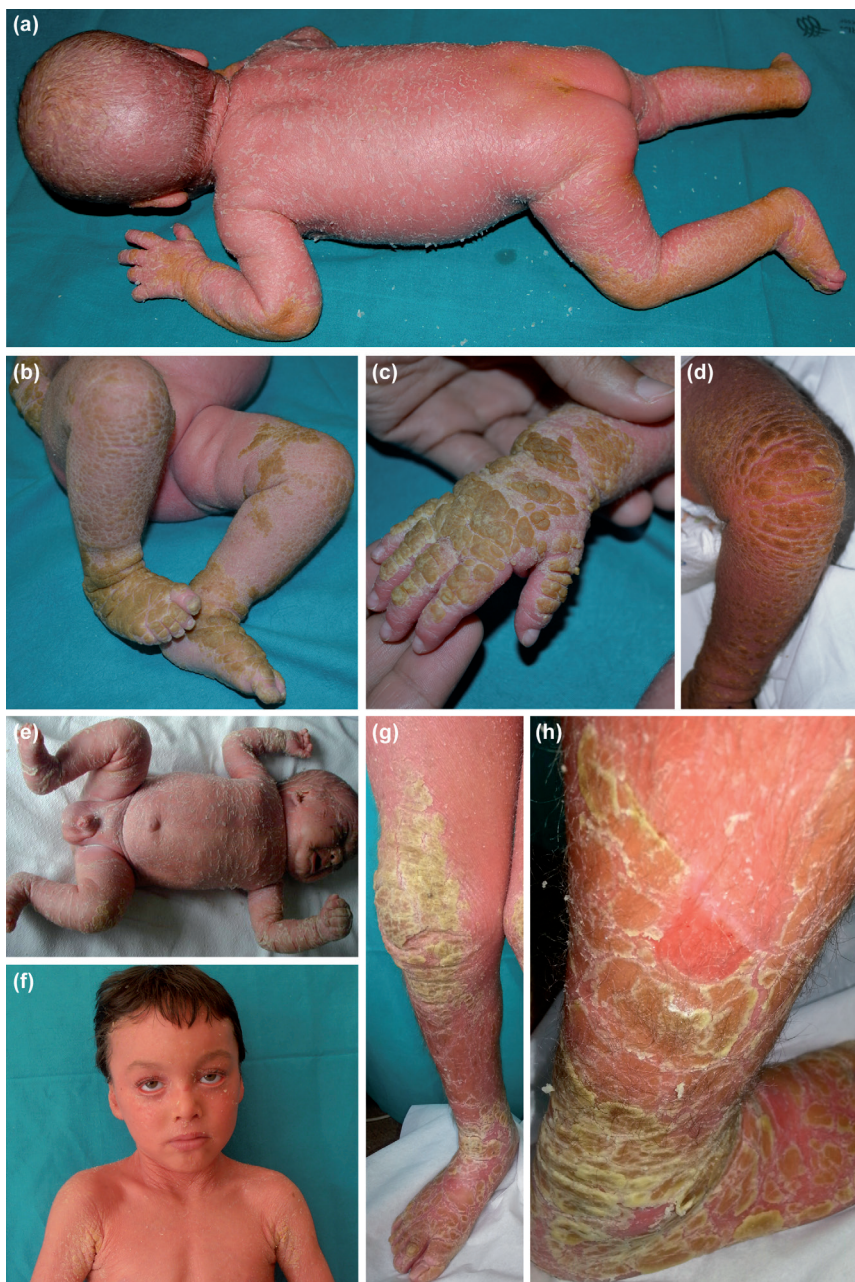

Fig. 1. Clinical features of Case 1 (a–d) and Case 2 (e–h) showing severe ichthyosiform erythroderma at the age of 3 (a) and 2 months (e), respectively, and subsequent development of massive adherent hyperkeratosis with a cobblestone and spiky appearance in Case 1 (b, c, age 1 year; d, age 1 year and 8 months). Hyperkeratotic plaques, more evident over joints, are also present in Case 2 despite retinoid treatment (f–h, age 5 years). Also note the hypertrichosis in Case 1 (d) and Case 2 (h).

kg was started at the age of 2.5 years with rapid and significant improvement of the hyperkeratosis within one month. Hyperkeratosis shedding allowed the recognition of several spots of non-erythematous normal-appearing skin of a diameter ranging from a few mm to one cm mainly localised on the trunk (Fig. S3a, b¹).

Case 2

A 2-month-old male infant was admitted to our Paediatric Dermatology Unit with ichthyosiform erythroderma. The patient was the first child of non-consanguineous healthy parents. He was born at the 34th week of pregnancy as a collodion baby which was shed within the first week of life. The patient was hospitalised for almost 2 months due to several complications including dehydration, metabolic acidosis, and sepsis. On admission in our hospital the patient presented severe erythroderma with large white desquamation on the trunk, and thicker yellowish confluent scales on the extensor limb surface (Fig. 1e). Palmoplantar keratoderma was also present together with marked ear deformity and minimal ectropion, while hair and nails were normal.

A diagnosis of CIE was made. Due to rapid hyperkeratosis worsening, the patient was started on acitretin 0.4 mg/kg from the 5th month. During follow-up hyperkeratotic plaques persisted over the limb joints, and hypertrichosis developed particularly over the limbs (Fig. 1f–h). The patient presented growth retardation (height below the 3rd percentile) and a motor impairment with a forced limb flexion secondary to hyperkeratosis. Histopathological re-evaluation of skin sections from a biopsy performed during the first hospitalisation in our institute revealed, in addition to hyperkeratosis with parakeratosis and hypogranulosis, the presence of several keratinocytes with perinuclear vacuolisation in the upper epidermal layers (Fig. S1a¹). Immunofluorescence labelling for keratin 10 was therefore performed as described above. Similarly to Case 1, it revealed a striking reduction of keratin 10 expression together with a dotted labelling of numerous nuclei in suprabasal epidermal layers (Fig. S1b, c¹). Mutation analysis of *KRT10* identified the c.1374-1G>C mutation in the proband but not in his parents. It changes the obligate G of the acceptor splice site of intron 6 (tAG > tAC) and, thus, is expected to alter *KRT10* pre-mRNA splicing in the same manner as the c.1374-1G>A, c.1374-2A>G and c.1374-2delA mutations found in the IC patients described by Choate et al. (8) (Fig. S2b¹).

Careful patient re-examination revealed the presence of a few tiny spots of normal skin on the face and back of the patient at the age of 5 years (Fig. S3c, d¹).

DISCUSSION

A few patients affected with IC have been described to date, and most of them were not followed since birth (see Table S1¹). Both our patients had a history of collodion at birth which, however, resolved quite rapidly. A collodion presentation has not been reported previously in IC. Our cases show that also IC can manifest at birth with this clinical phenotype shared by several ichthyosis forms (4).

Similar to previously reported cases, our 2 patients were initially diagnosed as CIE, due to the coexistence of erythroderma and scaling. However, in the first patient the progressive development of a massive and confluent hyperkeratosis, with a cobblestone appearance over joints, was atypical for a CIE and suggested a keratinopathic ichthyosis. The first patient also manifested a psychomotor retardation which cannot be explained only based on the severity of hyperkeratosis. This feature has never been reported in IC and needs further follow-up. On the other hand, hypertrichosis confirms to be a frequent, possibly underreported, finding of IC (Table S1¹). Hypertrichosis can be evident early in childhood, and should be carefully searched for in “atypical” cases of CIE.

In addition, normal appearing skin spots were observed in Case 1 already at the age of 2.5 years, while in previous reports their earliest detection was at the age of 6 years (11). Case 1 therefore demonstrates that revertant spots can appear in early childhood. Additionally, the presence of hyperkeratosis can mask their development, at least for some time. Indeed, in Case 1 the revertant skin spots became evident after starting the treatment with acitretin, similarly to what was described in one of the original cases by Camenzind et al. (2). Overall these observations further support the theory

¹<http://www.medicaljournals.se/acta/content/?doi=10.2340/00015555-1796>

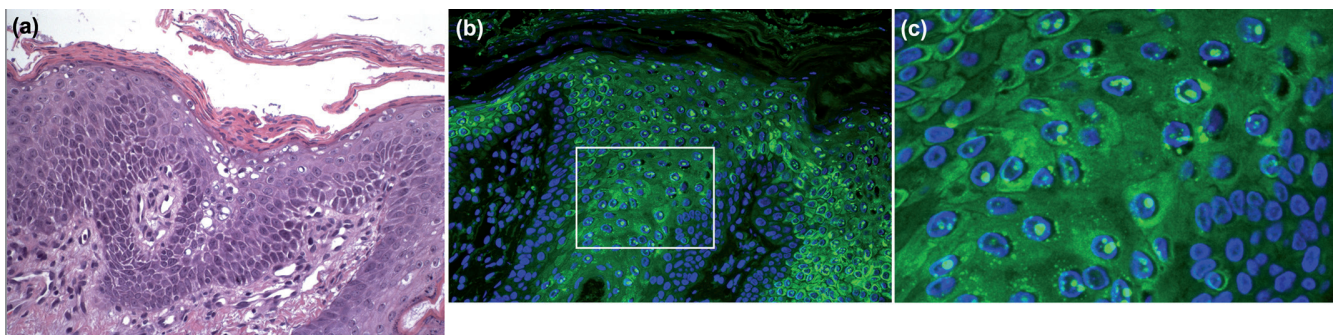


Fig. 2. Histopathological and immunofluorescence analysis of a skin biopsy in Case 1. The epidermis appears acanthotic and hyperkeratotic with a reduced granular layer and focal parakeratosis (a). Note the presence of cytoplasmic vacuolisation in several suprabasal keratinocytes. a, HE staining, original magnification $\times 200$. Immunofluorescence labelling for keratin 10 reveals a markedly reduced staining of suprabasal epidermis and the peculiar dotted nuclear labelling of numerous suprabasal keratinocytes (b). The nuclear labelling, mainly localised to nucleoli, is better visualised in panel (c), which shows a higher magnification of the inset depicted in panel (b). b and c, nuclear DAPI counterstaining, original magnification $\times 200$.

that the reverse mutations could start already in foetal life and that the progressive enlargement and growth advantage of revertant epidermal cell clones could lead to the appearance of the first revertant spots detectable, if carefully searched for, even in infancy (8, 9).

The histopathological picture of IC shows significant keratinocyte perinuclear vacuolisation, together with areas of parakeratosis and hypogranulosis. Keratinocyte vacuolisation is consequent to keratin filament damage due to *KRT10* gene mutations and further underlines the link between IC and keratinopathic ichthyoses. Indeed, present knowledge of IC indicates that it could be considered to belong to keratinopathic ichthyoses. Overall the combination of histopathological findings present in IC is characteristic and should prompt further diagnostic investigations. In this respect, we show that a simple immunofluorescence technique allows the visualisation of the nuclear localisation of keratin 10 in addition to the marked reduction of keratin 10 expression. The nuclear staining for keratin 10 has been described only in IC and can be considered a diagnostic hallmark. Importantly, the labelling is performed on routine formalin-fixed, paraffin-embedded histopathological sections and can thus represent a relatively inexpensive, rapid and widely applicable technique for the diagnosis of IC. Indeed, this technique can also be employed for the analysis of archival skin biopsy samples from patients with doubtful diagnoses, as in the case of our second patient. Of note, in our patients immunofluorescence labelling for keratin 10 led to an early diagnosis of IC before the clinical detection of normal skin spots. Furthermore, it allows an expedited mutation screening strategy targeting *KRT10* exon 6–intron 6/exon 7 where all IC mutations identified to date are located (8, 9). Here, both mutations occurred *de novo* and are predicted to generate an arginine-rich keratin tail.

In conclusion, these cases demonstrate that it is possible to diagnose IC in infancy, before revertant skin spots become evident, using immunofluorescence staining for keratin 10. In addition to being relevant to prognostication, early diagnosis of sporadic IC in infancy will enable to properly counsel the couples. In fact, while CIE is classically inherited as an autosomal recessive trait, which bears a 25% recurrence risk for subsequent pregnancies, sporadic IC has a lower risk of recurrence as it results from *de novo* event(s) during

gametogenesis or at conception. Molecular confirmation after diagnosis by immunofluorescence also provides a prenatal diagnostic tool in selected pregnancies to exclude gonadal mosaicism.

ACKNOWLEDGEMENTS

This study was supported by grants from Italian Ministry of Health (Ricerca Corrente Program) to DC and MEH, and ‘‘Association Athina Ichtyose Monaco’’ to GZ.

REFERENCES

- Marghescu S, Anton-Lamprecht I, Rudolph PO, Kaste R. Congenital reticular ichthyosiform erythroderma. *Hautarzt* 1984; 35: 522–529.
- Camenzind M, Harms M, Chavaz P, Saurat JH. Confetti ichthyosis. *Ann Dermatol Venereol* 1984; 111: 675–676.
- Happle R, Küster W. Ichthyosis variegata: a new name for a neglected disease. *J Am Acad Dermatol* 1997; 36: 500.
- Oji V, Tadani G, Akiyama M, Blanchet Bardon C, Bodemer C, Bourrat E, et al. Revised nomenclature and classification of inherited ichthyoses: results of the First Ichthyosis Consensus Conference in Sorèze 2009. *J Am Acad Dermatol* 2010; 63: 607–641.
- Ruffi T, Schneider BV, Schnyder UW. Non-bullous erythroderma (congenital) ichthyosiforme with perinuclear shells. *Hautarzt* 1990; 41: 442–447.
- Brusasco A, Tadani G, Cambiaghi S, Ermacora E, Grimalt R, Caputo R. A case of congenital reticular ichthyosiform erythroderma-ichthyosis ‘en confettis’. *Dermatology* 1994; 188: 40–45.
- Krunic AL, Palcesky D, Busbey S, Medenica M. Congenital reticular ichthyosiform erythroderma-ichthyosis variegata: a case report and review of the literature. *Acta Derm Venereol* 2003; 83: 36–39.
- Choate KA, Lu Y, Zhou J, Choi M, Elias PM, Farhi A, et al. Mitotic recombination in patients with ichthyosis causes reversion of dominant mutations in *KRT10*. *Science* 2010; 330: 94–97.
- Burger B, Spoerri I, Schubert M, Has C, Itin PH. Description of the natural course and clinical manifestations of ichthyosis with confetti caused by a novel *KRT10* mutation. *Br J Dermatol* 2012; 166: 434–439.
- Covaciu C, Castori M, De Luca N, Ghirri P, Nannipieri A, Ragone G, et al. Lethal autosomal recessive epidermolytic ichthyosis due to a novel donor splice-site mutation in *KRT10*. *Br J Dermatol* 2010; 162: 1384–1387.
- Torrelo A, Marrero MD, Mediero IG, Martínez MA, Zambrano A. Progressive macular leucoderma in a patient with congenital ichthyosiform erythroderma. *Br J Dermatol* 2001; 144: 1280–1282.