

SHORT COMMUNICATION

Segmented Heterochromia in a Single Scalp Hair

Sung Bin Cho, Zhenlong Zheng, Ji Young Kim and Sang Ho Oh*

Department of Dermatology and Cutaneous Biology Research Institute, Yonsei University College of Medicine, 50 Yonsei-ro, Seodaemun-gu, Seoul 120-752, Korea. *E-mail: oddung93@yuhs.ac

Accepted Nov 4, 2013; Epub ahead of print Dec 19, 2013

Segmented heterochromia in scalp hair refers to a hair condition resulting in alternating dark and light segments, which predominantly occurs in patients with iron-deficiency anaemia (1, 2). Here, we demonstrate a single hair shaft presenting with alternating black and white bands, which suggests unstable follicular melanocyte viability or a transient interruption of follicular melanogenesis, without any remarkable underlying conditions.

CASE REPORT

A black-haired 9-year-old Korean girl presented with greying of a few scalp hairs, the time of onset of which could not be determined. There was no remarkable past medical history or family history of autoimmune/autoinflammatory disorders, such as alopecia areata or vitiligo. On initial presentation only a few white hairs were sparsely distributed among the black scalp hair; grouped white hairs were not observed. Among the white hairs, a single hair shaft showed signs of pigment switching, consisting of 3 distinct portions: distal black (6 cm), middle white (8 cm), and proximal black (3.5 cm) (Fig. 1). With the presumption that scalp hair grows

approximately 1 cm/month, each portion was shown to be correlated with a 6-month, 8-month, and 3.5-month duration of hair growth, respectively; however, there were no remarkable changes in dietary habits or any signs of nutritional insufficiency. The patient had no distinctive lesions anywhere on the body with a chalk-white appearance by Wood's lamp examination, and a hair pull test was negative. In addition, the results of laboratory tests, including complete blood count, anti-nuclear antibody test, serum iron and ferritin level test, and thyroid function test were unremarkable.

Because the legal guardian of the patient declined a hair follicle biopsy, we examined a plucked hair shaft with transmission electron microscopy after obtaining informed consent. Transmission electron microscope analysis, showed numerous larger, mature eumelanin pigments of various sizes distributed evenly on the cortex of the black distal shaft (Fig. 2 a–c), while smaller eumelanin granules were sparsely dispersed on the cortex of the white mid-shaft (Fig. 2 d–f). On the black proximal end of the plucked hair, numerous but small mature eumelanin pigments were evenly distributed on the hair cortex (Fig. 2 g–i). The number and mean diameter of granules were measured at original magnification $\times 10,000$ in 33 granules at 31.4 ± 16.7 nm along the cortex of the distal shaft, in 4 granules at 22.0 ± 11.2 nm along the mid-shaft, and 37 granules at 16.8 ± 7.0 nm along the proximal end of the shaft using ImageJ 1.43u software (National Institutes of Health, Bethesda, MD, USA).

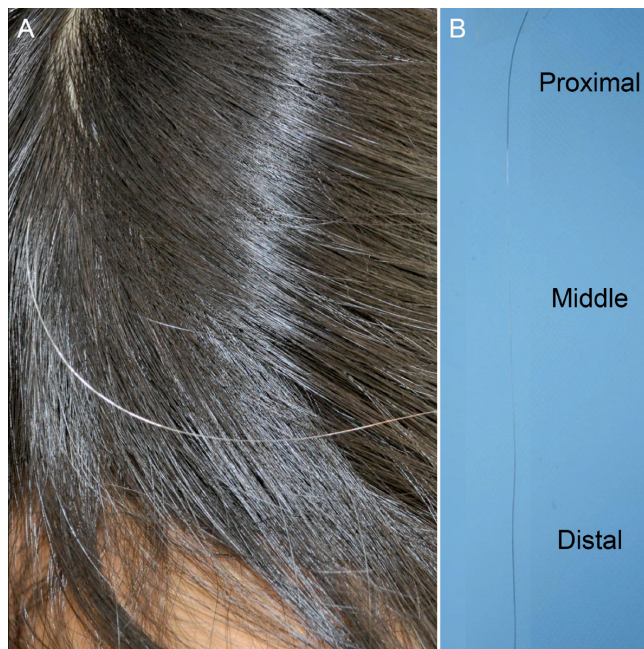


Fig. 1. Posterior scalp presenting a single hair shaft with segmented heterochromia (a). The plucked hair shaft (b).

DISCUSSION

In the current report, we demonstrated a single hair shaft of a 9-year-old Asian girl presenting with segmental heterochromia, which suggested a transient interruption of melanosome production in the follicular melanocytes. Segmental heterochromia in the scalp hair is a rare pigmentary disorder, which is mostly associated with iron deficiency anaemia (1, 2). However, it is also reported to develop without remarkable underlying haematological disorders as in our patient (3, 4). Agouti refers to a hair condition resulting in alternating eumelanin and pheomelanin production that appears in some non-human mammals. This condition clinically presents with cyclic banding of hairs. Unlike the eumelanin-to-pheomelanin switching patterns seen

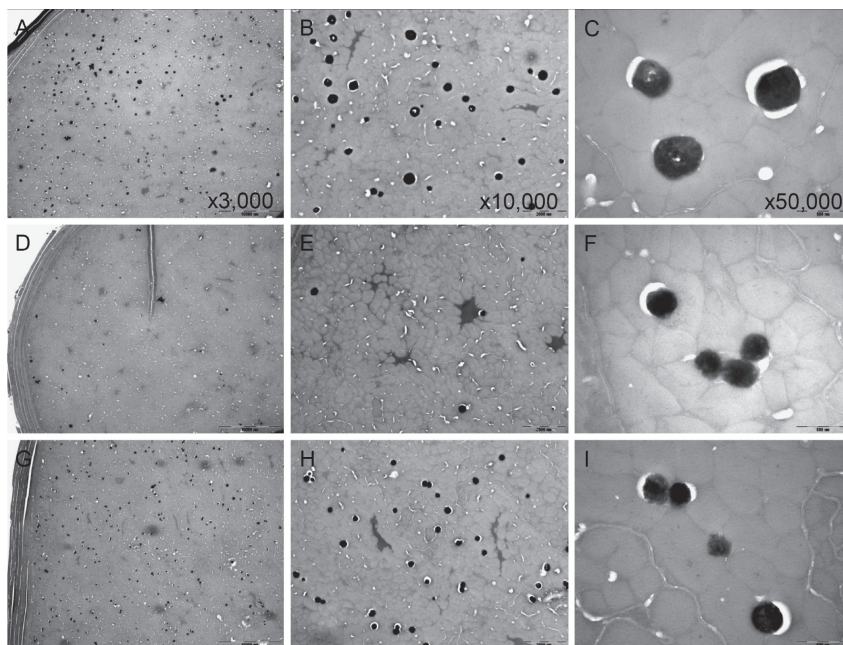


Fig. 2. Transmission electron microscopy of a plucked hair follicle with segmented heterochromia. Distal shaft (a–c), mid-shaft (d–f), and proximal shaft (g–i) of the hair.

in other mammals with agouti colouring, we found remarkable changes in the number and size of melanosomes in our patient's hair sample.

Follicular melanin is produced by cyclic and sequential regulation of melanogenesis (5). During the anagen phase, follicular melanogenesis is switched on, whereas it is switched off during catagen and is inactivated during telogen (5). However, follicular melanogenesis and melanocyte viability are known to be unstable in the early stage of hair greying (6). A previous case reported an 81-year-old man with repigmentation of his depigmented hairs after treatment for multiple myelomas with lenalidomide, a 4-amino-glutamyl analogue of thalidomide (7). Hair repigmentation of his beard and posterior scalp was noticed 6 weeks post-treatment, and pigmentation was maintained in these areas 3 months after the lenalidomide discontinuation (7). The authors of this report suggested that removing the inhibitory influences of inflammatory cytokines might influence follicular melanogenesis and that the hair greying process might not be irreversible (7). Additionally, other observations on the skin of stressed mice indicated that permanent graying resulted from the differentiation of melanocyte precursors by genotoxic influences rather than from the aging process or apoptosis of follicular melanocytes (8, 9).

Tobin & Cargnello (10) previously reported partial reversal of premature graying hairs in a 22-year-old healthy Chinese male. The authors demonstrated that focally degenerated hair bulb melanocytes were uncommonly found in the affected scalp on transmission mi-

croscopic analysis (10). In this report, we presented clinically recovered pigment production in the proximal part of a hair shaft, which contained eumelanin pigments that were smaller than the melanosomes observed in the distal part of the same hair. However, eumelanin melanosomes in all 3 parts of the hair shaft showed mature melanosomes in stage III or IV. In addition, the pattern of eumelanin distribution had recovered in the hair cortex of the proximal shaft as compared to the distal shaft.

We suggest that the dysregulated on/off behaviour of follicular melanogenesis in genetically determined follicular melanocytes may play an underestimated role in the premature hair greying process. However, it is necessary to further investigate this phenomenon in a larger study population.

The authors declare no conflicts of interest.

REFERENCES

1. Sato S, Jitsukawa K, Sato H, Yoshino M, Seta S, Ito S, et al. Segmented heterochromia in black scalp hair associated with iron-deficiency anemia. *Canities segmentata sideropenica*. *Arch Dermatol* 1989; 125: 531–535.
2. Yoon KH, Kim D, Sohn S, Lee WS. Segmented heterochromia in scalp hair. *J Am Acad Dermatol* 2003; 49: 1148–1150.
3. Faulkner C, Godbolt AM, Messenger AG, Jones SK. Non-synchronized segmented heterochromia in black scalp hair. *Clin Exp Dermatol* 2003; 28: 280–282.
4. Jung KE, Hong SP, Kim MH, Park BC. Presence of iron in segmented heterochromia of the scalp hair without iron-deficiency anaemia. *Clin Exp Dermatol* 2012; 37: 790–792.
5. Slominski A, Paus R. Melanogenesis is coupled to murine anagen: toward new concepts for the role of melanocytes and the regulation of melanogenesis in hair growth. *J Invest Dermatol* 1993; 101: 90S–97S.
6. Tobin DJ, Paus R. Graying: gerontobiology of the hair follicle pigmentary unit. *Exp Gerontol* 2001; 36: 29–54.
7. Dasanu CA, Mitsis D, Alexandrescu DT. Hair repigmentation associated with the use of lenalidomide: Graying may not be an irreversible process! *J Oncol Pharm Pract* 2013; 19: 165–169.
8. Inomata K, Aoto T, Binh NT, Okamoto N, Tanimura S, Wakayama T, et al. Genotoxic stress abrogates renewal of melanocyte stem cells by triggering their differentiation. *Cell* 2009; 137: 1088–1099.
9. Nishimura EK. Melanocyte stem cells: a melanocyte reservoir in hair follicles for hair and skin pigmentation. *Pigment Cell Melanoma Res* 2011; 24: 401–410.
10. Tobin DJ, Cargnello JA. Partial reversal of canities in a 22-year-old normal Chinese male. *Arch Dermatol* 1993; 129: 789–791.