

## SHORT COMMUNICATION

# Treatment of Generalised Vitiligo with Tacrolimus 0.1% Ointment vs. UVB Intense Pulsed Light Phototherapy: A Pilot Study

Anke Hartmann, Lisa Löhberg, Petra Keikavoussi, Saskia Eichner and Gerold Schuler

Department of Dermatology, University Hospital Erlangen, Ulmenweg 18, DE-91054 Erlangen, Germany. E-mail: anke.hartmann@uk-erlangen.de

Accepted Aug 18, 2013; Epub ahead of print Jan 28, 2014

Despite their limitations and side-effects whole-body UVB phototherapy and corticosteroids are still the mainstay in first-line treatment of vitiligo in both adults and children (1). As vitiligo usually does not affect more than 20% of the body surface, topical treatment strategies have become the focus of interest. Several clinical studies have recently shown important advantages of focused broad- (BB) or narrow-band (NB) UVB as they allow selective treatment of target lesions, along with an energy adaptation to the respective body part while sparing the normally pigmented surrounding skin (2–4). Given twice weekly up to every second week for less than 60 sessions they allow both the reduction of number of treatments as well as the cumulative doses along with higher efficiency. Furthermore, calcineurin antagonists like tacrolimus and pimecrolimus were introduced as topical immunomodulators for vitiligo and proved to be equally effective as clobetasol (5–8). Using overnight occlusive hydrocolloid dressings they proved to be effective and safe also in poorly repigmenting body areas like forearms and shins (4, 5). Recently, it was shown that tacrolimus increases pigmentation and migration of human melanocytes (9).

Until now, it is not known whether either of the 2 treatment options is generally superior to the other or whether intra-individual responses will be similar or different. In a small case study we compared for the first time the efficacy of targeted intense pulsed light (IPL) phototherapy versus tacrolimus 0.1% ointment in an intra-individual right–left comparative way for up to 9 months.

## MATERIALS AND METHODS

Eleven patients (8 women, 3 men; 15–69 years old; mean  $41 \pm 19$ ), with symmetrical vitiligo of <20% body surface area (BSA), were treated after they or their parents had signed detailed written informed consent. They had Fitzpatrick skin phototype I–IV and disease duration of 8 months up to 30 years (mean  $11.1 \pm 10$  years). Patients with a tendency to spontaneous repigmentation, those who had received topical or systemic treatment during the last 6 months, pregnant women, and patients with history of premalignant or malignant skin lesions were excluded. Tacrolimus 0.1% ointment (Protopic<sup>®</sup>, Astellas Pharma GmbH, Munich, Germany) was applied twice daily on the depigmented lesions on the face, trunk, and extremities of the right side, combined with overnight hydrocolloid dressing (Comfeel plus transparent, Coloplast GmbH, Hamburg, Germany) on the shins. Targeted phototherapy was performed

once weekly on the respective lesions of the left side, using a BBUVB light source with peak emission at 311 nm (Relume-Mode, Lumenis). Treatment of hands and feet was spared, as these regions are known to be treatment resistant (3, 5–7).

If repigmentation was not visible after 6 months the treatment was stopped. Otherwise, after 9 months therapy was continued with the most effective regimen on both treatment sides.

Patients were free to withdraw at any time during the treatment procedure. All procedures were in accordance with the ethical standards on human experimentation and with the Helsinki Declaration, as revised in 2008. Baseline photographs performed by digital photography using natural as well as Wood's light were performed at the beginning of the treatment and were compared with photographs after 3, 6, and 9 months, and at the end of treatment, respectively. Present repigmentation was evaluated. Because affected BSA was <10% in all patients and as we performed a right–left comparative treatment we calculated percent repigmentation for each treated body region instead of percentage of total vitiligo body area, as recommended by the Vitiligo European Task Force (VETF). For grading the following generally accepted scale was used: minimal <25%; moderate: 25–50%; good: 50–75%; excellent: >75%. In addition, repigmentation was also assessed by the 0–3 VETF staging score as recommended (10). To the best of our knowledge, this score has been used so far only in one pilot clinical trial but did not show significant improvement (11). For statistical evaluation, the student *t*-test was used to calculate the difference between the means of 2 independent samples. The significance level was set at  $p=0.05$ .

## RESULTS

In the 11 patients vitiligo lesions in 35 different body areas (1–325 cm<sup>2</sup>) were treated. Mean starting fluence was  $50.5 \pm 17.6$  mJ/cm<sup>2</sup> in UV-sensitive regions (face, neck, trunk, upper arms, and thighs) and  $87.7 \pm 34.4$  mJ/cm<sup>2</sup> in UV-insensitive areas (forearms, elbows, knees, lower extremities), respectively. After 9 months, mean highest fluence was  $277 \pm 202$  mJ/cm<sup>2</sup> in UV-sensitive and  $705 \pm 535$  mJ/cm<sup>2</sup> in insensitive areas, respectively.

After 6 months, 2 of 11 patients did not show any repigmentation and thus treatment was stopped. In the remaining 9 patients, mean time of initial repigmentation on the tacrolimus-treated side was comparable to the UVB-treated side, even if face, trunk and extremities were considered separately (face: tacrolimus  $8.0 \pm 1.0$  weeks versus UVB-IPL  $9.3 \pm 4.9$  weeks,  $p=0.69$ ; trunk: tacrolimus  $10.0 \pm 2.0$  weeks versus UVB-IPL  $10.0 \pm 5.4$  weeks,  $p=0.73$ ; extremities: tacrolimus  $14.8 \pm 5.8$  weeks versus UVB-IPL  $14.3 \pm 6.2$  weeks,  $p=0.99$ ). After 6 months, the mean percentage of repigmentation of all

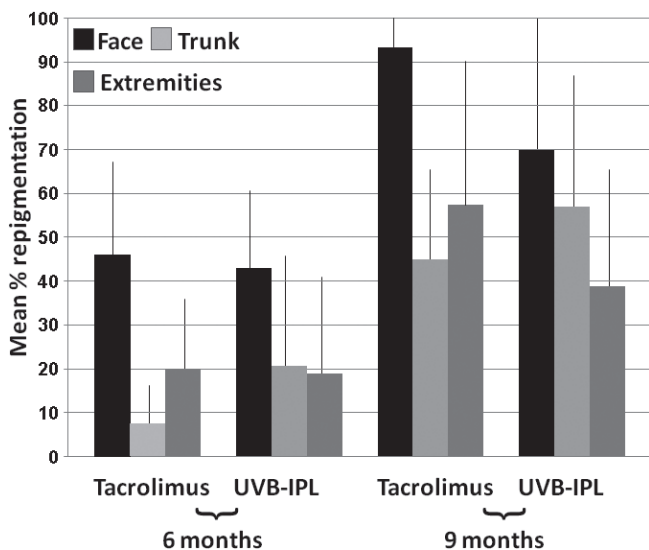


Fig. 1. Mean percentage repigmentation of lesions on the face, trunk and extremities after 6 months (non-responders included) and 9 months treatment (without non-responder, which stopped treatment after 6 months) with tacrolimus 0.1% ointment (right side of the body) versus targeted UVB-phototherapy (left side of the body), respectively.

treated body sites, non-responding lesions included, was comparable between tacrolimus- and UVB-treated lesions (Fig. 1). After 9 months, 38% of lesions on the tacrolimus-treated side on the trunk showed repigmentation compared to 63% on the UVB-treated side, whereas on face and extremities 67% and 80% of the lesions on both treatment sides responded. Mean percentage of repigmentation on the face and extremities was higher on the tacrolimus-treated side compared to the UVB-treated side; however, the differences were not statistically significant (Fig. 1).

According to the VETF staging scale mean staging score before and after treatment was similar for each side of the body ( $1.85 \pm 0.4$  on the tacrolimus side and  $1.85 \pm 0.5$  on the UVB-treated side at the start, and  $1.25 \pm 0.6$  and  $1.25 \pm 0.7$  at the end of treatment, respectively). Thus, mean decrease was 0.6, translating to a significant 32% improvement ( $p=0.001$  and  $0.003$ , respectively).

Four patients showed moderate to excellent repigmentation after treatment with either tacrolimus or UVB-IPL, respectively; however, on the respective opposite region there was only minimal or no reaction (Fig. S1A<sup>1</sup> and Fig. S2<sup>1</sup>). Five patients showed repigmentation with both treatment modalities; however, the bilateral responses were intra-individually considerably different (Fig. S1B<sup>1</sup>, Fig. S3<sup>1</sup>), with either a follicular or a homogeneous interfollicular pattern of repigmentation or a mixture of both, without any correlation to treatment mode or localisation of the respective area. After 9 months, 4 patients continued with the more effective regimen on both treatment sides for up to additional 9

months and, interestingly, all revealed repigmentation similar to the original opposite side (Fig. S2C<sup>1</sup>). Side effects included initial mild prickling on the tacrolimus-treated and transient erythema and perilesional tanning on the left side.

## DISCUSSION

In our pilot study we compared for the first time 2 increasingly accepted localised approaches for vitiligo treatment in patients with generalised vitiligo in a direct right/left fashion. Long-term treatment with weekly sessions of targeted UVB-IPL phototherapy, as well as twice daily tacrolimus 0.1% ointment proved overall to be comparably effective as measured by mean time to initial repigmentation and mean percent repigmentation. Our pilot study in 11 patients, although small, clearly indicated that intra-individual differences occur and that treatment response to one of the topical approaches does not generally imply response to another treatment as well. Although it is known that tacrolimus – in contrast to corticosteroids – does not penetrate through an intact skin barrier and into the circulation, the possibility and relevance of systemic effects of either of the 2 topical treatment approaches cannot be completely excluded (6, 12). Importantly, for the individual patient, response to either of the 2 treatments is currently not predictable and may vary considerably between different body areas. Given these facts it is not surprising that the results of inter-individual comparative studies were often incongruent, and would require very large cohorts to come to reliable results. Our findings confirm the importance of intra-individual right/left comparative studies, which has also been suggested by others (13). Our preliminary results should be confirmed in a larger prospective, randomised clinical trial, which may also allow to outline urgently needed parameters predicting responses.

## REFERENCES

- Gawkrodger DJ, Ormerod AD, Shaw L, Mauri-Sole I, Whitton ME, Watts MJ, et al. Vitiligo: concise evidence based guidelines on diagnosis and management. *Postgrad Med J* 2010; 86: 466–471.
- Hofer A, Hassan AS, Legat FJ, Kerl H, Wolf P. The efficacy of excimer laser (308 nm) for vitiligo at different body sites. *J Eur Acad Dermatol Venereol* 2006; 20: 558–564.
- Welsh O, Herz-Ruelas ME, Gómez M, Ocampo-Candiani J. Therapeutic evaluation of UVB-targeted phototherapy in vitiligo that affects less than 10% of the body surface area. *Int J Dermatol* 2009; 48: 529–534.
- Asawanonda P, Kijluakiat J, Korkij W, Sindhupak W. Targeted broadband ultraviolet B phototherapy produces similar responses to targeted narrowband ultraviolet B phototherapy for vitiligo: a randomized, double-blind study. *Acta Derm Venereol* 2008; 88: 376–381.
- Lepe V, Moncada B, Castaneda-Cazares JP, Torres-Alvarez MB, Ortiz CA, Torres-Rubalcava AB. A double-blind ran-

<sup>1</sup><http://www.medicaljournals.se/acta/content/?doi=10.2340/00015555-1740>

- domized trial of 0.1% tacrolimus vs 0.05% clobetasol for the treatment of childhood vitiligo. *Arch Dermatol* 2003; 139: 581–585.
6. Hartmann A, Bröcker EB, Hamm H. Occlusive treatment enhances efficacy of tacrolimus 0.1% ointment in adult patients with vitiligo: results of a placebo-controlled 12-month prospective study. *Acta Derm Venereol* 2008; 88: 474–479.
  7. Hartmann A, Bröcker EB, Hamm H. Repigmentation of pretibial vitiligo with calcineurin inhibitors under occlusion. *J Dtsch Dermatol Ges* 2008; 6: 383–385.
  8. Lubaki LJ, Ghanem G, Vereecken P, Fouty E, Benammar L, Vadoud-Seyedi J, et al. Time-kinetic study of repigmentation in vitiligo patients by tacrolimus or pimecrolimus. *Arch Dermatol Res* 2010; 302: 131–137.
  9. Kang HY, Choi YM. FK506 increases pigmentation and migration of human melanocytes. *Br J Dermatol* 2006; 155: 1037–1040.
  10. Ta'ieb A, Picardo M; VETF Members. The definition and assessment of vitiligo: a consensus report of the Vitiligo European Task Force. *Pigment Cell Res* 2007; 20: 27–35.
  11. Szczerko O, Shear N, Taddio A, Boon H. Ginkgo biloba for the treatment of vitiligo vulgaris: an open label pilot clinical trial. *BMC Complement Altern Med* 2011; 11: 21.
  12. Bos JD, Meinardi MM. The 500 Dalton rule for the skin penetration of chemical compounds and drugs. *Exp Dermatol* 2000; 9: 165–169.
  13. van Geel N, Speeckaert R, Mollet I, De Schepper S, De Wolf J, Tjin EP, et al. In vivo vitiligo induction and therapy model: double-blind, randomized clinical trial. *Pigment Cell Melanoma Res* 2012; 25: 57–65.