

SHORT COMMUNICATION

Symmetrical Giant Facial Plaque-type Juvenile Xanthogranuloma Persisting Beyond 10 years of Age

Kazumitsu Sugiura¹, Yoshie Hasegawa¹, Yoshie Shimoyama², Hideo Hashizume³ and Masashi Akiyama¹¹Department of Dermatology, Nagoya University Graduate School of Medicine, 466-8550 Nagoya, ²Department of Pathology and Clinical Laboratories, Nagoya University Hospital, Nagoya, and ³Department of Dermatology, Shimada City Hospital, Shimada, Japan. E-mail: kazusugi@med.nagoya-u.ac.jp
Accepted Jun 25, 2013; Epub ahead of print Nov 8, 2013

Juvenile xanthogranuloma (JXG) is a non-Langerhans histiocytosis occurring predominantly in infancy and early childhood. Resolution usually occurs over a period of months to several years, and it is rare for the condition to persist beyond late childhood (1). The symmetrical giant facial plaque variant of JXG (SGFP-JXG) is very rare. It was originally reported by Gunson & Birchall. (2). Herein we report a case of SGFP-JXG that persisted beyond 10 years of age.

CASE REPORT

A 10-year-old Japanese boy was referred to our clinic with facial yellowish papules. He was a fraternal twin, the result of a normal pregnancy and delivery, and was otherwise completely healthy and taking no regular medications. The twin brother showed no skin lesions. There was no particular family history, such as neurofibromatosis. The plaques were first noticed as red macules at approximately 6 months of age, which slowly evolved during the first year of life. He had also had yellowish nodules on the bilateral arms. He had come to a nearby dermatology clinic at 2 years of age (Fig. 1A). At that time, a biopsy from a skin lesion on the left arm showed mixed inflammatory cell infiltration containing small lymphocytes and histiocytes from the superficial dermis, extending into the deep dermis. Touton giant cells and numerous foam cells were present (Fig. 2). The nodules on the arms had been diagnosed as JXG. Although the JXG on the arms gradually decreased in size and mostly resolved, the facial lesions did not improve. Physical examination at the age of 10 revealed symmetrical yellowish indurated

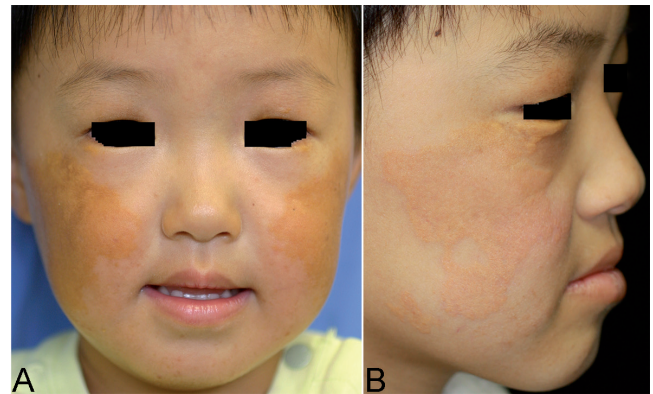


Fig. 1. Multiple yellowish plaques are distributed symmetrically on the upper and lower eyelids and on the cheeks. (A) At 2 years of age. (B) At 10 years of age.

plaques with smooth surface on the bilateral upper and lower eyelids and on the cheeks (Fig. 1B). Similar yellowish nodules were also seen on the left elbow. There was neither ophthalmic or oral mucosal involvement, or palpable hepatosplenomegaly nor lymphadenopathy. Pathological findings following a skin biopsy at the age of 10 from the lesion on the right cheek were consistent with JXG (Fig. 3A). In addition, CD68 was positive (Fig. 3B), but S-100, CD1a, and langerin were negative (data not shown) by immunohistochemistry, which is also consistent with JXG. Hence, the patient was diagnosed with SGFP-JXG.

DISCUSSION

JXG usually manifests as an asymptomatic, reddish-brown nodule which slowly grows to a diameter of 1–2

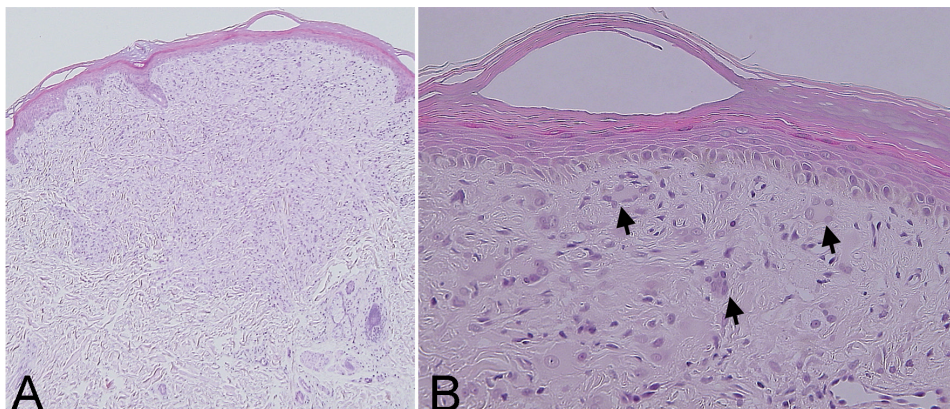


Fig. 2. Haematoxylin-eosin staining of the yellowish nodule on the left arm at 2 years of age. Numerous foam cells are seen throughout the dermis (original magnification $\times 4$) (A). Giant cells and numerous foam cells are seen. Arrows indicate Touton giant cells (original magnification $\times 20$) (B).

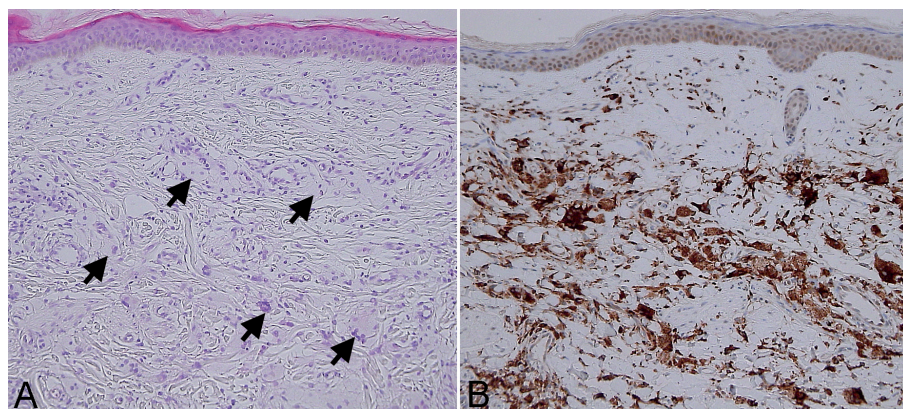


Fig. 3. Haematoxylin-eosin staining of the yellowish plaque on the right cheek at 10 years of age. Many foam cells are seen in the dermis (A). Immunohistochemistry of CD68 on the lesion of the right cheek. The histiocytes are CD68 positive (B) (original magnification $\times 10$). Arrows: Indicates gaint cells and foam cells.

cm. Evolution into a yellowish-brown papule, plaque or nodule often occurs, followed by spontaneous resolution that may leave an atrophic scar.

Plaque and clustered types of JXG at extrafacial sites have been reported (3, 4). However, despite the atypically large lesions, these types of JXG usually reduce with scarring and pigmentation within a year.

SGFP-JXG was first reported by Gunson & Birchall (2) in 2008. To the best of our knowledge, our report is the second reported case of SGFP-JXG. Gunson & Birchall described SGFP-JXG lesions as multiple large, flat, symmetrically distributed plaques of over 2 cm in diameter (2). The case in the literature had facial lesions, without any JXG lesions on other body sites. The lesions had been present for >6 years and had shown no sign of spontaneous resolution. The present case has also had the facial lesions for 10 years without any noticeable tendency of spontaneous resolution. Interestingly, he had also had JXG on the arms, and it tended to spontaneously resolve. Disseminated JXG, which has multiple cutaneous lesions, is sometimes associated with visceral JXG in infancy (5, 6). Both the present SGFP-JXG case and the patient in the literature showed no involvement of internal organs. Unfortunately, the therapeutic options are limited given the large and cosmetically sensitive area involved.

In conclusion, we report herein the second case of SGFP-JXG, and both cases suggest that this type of

JXG may persist beyond the age of 10 years but that it is not associated with visceral lesions.

ACKNOWLEDGEMENT

This study was supported in part by Grants-in-Aid for Scientific Research (C) 23591617 (KS) and (A) 23249058 (MA) from the Ministry of Education, Culture, Sports, Science and Technology of Japan.

The authors declare no conflicts of interest.

REFERENCES

1. Chang MW. Update on juvenile xanthogranuloma: unusual cutaneous and systemic variants. *Semin Cutan Med Surg* 1999; 18: 195–205.
2. Gunson TH, Birchall NM. Symmetrical giant facial plaque-type juvenile xanthogranuloma. *J Am Acad Dermatol* 2008; 59(2 Suppl 1): S56–57.
3. Yazganoglu KD, Erdem Y, Buyukbabani N, Baykal C. A giant congenital plaque. *Pediatr Dermatol* 2012; 29: 217–218.
4. Kaur MR, Brundler MA, Stevenson O, Moss C. Disseminated clustered juvenile xanthogranuloma: an unusual morphological variant of a common condition. *Clin Exp Dermatol* 2008; 33: 575–577.
5. Haughton AM, Horii KA, Shao L, Daniel J, Nopper AJ. Disseminated juvenile xanthogranulomatosis in a newborn resulting in liver transplantation. *J Am Acad Dermatol* 2008; 58(2 Suppl): S12–15.
6. Patel P, Vyas R, Blickman J, Katzman P. Multi-modality imaging findings of disseminated juvenile xanthogranuloma with renal involvement in an infant. *Pediatr Radiol* 2010; 40 Suppl 1: S6–10.