

## CLINICAL REPORT

# Livedoid Vasculopathy: Clinical Features and Treatment in 24 Chinese Patients

Suying FENG<sup>1</sup>, Wei SU<sup>2</sup>, Peiyong JIN<sup>1</sup> and Changgeng SHAO<sup>1</sup>

<sup>1</sup>Jiangsu Key Laboratory of Molecular Biology for Skin Diseases and STIs, Institute of Dermatology, Chinese Academy of Medical Sciences and Peking Union Medical College, Nanjing, China and <sup>2</sup>Department of Pathology, Ameripath Southwest Florida, Ft Myers, USA

**Livedo vasculopathy (LV) is a chronic cutaneous disorder characterised by recurrent, painful ulceration ending in stellate scars. We have conducted a retrospective study of clinical features and treatment response of LV in 24 Chinese patients. LV occurred more frequently in women (male:female ratio 1:3). The peak age at onset of disease ranged from 14 to 20 years, younger than previously published data. 87.5% of the patients (21/24) showed significant summer exacerbation with ulcer formation. Out of 24 patients tested, 14 (58.3%) had positive antiphospholipid antibodies. Ten out of 14 patients (71.4%) were tested to be hypersensitive to multivalent insect antigens. Combinative anti-inflammatory therapy with steroids, tetracycline and Tripterygium glycosides plus antiplatelet/profibrinolytic drugs promoted quick healing of ulcer and reduce recurrence. The younger age of disease presentation and significant summer exacerbation are 2 novel clinical features observed in this study. These findings suggest that apart from procoagulation other risk factors may contribute significantly to the pathogenesis of LV. Although antiplatelet/profibrinolytic drugs are deemed as a first line therapy for LV, anti-inflammatory medications such as steroids, tetracycline and Tripterygium glycosides, from our experiences, are indispensable, especially for acute, ulcerative stage of disease. Key words: livedoid vasculopathy; clinical features; treatment.**

Accepted Jun 19, 2013; Epub ahead of print Dec 17, 2013

Acta Derm Venereol 2014; 94: 574–578.

Suying Feng, Jiangsu Key Laboratory of Molecular Biology for Skin Diseases and STIs, Institute of Dermatology, Chinese Academy of Medical Sciences and Peking Union Medical College, Nanjing, China. E-mail: suyong\_f@yahoo.com

Livedoid vasculopathy (LV) is a chronic vascular occlusive disease characterised clinically by livedo reticular erythema complicated by recurrent and painful ulcers which lead to stellate scars after healing. The areas of the body commonly involved are medial and lateral ankle as well as dorsal feet. The disease is very painful and notorious to treat, significantly affecting the quality of the patient's life (1, 2). Although the exact pathogenesis of

LV is unclear at present, more and more evidence points to procoagulation as the culprit of this disease (3–8).

During the period 1996–2010 we have treated 24 patients with LV with good outcome. The purpose of this paper is to summarise clinical characteristics of LV, especially those novel features that have not been emphasised in previous studies, as well as therapeutic effects of our standardised treatment regimen.

## MATERIALS AND METHODS

### Patients

Cases were collected retrospectively from the archives of the Institute of Dermatology, Chinese Academy of Medical Sciences, Peking Union Medical College for the period 1996–2010. Inclusion criteria include: (i) Livedoid reticular erythema or stellate white scar complicated with recurrent painful ulceration involving predominantly ankles, dorsal feet and legs. (ii) Histologic confirmation of presence of hyalinising changes of vascular walls with or without intraluminal thrombi. (iii) No other causes, such as bona fide vasculitis, primary antiphospholipids antibody syndrome or drugs, were accounted for clinical symptoms.

Data were collected from medical records and clinical photographs of the patients. The following data were analysed: age of onset of disease, sex, duration of disease at diagnosis and during follow-up, topography and description of cutaneous lesions, treatment regimen and response, and duration of follow-up.

### Methods

**Anticardiolipin antibody (ACA) testing (9):** Quantitative ELISA was performed by using IgAGM kit (EA 1621-9601 P), which was provided by OUMENG, Luebeck, Germany. Following the manufacturer's instructions, the positive predict value of ACA is more than 12 relative units (RU)/ml in our study, we put 20–40 RU/ml as representing slightly positive, 41–60 RU/ml as moderately positive, and > 60 RU/ml as strongly positive. In healthy controls <5% are positive for ACA (according to our experience).

**Anti-β2GPI antibody testing:** Quantitative ELISA was performed by using IgAGM kit (EA 1632-9601 P), which was provided by OUMENG. Following the manufacturer's instructions, the positive predictive value of Anti-β2GPI antibody is more than 20 RU/ml.

**Anaphylactogen skin prick test:** The test kit was from The New Hualian Union Pharmaceutical Co. Ltd. Following the manufacturer's instructions, 1:10 volume allergen extract solution was injected in the volar forearm. Each droplet contained a single allergen or mixes of closely related allergens. Injection sites were placed at least 2 cm apart to avoid overlapping

reactions. Histamine dichloride and glycerinated saline were used as positive and negative controls, respectively. A wheal diameter >3 mm was considered positive.

## RESULTS

Table I summarizes the patients' clinical characteristics.

### *Patients, cutaneous lesions and comorbidities*

Twenty-four patients were included (male:female 1:3). The mean age at onset of disease was 17.0 years old (5 between 9–13 years, 17 between 14–20 years, one between 21–35 years, and one >35 years). The duration of disease at the time of presentation to our clinic ranged from 2 months to 15 years.

When referred to our clinic, all 24 patients' conditions were in acute stage with small ulcers, stellate scars and variable degree of hyperpigmentation. Eleven patients initially presented with purpura before developing ulcers and scars. Ten cases had accompanying telangiectasia; 15 cases had significant pain, 2 had pruritus; 4 had both pain and pruritus; 3 young patients (all under 14 years old) developed haemorrhagic blisters. All patients had bilateral disease. In 19 patients skin lesions were localised around the ankles and on the dorsal feet; in 4

patients the typical skin lesions of LV occurred initially around ankles and telangiectasia then developed gradually and spread to whole lower extremities and dorsal feet. In one patient the cutaneous lesions were limited to dorsal feet and toes with painful ulcers between toes, severely affecting ambulation. Clinical photos of 2 patients are shown in Fig. 1.

One patient had hypertension, one patient had diabetes and 3 patients had mild superficial varicosis on the lower extremities.

### *Possible risk and aggravation factors*

Twenty-one (87.5%) patients showed obvious summer exacerbation with development of ulcer. One patient's symptoms were worse in winter. Two patients showed no seasonal variation. In 12 patients the disease was exacerbated after long period of standing. In 3 patients the symptoms were worse after upper respiratory tract infection. Two patients had history of trauma to legs and feet before development of LV in these regions.

### *Histopathology*

All patients underwent skin biopsy. The histology of LV was characterised by dilated and tortuous blood

Table I. Clinical and treatment information of the 24 patients with livedoid vasculopathy

Pat. No.	Sex/Age, years	AO	Location of cutaneous lesions	Comorbidity	SE	ACA	β2GP1	AT	TAS	MS	FU
1	F/9	9	Ankle dorsal foot		Summer	Low	–	+	c	a	24
2	F/12	11	Ankle dorsal foot		Summer	–	–	Not done	d	b	24
3	F/14	14	Ankle dorsal foot		Summer	–	–	+	d	b	12
4	F/15	15	Lower legs, dorsal foot		Summer	Moderate	–	Not done	a	a	48
5	F/15	11	Ankle dorsal foot		Summer	Moderate	Low	+	a	a	48
6	F/15	11	Ankle dorsal foot		Summer	Moderate	–	Not done	a	a	60
7	F/16	12	Ankle dorsal foot		Summer	High	Moderate	Not done	a	a	48
8 <sup>a</sup>	M/18	16	Lower legs, dorsal foot		Summer	–	–	+	b	c	12
9	F/18	18	Ankle dorsal foot		Winter	–	–	Not done	b	b	3 <sup>b</sup>
10	F/19	18	Ankle dorsal foot		Summer	Moderate	Moderate	–	a	a	52
11	M/20	19	Ankle dorsal foot		Summer	–	–	Not done	b	b	48
12	F/20	14	Ankle dorsal foot		Summer	–	Low	+	a	a	6b
13 <sup>a</sup>	F/20	16	Lower legs, dorsal foot		Summer	High	–	–	a	c	12
14	F/21	18	Ankle dorsal foot		Summer	Low	–	Not done	a	a	24 <sup>b</sup>
15	F/21	18	Dorsal foot, toe webs		Summer	–	–	Not done	b	b	60
16	F/21	16	Ankle dorsal foot	Diabetes	Summer	–	–	+	e	b	84
17	M/22	20	Ankle dorsal foot		None	–	Moderate	–	a	a	60
18	M/24	18	Ankle dorsal foot		None	Moderate	–	+	a	a	48
19 <sup>a</sup>	F/24	19	Lower legs, dorsal foot	Mild varicosis	Summer	–	–	+	b	c	6 <sup>b</sup>
20	F/24	17	Ankle dorsal foot		Summer	Moderate	–	+	a	a	24
21	M/26	20	Ankle dorsal foot		Summer	–	–	+	b	b	12 <sup>b</sup>
22 <sup>a</sup>	M/35	20	Ankle dorsal foot	Mild varicosis	Summer	–	–	Not done	b	c	12 <sup>b</sup>
23	F/37	22	Ankle dorsal foot	Mild varicosis	Summer	–	–	Not done	b	b	60
24	F/52	37	Ankle dorsal foot	Hypertension	Summer	–	Moderate	–	e	a	120

<sup>a</sup>Refers to the patients whose lesions were accompanied with prominent telangiectasia.

<sup>b</sup>Six patients discontinued all the medications with no recurrence of disease.

AO: age at onset; SE: seasonal exacerbation; ACA: anticardiolipin antibody; AT: anaphylactogen test; TAS: treatment in acute stage; MS: maintenance stage; FU: Follow-up (months).

*Selection of treatment in acute stage:* a: tetracycline, prednisone, Tripterygium glycoside (TG), pentoxifylline and aspirin; b: tetracycline, prednisone, TG and pentoxifylline; c: prednisone, TG, pentoxifylline and aspirin; d: dapson, prednisone, TG and pentoxifylline; e: Danazol, tetracycline, TG and pentoxifylline.

*Selection of treatment in maintenance stage:* a: pentoxifylline 0.4 g every other day and aspirin 25 mg every day; b: pentoxifylline 0.4 g every other day; c: danazol 200 mg every other day.

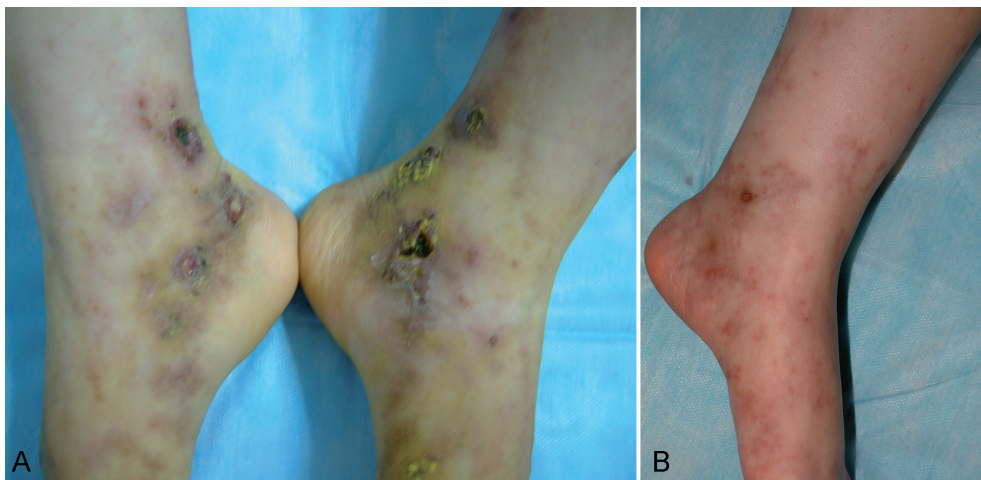


Fig. 1. Atrophy blanche with multiple punctate ulcers, hyperpigmentation and telangiectasia (A, Patient no. 12). Livedo reticular erythema with incipient ulceration (B, Patient no. 13).

vessels in the dermis. The vascular wall was thickened and oedematous with proliferation of endothelial cells. Some vessels showed fibrin deposition both within the wall and inside the lumen. There was perivascular lymphocytic infiltrate with no significant neutrophils, unlike leukocytoclastic vasculitis (Fig. 2). Among 12 patients tested by direct immunofluorescence, 7 showed C3 and immunoglobulin deposition within the blood vessel walls.

#### Laboratory examination.

Routine workups for coagulation were conducted: platelet count and function tests, prothrombin time, activated partial prothrombin time, protein C and S levels were within normal limits for all 24 patients. In addition, all 24 patients underwent serology study of ANA, anticardiolipin antibody (ACA), and anti- $\beta$ 2GPI. ACA was present in 11 patients (45.8%, 3 were slightly positive, 6 moderately positive and 2 strongly positive).  $\beta$ 2GPI antibody was present in six patients (25%; 2 were slightly positive, 4 moderately

positive). Three patients were tested positive for both ACA and  $\beta$ 2GPI. Out of 24 patients, two showed low titer ANA, one of which had positive immunocomplex but with normal levels of immunoglobulin and ENA polypeptide. The antineutrophil cytoplasmic antibody (ANCA) test was negative for all patients. The anaphylactogen skin prick test was carried out in 14 patients, 10 of which showed hypersensitivity to multivalent insect antigens.

#### Treatment and follow-up

For all patients, anti-platelet/profibrinolytic drugs (aspirin and/or pentoxifylline and danazol) were the primary therapy for the quiescent stage of disease. Anti-inflammatory medications such as steroid, tetracycline and Tripterygium glycosides (TG) were added to control acute symptoms and to prevent recurrence. Extracted from a Chinese herb, TG is a widely used medication in China for its anti-inflammatory and immunosuppressive function.

The starting medication in 21 patients  $\geq 15$  years of age included prednisone 15 mg/day; tetracycline 0.25 g, 3 times a day; TG 20 mg, 2 or 3 times a day; and pentoxifylline 0.4 g/day. For the 3 younger patients, tetracycline was replaced with dapsone, 25 mg twice a day. In 11 patients with positive ACA and/or  $\beta$ 2GPI antibody small dose of aspirin (25 mg/day) was added. Danazol 200 mg/day was used in place of steroid in one patient with diabetes and in another patient with hypertension. Two weeks after start of therapy, all patients showed significant clinical improvement: pain diminished prominently or disappeared, and ulcers began to heal. At this time, prednisone was reduced to 10 mg/day; tetracycline to 0.25 g twice a day, TG to 10 mg twice a day, dapsone to 25 mg/day, whereas the doses of pentoxifylline and aspirin remained unchanged. At one month follow-up ulcers were healed in all patients with only a few erythematous macules visible, at which time prednisone was reduced to 5 mg/day, tetracycline to

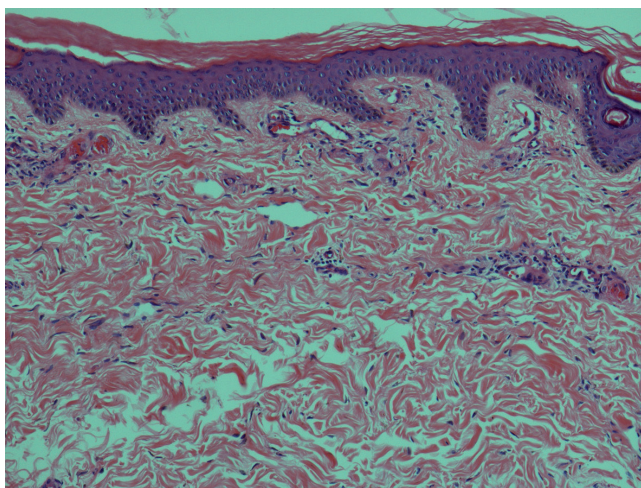


Fig. 2. Fibrin deposition within the lumen and walls of vessels (H&E  $\times$  100).



0.25 g/day, TG to 10 mg/day, pentoxifylline to 0.4 g every other day, whereas aspirin was kept at 25 mg/day and dapsone was stopped. These dosages were maintained for 2–4 weeks before tapering as follows: prednisone 5 mg every other day, tetracycline 0.25 g/day, pentoxifylline 0.4 g every other day, aspirin 25 mg/day and TG stopped altogether. These dosages were kept for another month before reaching pre-maintenance therapy consisting of prednisone 5 mg every 3 days, tetracycline 0.25 g/day, pentoxifylline 0.4 g every other day and aspirin 25 mg/day. In 2 patients who used danazol instead of prednisone, the dose of danazol were kept at 200 mg/day before pre-maintenance therapy and reduced to 200 mg every other day during pre-maintenance therapy. When the disease was quiescent, treatment regimen was switched to maintenance therapy, which was pentoxifylline 0.4 g every other day for the patients without ACA/ $\beta$ 2GP1 antibody or pentoxifylline 0.4 g every other day plus aspirin 25 mg/day for the patients with ACA and/or  $\beta$ 2GP1 antibody. For the 4 patients who had prominent telangiectasia, danazol mono-drug therapy (200 mg every other day) was used.

The follow-up period ranged from 3 months to 10 years. Six patients discontinued all medications with no recurrence of disease (the follow-up period for these 6 patients ranged from 3–24 months). Ten patients stopped maintenance therapy in low risk seasons (winter/autumn) but needed smaller doses of medications (prednisone 5–10 mg/day; TG 20 mg twice a day or (and) tetracycline 0.25 g/day; and pentoxifylline 0.4 g/day) to control the disease in summer when lesions recurred. Another 8 patients were kept on maintenance during the low risk seasons and treated accordingly when the condition was exacerbated. The patient (no. 24) with longest follow-up period (10 years) had a fairly stable disease: prednisone 5 mg every 3 days or tetracycline 0.25 g/day could control and prevent acute attack with no medications in autumn and winter.

Two out of 24 patients experienced quick relapse (1 week and 2 weeks, respectively) after stopping treatment against our medical advice, but they responded promptly when the medications were resumed.

For all patients the oral medication was supplemented with topical treatment. After cleaning ulcers with 1:500 Povidone iodone, 0.5% nitrofurazone or 1% aureomycin ointment or vitamin E cream was applied until ulcer was healed.

Routine blood, liver and kidney functions tests were performed to monitor side effects of medications. In 2 patients leukopenia was present, and TG was thus stopped and ampeptide 0.6 g tid was added, which promotes proliferation, differentiation, maturation and release of blood cells. Its main therapeutic usage is to increase the levels of neutrophils and platelets. One week later complete blood count was normalised. One patient developed abnormal liver function during treatment. With reduction

of the doses of dapsone and TG and administration of glycyrrhizinate 150 mg 3 times a day. Glycyrrhizinate is a Chinese herb medication extracted from liquorice root. It is used in hepatitis or other liver ailments to reduce liver enzyme and promote liver cell regeneration. The patient's liver function then returned to normal.

## DISCUSSION

Since French scholar Millian first described LV under the name "atrophy blanche en plaque", this condition has had many synonyms such as livedo reticularis with summer ulcerations, livedo reticularis with winter ulceration, segmental hyalinising vasculitis, livedo vasculitis, and atrophy blanche. These various terms connote that a vascular malfunction leads to clinical presentation of ulceration ending in stellate scars. More and more evidence support that this vascular malfunction is by large a procoagulant process.

Our study is one of few large clinical case studies on LV and the first to document in detail clinical features and treatment experiences in Asian cohorts. In our study (24 patients), 11 were tested positive for ACA and 6 patients positive for  $\beta$ 2GP1. This finding confirms previously published data (6, 10, 11), indicating that anti-phospholipid antibody plays an important role in the pathogenesis of LV. In addition, we noticed 2 unique clinical features of LV in Chinese patients. Firstly, the peak age incidence of LV in our study (14–20 years) was lower than that reported in English literature (30–60 years) (1). Secondly, there is high incidence of summer exacerbation (87.5% of our patients, 21/24). The first observation is congruent with the study by Huang & Qui (12) published in Chinese literature in 1988. In their study of 26 patients with LV, the mean age of disease onset was 30.8 years, and 80.7% of his patients were younger than 39 years. The reason for this age difference between Chinese and other ethnic groups is unclear at present. We surmise that the inciting factors for LV in our patients might be different. Significant summer exacerbation prompted us to perform anaphylactogen skin prick test to multivalent insect antigens which was found positive in 71.43% patients (10/14). On the other hand the incidence of varicosis in our patients was low: out of 24 patients only 3 showed very mild varicosis. It is possible that a hypersensitivity reaction to insect bites might be a risk factor in our cohorts while stasis is an exacerbating factor in other case studies of LV in which the peak age (30–60 years) was coincident with that of varicosis (1).

We encountered one patient (not included in this study) who presented with LV-like skin lesions in the atypical locations of the hands and fingers. He was initially misdiagnosed as LV and did not respond to our standard treatment regimen for LV. Further workup revealed that his disease fulfilled criteria of systemic lupus erythematosus. This case underscores the importance of

ruling out other etiologies before rendering diagnosis of idiopathic LV as treatment will be different.

Our treatment regimen proved to be very effective. We favour combination therapy because it enhances clinical response and reduces side effects. Although anticoagulant and profibrinolytic mediations are deemed first-line therapy (13), anti-inflammatory drugs, from our experiences, are necessary to control acute symptoms in a timely fashion and to prevent recurrence. In our study, a combination of corticosteroids, tetracycline, TG and pentoxifylline could control acute attack within 2 weeks. Once control of acute symptoms has been gained, the dosage of these drugs should be timely reduced to once every other day or even less. This treatment regimen often had to be maintained at a small dose for months or indefinitely to prevent recurrence.

When designing a drug regimen, considerations must be given to the stages of the disease, possible triggering or aggravating factors and patient's comorbidities. Steroids can be substituted with danazol if needed. For patients with anti-phospholipid antibodies aspirin are administered. One must pay attention to adverse reactions of medications. Routine complete blood examination, liver and kidney function tests should be performed before start of drugs to establish the baseline results. They are then regularly monitored during treatment: initially twice a month, then once a month, and eventually once every 2 months. It is equally important to educate patients to modify their life styles accordingly: avoiding vigorous exercise and prolonged standing, especially in high risk times such as summer.

There are some limitations of this study: due to financial constrain and availability of the tests, we did not perform genetic studies such as Factor V Leiden mutation, Factor II or MTHFR polymorphisms, which have been causally associated with LV in several papers (7, 13). Monitoring levels of ACA and anti- $\beta$ 2GP1 during acute and quiescent stages would be also an interesting study to conduct to see if they are related to the disease activity. The treatment study is an uncontrolled, retrospective trial of a mixture of drugs adhering to previous empiric results obtained in China. A prospective ran-

domised controlled study using these drugs would be desirable but was not considered possible.

*The authors declare no conflict of interest.*

## REFERENCES

1. Maessen-Visch MB, Koedam MI, Hamulyak K, Neumann HA. Atrophie blanche. *Int J Dermatol* 1999; 38: 161–172.
2. Lyde CB. Atrophie blanche: a review from the perspective of a 31 patient cohort. *Dermatol Ther* 2001; 14: 111–116.
3. Criado PR, Rivitti EA, Sotto MN, Freire de Carvalho J. Livedoid vasculopathy as a coagulation disorder. *Autoimmun Rev* 2011; 10: 353–360.
4. Di Giacomo TB, Hussein TP, Souza DG, Criado PR. Frequency of thrombophilia determinant factors in patients with livedoid vasculopathy and treatment with anticoagulant drugs: a prospective study. *J Eur Acad Dermatol Venereol* 2010; 24: 1340–1346.
5. Agirbasli M, Eren M, Eren F, Murphy SB, Serdar ZA, Seckin D, et al. Enhanced functional stability of plasminogen activator inhibitor-1 in patients with livedoid vasculopathy. *J Thromb Thrombolysis* 2011; 32: 59–63.
6. Hairston BR, Davis MDP, Pittelkow MR, Ahmed I. Livedoid vasculopathy: further evidence for procoagulant pathogenesis. *Arch Dermatol* 2006; 142: 1413–1418.
7. Kavala M, Kocaturk E, Zindanci I, Turkoglu Z, Altintas S. A case of livedoid vasculopathy associated with factor V Leiden mutation: successful treatment with oral warfarin. *J Dermatolog Treat* 2008; 19: 121–123.
8. Davis MD, Wysokinski WE. Ulceration caused by livedoid vasculopathy associated with a prothrombotic state: response to warfarin. *J Am Acad Dermatol* 2008; 58: 512–515.
9. Feng SY, Jin PY, Shao CG. The significance of anticardiolipin antibody and immunologic abnormality in livedoid vasculitis. *Int J Dermatol* 2011; 50: 21–23.
10. Acland KM, Darvay A, Wakelin SH, Russel-Jones R. Livedoid vasculitis: a manifestation of the antiphospholipid syndrome? *Br J Dermatol* 1999; 140: 131–135.
11. Noda S, Asano Y, Yamazaki M, Ichimura Y, Tamaki Z, Takekoshi T, et al. Severe livedoid vasculopathy associated with antiphosphatidylserine-prothrombin complex antibody successfully treated with warfarin. *Arch Dermatol* 2011; 147: 621–623.
12. Huang ZJ, Qiu BZ. Analysis on 26 cases of segmental hyalinizing vasculitis. *Chinese J Dermatol* 1988; 21: 369–371.
13. Callen JP. Livedoid vasculopathy: what it is and how the patient should be evaluated and treated. *Arch Dermatol* 2006; 142: 1481–1482.