

## SHORT COMMUNICATION

## Fatal Case of Toxic Epidermal Necrolysis Caused by Cefozopran and Associated with Psoriasis

Yu Sawada, Rieko Kabashima-Kubo, Ryosuke Hino and Motonobu Nakamura

Department of Dermatology, University of Occupational and Environmental Health, 1-1 Iseigaoka, Yahatanishi-ku, Kitakyushu 807-8555, Japan. E-mail: long-ago@med.uoeh-u.ac.jp

Accepted May 29, 2013; Epub ahead of print Sep 17, 2013

Cefozopran is a fourth-generation cephem antibiotics and has a broad spectrum of antibacterial activity, inhibiting most of the gram-negative and gram-positive organisms and is used as an antibiotic agent for the empirical treatment of bacterial infections in febrile neutropenia patients (1). There have been several case reports of mild cutaneous side effects, such as exanthema, due to cefozopran, however, no severe drug eruption by cefozopran has been documented in English literature. Herein, we report the first case of toxic epidermal necrolysis (TEN) caused by cefozopran.

## CASE REPORT

A 71-year-old woman was referred to our department for evaluation of a generalised eruption. She had been treated for psoriasis with narrowband ultraviolet B light intermittently for 10 years. Because of pyelonephritis and septicaemia, she received cefozopran, which gradually improved her general condition. However, 7 days after intravenous administration of 1 mg cefozopran twice daily, she developed a widespread skin eruption accompanied with a high fever, 39°C. She had no medication other than cefozopran and no history of allergy to any medicine. On physical examination, erosions and scaly crusts spread widely on the chest (Fig. 1), back, and extremities involving more than 70% of body surface area. The oral mucosa was also affected and Nikolsky sign was positive. Laboratory examination revealed C-reactive protein 14.53 mg/dl (normal <0.2 mg/dl), fasting serum glucose 469 mg/dl (normal 126 mg/dl), blood urea nitrogen (BUN) 39 mg/dl (normal 8–22 mg/dl). Her SCORTEN score was 4 points (age >40 years, serum BUN >27 mg/dl, blistering body surface >10%, serum glucose >250 mg/dl). We performed lymphocyte stimulation test with cefozopran as described previously (2, 3). <sup>3</sup>H-thymidine incorporation was significantly increased by the addition of  $1.6 \times 10^{-7}$  M cefozopran (corresponding to  $C_{max}$  for intravenous dosing) to the peripheral lymphocyte culture with a stimulation index of 4.2 (Fig. 2). Three normal volunteers showed negative results. Histological evaluation was difficult for this patient because of the detached epidermis in skin biopsy specimen. The patient did not give consent to another biopsy, and direct immunofluorescence could not be performed. We diagnosed her eruption as TEN caused by cefozopran. Although

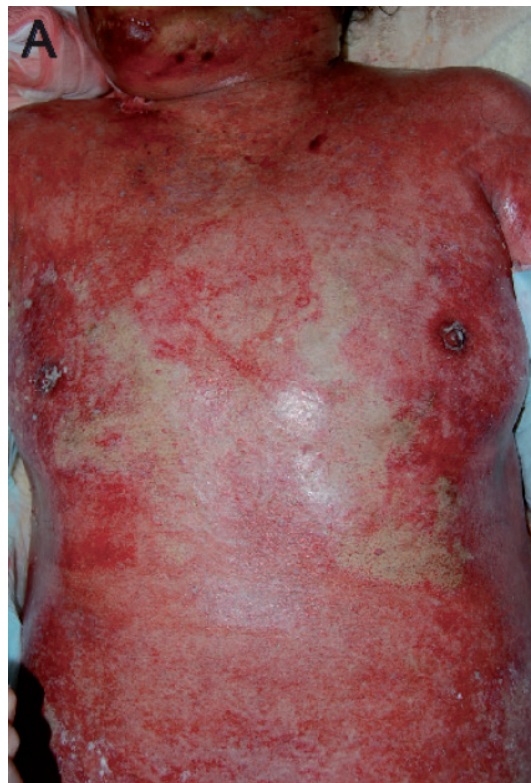

Fig. 1. Erosive and ulcerative lesions on the chest 7 days after starting cefozopran.

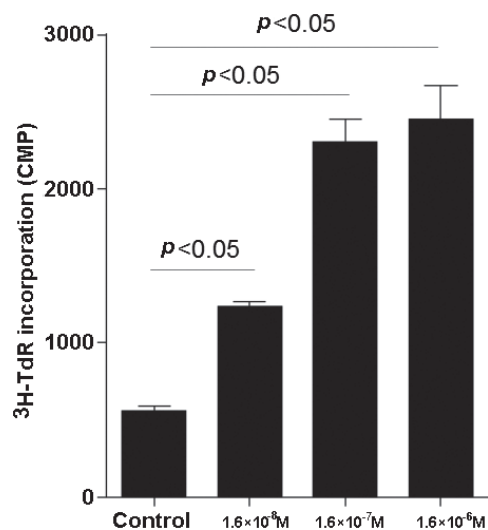


Fig. 2. The patient's peripheral blood mononuclear cells ( $2 \times 10^5$ /well) taken at the initial visit and were cultured for 72 h in a 96-well plate with cefozopran at 3 different concentrations.

high dose of immunoglobulin (1 g/kg/day) was administered intravenously, she developed overwhelming septicaemia and disseminated intravascular coagulation (DIC) resulting in death due to septic shock.

## DISCUSSION

TEN is one of the most severe blistering diseases. The pathophysiology is not well known, although immune mechanisms and altered drug metabolism have been postulated. Recently, the possible role of Th17 cells in pathogenesis of TEN was reported (4). Th17 cells might be involved in inflammation and tissue damage through regulation of the recruitment of neutrophils and other inflammatory leukocytes. Th17 cells also profoundly participate in the pathogenesis of psoriasis and patients with pustular psoriasis sometimes develop severe cutaneous side effects to drugs (5, 6). Although we could not estimate the Th17 frequency in peripheral blood in our patient due to DIC, the association of psoriasis and possible Th17 elevation might underlie the pathomechanism of a rare severe TEN caused by cefozopran in this case.

## REFERENCES

1. Klein O, Chin NX, Huang HB, Neu HC. In vitro activity of SCE-2787, a new cephalosporin with potent activity against *Pseudomonas aeruginosa* and members of the family Enterobacteriaceae. *Antimicrob Agents Chemother* 1994; 38: 2896–2901.
2. Sawada Y, Nakamura M, Tokura Y. Generalized fixed drug eruption caused by pazufloxacin. *Acta Derm Venereol* 2011; 91: 600–601.
3. Sawada Y, Yoshiki R, Kawakami C, Fukamachi S, Sugita K, Nakamura M, et al. Valsartan-induced drug eruption followed by CD30+ pseudolymphomatous eruption. *Acta Derm Venereol* 2010; 90: 521–522.
4. Teraki Y, Kawabe M, Izaki S. Possible role of T(H)17 cells in the pathogenesis of Stevens-Johnson syndrome and toxic epidermal necrolysis. *J Allergy Clin Immunol* 2013; 131: 907–909.
5. Rogers SC, McKee PH. Toxic epidermal necrolysis in two patients with pustular psoriasis. *Br J Dermatol* 1977; 96: 323–326.
6. Sawada Y, Kawakami C, Nakamura M, Tokura Y, Hino R. Toxic epidermal necrosis-like dermatosis induced by the first course of methotrexate. *Eur J Dermatol* 2009; 19: 397–398.