

## SHORT COMMUNICATION

### Digital Vasculitis with Eosinophilia Possibly Associated with Etanercept Therapy

Kyoko Nakahigashi, Gyohei Egawa, Yoshiki Miyachi and Kenji Kabashima\*

Department of Dermatology, Kyoto University Graduate School of Medicine, 54, Kawahara-cho, Shogoin, Sakyo-ku, Kyoto 606-8507, Japan.

\*E-mail: kaba@kuhp.kyoto-u.ac.jp

Accepted Apr 8, 2013; Epub ahead of print Jul 4, 2013

A prospective study has reported that 7.6% of patients with rheumatoid arthritis (RA) exhibited eosinophilia (1), which may be caused by its disease activity or hypersensitivity to therapeutic reagents. Cutaneous vasculitis is also a rare complication of RA, whose clinical findings include cutaneous ulcers, petechiae or purpura, digital infarcts, and so on. The overall annual incidence of rheumatoid vasculitis is 1% (2). We report here a case of RA with massive eosinophilia and digital cutaneous vasculitis during etanercept treatment.

#### CASE REPORT

A 24-year-old woman presented with chilblain-like digital eruptions. Multiple painful erythema and purpura were observed on her fingers and toes (Fig. 1), which recurred repeatedly over the last 6 months, unrelated to the season of the year. The patient had had RA from the age of 16 years. She had been treated with prednisolone (5 mg/day) and methotrexate (6 mg/week) for the last 8 years, and with etanercept (25 or 50 mg/week) for the last 3 years. She had no history of atopic eczema, asthma, or rhinitis.

Laboratory investigations revealed prominent eosinophilia (59.8%,  $9.2 \times 10^9/l$ ) with normal serum levels of IgE. Serum interleukin (IL)-5 and eosinophil cationic protein levels were consistently extensively elevated (38.0 pg/ml; normal range  $<3.9$  pg/ml and  $>150$   $\mu\text{g/l}$ ; normal range  $<14.9$   $\mu\text{g/l}$ , respectively). Eosinophilia had been noted at least for the past 2 years and progressively became more severe. Rheumatoid factor, anti-cyclic citrullinated protein antibodies, and antinuclear antibodies were all positive (37.1 IU/ml; normal  $<11.7$  IU/ml, 186 titre; normal  $<4.3$ , and 160 titre;

normal  $<40$ , respectively), which had been stable over 3 years. The nucleolar patterns were homogeneous and speckled. Anti-Ro (SS-A), anti-Sm, and anti-neutrophil cytoplasmic antibodies were all negative. Serum complement levels were within normal limits.

A skin biopsy was taken from a recently developed eruption on her finger. The histological examination revealed perivascular infiltration of mononuclear cells throughout the dermis to subcutaneous tissues (Fig. 2a). Infiltrating cells included neutrophils, lymphocytes, and eosinophils (Fig. 2b). Necrotizing vasculitis with fibrinoid degeneration and leukocytoclasia were observed. A direct immunofluorescence study showed deposition of C3 in the small blood vessels (data not shown).

Based on the above findings, we diagnosed the patient as digital vasculitis with eosinophilia possibly associated with etanercept therapy. Although we strongly suspected that eosinophilia was due to the allergic reaction to etanercept, we continued the treatment because the symptoms of RA were sufficiently controlled. Increasing the dose of prednisolone (10 mg/day) gradually resolved the skin lesions and eosinophilia. During the following 2 years, eosinophilia and the chilblain-like digital eruptions were observed, with remissions and exacerbations in response to increases or decreases of the dose of prednisolone.

#### DISCUSSION

Eosinophilic vasculitis syndrome is a recently recognized entity that Chen et al. (3) first described in patients with connective tissue disease (CTD). This disorder is classified into 2 groups: (i) idiopathic eosinophilic vasculitis with peripheral blood eosinophilia charac-

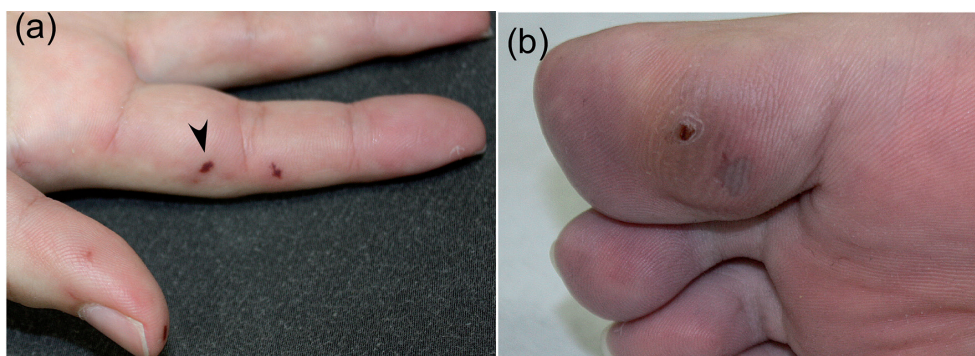


Fig. 1. Multiple erythema and purpura on the patient's (a) fingers and (b) toes.

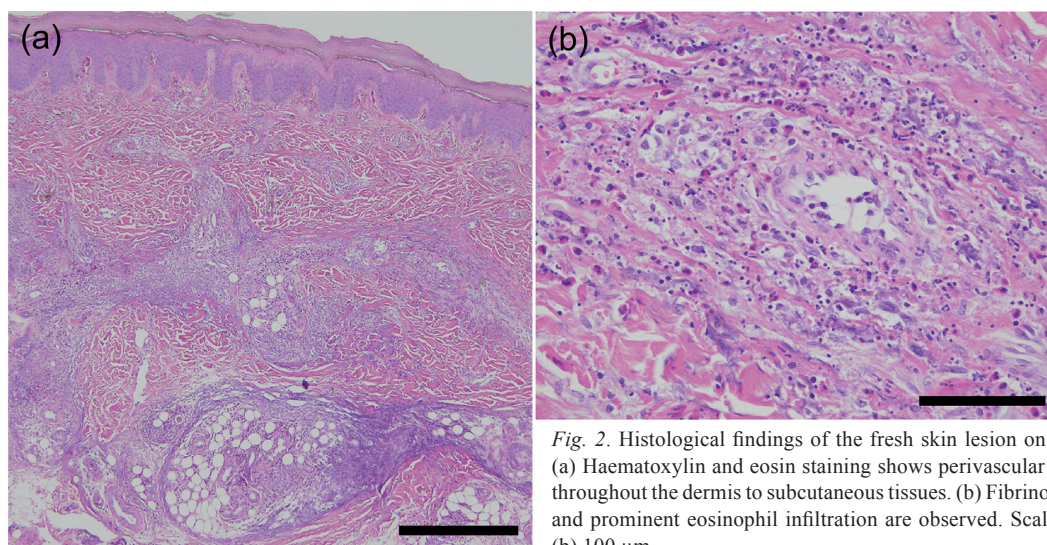


Fig. 2. Histological findings of the fresh skin lesion on the finger (arrowhead in Fig. 1). (a) Haematoxylin and eosin staining shows perivascular infiltration of mononuclear cells throughout the dermis to subcutaneous tissues. (b) Fibrinoid degeneration, leukocytoclasia, and prominent eosinophil infiltration are observed. Scale bars represent (a) 500  $\mu$ m and (b) 100  $\mu$ m.

terized by recurrent episodes of pruritic erythematous purpuric papules without significant immunoserological findings; and (ii) eosinophilic vasculitis associated with CTD. We supposed that the etanercept might be the main cause of eosinophilia in our case for the following 3 reasons: (i) eosinophilia is uncommon in patients with RA (1); (ii) eosinophilia developed 6 months after the initiation of etanercept therapy; and (iii) serological and physical examinations indicated that RA was in remission throughout the course.

Etanercept is an anti-tumour necrosis factor (TNF)- $\alpha$  drug for RA. A wide range of adverse cutaneous symptoms have been reported, including injection site reaction, discoid lupus, cutaneous vasculitis, new onset or exacerbation of psoriasis, and serious skin reactions, such as erythema multiforme, Stevens-Johnson syndrome, and toxic epidermal necrolysis (4). Ramos-Casals et al. (5) reported that 113 patients developed vasculitis after receiving anti-TNF- $\alpha$  agents (etanercept in 59 cases, infliximab in 47, adalimumab in 5, and other agents in 2). Although there were also some cases of chilblain lupus induced by TNF- $\alpha$  antagonists (6), our case was unlikely to be diagnosed as chilblain lupus, since anti-DNA and anti-Sm antibody were negative.

Meanwhile, there have been several reports representing eosinophilia associated with anti-TNF- $\alpha$  therapy, clinically represented as prurigo, eosinophilic cellulitis, eosinophilic fasciitis, and atopic eczema (7). To date, no cases of eosinophilic necrotizing vasculitis have been

reported, to the best of our knowledge. In conclusion, we report here a case of RA treated with etanercept, who represented massive eosinophilia and cutaneous digital eosinophilic necrotizing vasculitis, possibly related to etanercept treatment.

*The authors declare no conflicts of interest.*

## REFERENCES

1. Kargili A, Bavbek N, Kaya A, Koşar A, Karaaslan Y. Eosinophilia in rheumatologic diseases: a prospective study of 1000 cases. *Rheumatol Int* 2004; 24: 321–324.
2. Sayah A, English JC 3rd. Rheumatoid arthritis: a review of the cutaneous manifestations. *J Am Acad Dermatol* 2005; 53: 191–209; quiz 210–212.
3. Chen KR, Su WP, Pittelkow MR, Conn DL, George T, Leiferman KM. Eosinophilic vasculitis in connective tissue disease. *J Am Acad Dermatol* 1996; 35: 173–182.
4. Borrás-Blasco J, Navarro-Ruiz A, Borrás C, Casterá E. Adverse cutaneous reactions induced by TNF-alpha antagonist therapy. *South Med J* 2009; 102: 1133–1140.
5. Ramos-Casals M, Brito-Zerón P, Muñoz S, Soria N, Galiana D, Bertolaccini L, et al. Autoimmune diseases induced by TNF-targeted therapies: analysis of 233 cases. *Medicine (Baltimore)* 2007; 86: 242–251.
6. Sifuentes Giraldo WA, Ahijón Lana M, García Villanueva MJ, González García C, Vázquez Díaz M. Chilblain lupus induced by TNF- $\alpha$  antagonists: a case report and literature review. *Clin Rheumatol* 2012; 31: 563–568.
7. Bessissow T, Renard M, Hoffman I, Vermeire S, Rutgeerts P, Van Assche G. Review article: non-malignant haematological complications of anti-tumour necrosis factor alpha therapy. *Aliment Pharmacol Ther* 2012; 36: 312–323.