

## SHORT COMMUNICATION

### Alopecia Universalis Associated with Vitiligo in an 18-year-old HIV-positive Patient: Highly Active Anti-retroviral Therapy as First Choice Therapy?

Damjan S. Nikolic<sup>1</sup>, Daniela Viero<sup>1</sup>, Vanessa Christinet Yana Tijé<sup>2</sup> and Laurence Toutous-Trellu<sup>1,2</sup>

Departments of <sup>1</sup>Dermatology and Venereology, and <sup>2</sup>Infectious Diseases, University Hospital, Gabrielle-Perret-Gentil 4, CH-1211 Geneva 14, Switzerland. E-mail: damjan.nikolic@hcuge.ch

Accepted Apr 2, 2013; Epub ahead of print Jul 4, 2013

Many dermatological conditions have been described in HIV-infected patients, either in the context of an uncontrolled HIV infection or in the situation of highly active anti-retroviral therapy (HAART). Uncommon clinical associations and specific responses to antiviral treatments are still arising in this population. We describe here and discuss the evolution of an auto-immune dermatosis in the context of a chronic HIV infection.

#### CASE REPORT

An 18-year-old man of Togolese origin was hospitalized in our stationary unit in July 2007 in the context of unusual slow extension of skin lesions over the last 6 months. Blood tests at admission revealed leucopaenia 2.8 G/l (normal 4–10 G/l) with hypereosinophilia at 2.4 G/l, as well as a slight anaemia at 123 g/l (normal 140–180 g/l). HIV screening revealed a chronic HIV infection with a CD4 T cells count as low as 9 cells/mm<sup>3</sup> and a highly increased HIV viraemia, at 280,000 copies/ml. The HIV infection was probably acquired during early childhood via blood transfusion. The patient's general condition was good, and complete skin examination revealed diffuse alopecia (Fig. 1a), including the eyelids, as well as depigmented macules scattered throughout the whole skin, but mostly predominant on the legs, presenting as large depigmented macules (Fig. 2a). There was no superficial sensory loss on the depigmented lesions.

A diagnosis of alopecia universalis was made, with a suspicion of concomitant occurrence of vitiligo in association with uncontrolled HIV infection. Histological analysis from a depigmented macule showed melanocyte loss combined with a lichenoid dermo-epidermitis that was globally compatible with a vitiligo, but we could not completely rule out a potential associated drug-induced dermatitis. However, at that time the patient was not receiving any treatment. We therefore diagnosed concomitant occurrence of vitiligo and alopecia universalis in a deeply immunosuppressed HIV-positive patient. Because of the discovery of virological multiple anti-retroviral drug resistances, salvage HAART, including lopinavir, d4T, raltegravir

and subcutaneous enfurvitide injections, was introduced. Three months after HAART onset, a dramatic and complete response of the alopecia was observed (Fig. 1b), as well as progressive repigmentation of the depigmented macules starting from a perifollicular position (Fig. 2b). CD4 count had consistently increased up to 332 cells/mm<sup>3</sup> 6 months later, whereas HIV viraemia had dropped to less than 40 copies/ml. Since then, hair growth (Fig. 1b) and skin pigmentation were normal and HIV infection remained well controlled under a simplified HAART, associating zidovudine, lopinavir and raltegravir. The patient was subsequently lost to follow-up and developed Grave's disease in January 2010, 1 month after re-introduction of anti-retroviral therapy.

#### DISCUSSION

To our knowledge this is the first report of the concomitant occurrence of alopecia universalis and vitiligo in an

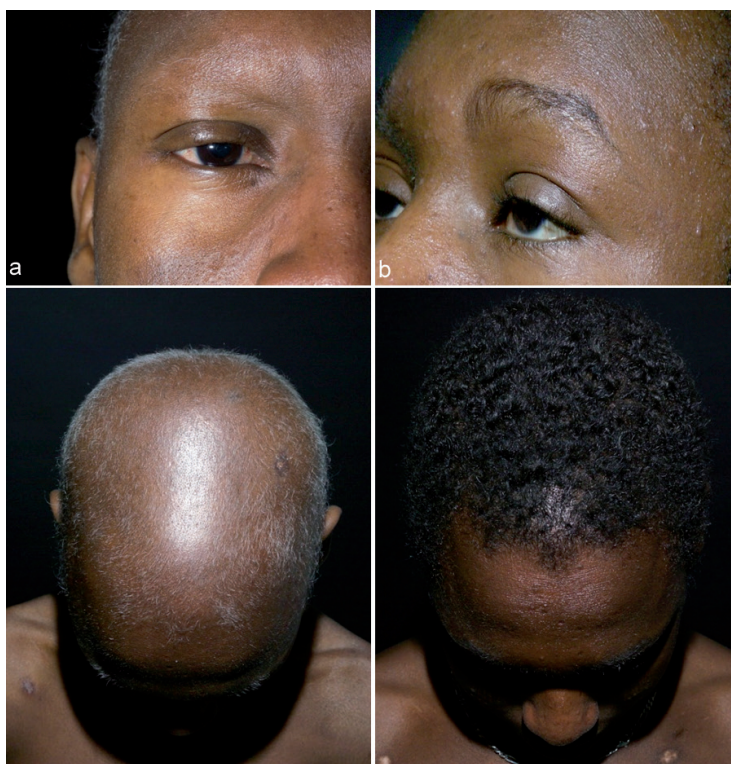

Fig. 1. Alopecia universalis (a) prior to, and (b) after, the introduction of highly active anti-retroviral therapy.

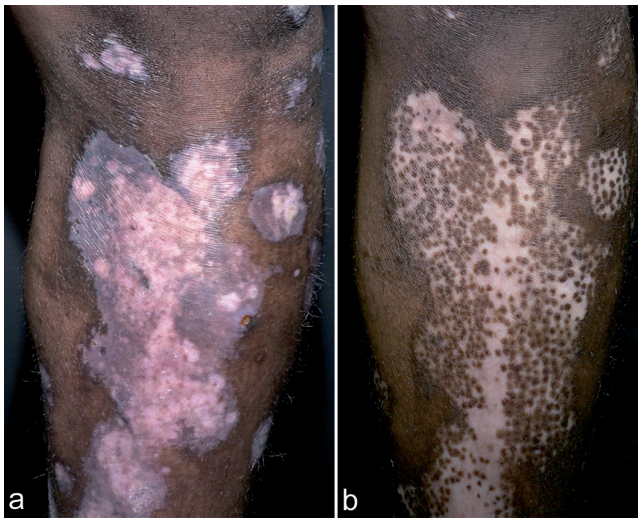


Fig. 2. Vitiligo lesions (a) prior to, and (b) after, the introduction of highly active anti-retroviral therapy.

HIV-infected patient with severe immunosuppression and complete healing during the first months of HAART initiation. Alopecia universalis in HIV-positive patients has already been reported (1), and reports linking vitiligo onset with recent HIV infection were made soon after HIV discovery (2). The concomitant presence of vitiligo and alopecia universalis in immunocompetent patients has been reported in a context of severe autoimmune disorders, such as the Vogt-Koyanagi-Harada syndrome (3), or the autoimmune polyglandular syndrome 3-C, which is usually associated with Hashimoto thyroiditis (4). Immune reconstitution inflammatory syndrome (IRIS) in HIV patients is a condition representing the paradoxical clinical deterioration of a known opportunistic infection or the occurrence of a new or latent disorder observed 3–6 months after the start of HAART (5). Skin involvement is frequent in this context and can reach up to 75% of the patients (5). Classical presentations include onset of various cutaneous infections, but appearance of eczema or acne has also been reported. Vitiligo and alopecia universalis have not classically been associated with skin manifestations of IRIS, although there is a report showing concomitant onset of alopecia universalis and Grave's disease in the context of HAART (6). On the other hand, there is no report of complete cure of vitiligo or alopecia universalis following HAART. Thus, our case demonstrates that auto-immune skin disorders arising in the context of massive immunosuppression can successfully disappear after restoration of adaptive immune function. Severely HIV-immunocompromised patients presenting auto-immune skin disorders should benefit from HAART in first intention and specific treatments reserved in case of non-response to HAART. Different mechanisms can be engaged following immune system restoration in the context of HAART.

Usually, 2–3 months after HAART onset, HIV viral load dramatically decreases, with a concomitant increase in peripheral CD4 T cells (7). CD8 T cells, NK cells and B cells are also increased during HAART, whereas plasma levels of pro-inflammatory cytokines, such as tumour necrosis factor-alpha, interleukin (IL)-1 and IL-6, are globally reduced. In counterpart, IRIS is classically accompanied by a dramatic increase in blood levels of pro-inflammatory cytokines (8). In our patient, HAART seems to have restored immune functions through restoration of an efficient pool of immune system cells. Thus, relatively low IL-4 levels in untreated patients, with subsequent restoration of IL-4 levels under HAART, have been demonstrated (9). Interestingly, another report describes low levels of IL-4 in the serum of a young woman presenting with alopecia universalis (10). Hence, auto-immune disorders in untreated HIV infection, or in the context of immune restoration under HAART, may emerge and heal.

## REFERENCES

1. Lafeuillade A, Quilichini R, Chaffanjon P, Dhiver C, Gastaut JA. Alopecia universalis in a homosexual man seropositive for the human immunodeficiency virus. *J Acquir Immune Defic Syndr* 1990; 3: 1019.
2. Duvic M, Rapini R, Hoots WK, Mansell PW. Human immunodeficiency-associated vitiligo: expression of autoimmunity with immunodeficiency? *J Am Acad Dermatol* 1987; 17: 656–662.
3. Jovic NS, Nesovic M, Vranjesevic DN, Ciric J, Marinkovic DM, Bonaci B. The Vogt-Koyanagi-Harada syndrome: association with autoimmune polyglandular syndrome type 1. *Postgrad Med J* 1996; 72: 495–497.
4. Turkoglu Z, Kavala M, Kolcak O, Zindanci I, Can B. Autoimmune polyglandular syndrome-3C in a child. *Dermatol Online J* 2010; 16: 8.
5. Osei-Sekyere B, Karstaedt AS. Immune reconstitution inflammatory syndrome involving the skin. *Clin Exp Dermatol* 2010; 35: 477–481.
6. Sereti I, Sarlis NJ, Arioglu E, Turner ML, Mican JM. Alopecia universalis and Graves' disease in the setting of immune restoration after highly active antiretroviral therapy. *AIDS* 2001; 15: 138–140.
7. Autran B, Carcelain G, Li TS, Blanc C, Mathez D, Tubiana R et al. Positive effects of combined antiretroviral therapy on CD4+ T cell homeostasis and function in advanced HIV disease. *Science* 1997; 27: 112–116.
8. Miralles P, Berenguer J, Lacruz C, Cosin J, López JC, Padilla B et al. Inflammatory reactions in progressive multifocal leukoencephalopathy after highly active antiretroviral therapy. *AIDS* 2001; 15: 1900–1902.
9. Sousa AE, Chaves AF, Doroana M, Antunes F, Victorino RM. Bulk cytokine production versus frequency of cytokine-producing cells in HIV1 infection before and during HAART. *Clin Immunol* 2000; 97: 162–170.
10. Tokura Y, Sugita K, Kabashima K, Ito T, Yagi H. Alopecia universalis associated with impaired interleukin-4 production and low serum IgE level. *J Am Acad Dermatol* 2007; 57: S22–S25.