

## SHORT COMMUNICATION

# Remission of Bullous Pemphigoid after Rituximab Treatment in a Psoriasis Patient on Regular Low-dose Methotrexate

Ting-Shun Wang and Tsen-Fang Tsai\*

Department of Dermatology, National Taiwan University Hospital, No. 7, Chun-Shan South Road, Taipei 100, Taiwan. \*E-mail: tftsai@yahoo.com  
Accepted Feb 21, 2013; Epub ahead of print Apr 29, 2013.

There is good evidence for the comorbidity of psoriasis and bullous pemphigoid (BP) since its first description in 1929 (1, 2). The onset of BP on top of psoriasis usually occurs after the administration of anthralin, coal tar, salicylic acid or phototherapy (3). Treatment of BP in psoriasis frequently poses a therapeutic dilemma, because the treatment of choice for BP is systemic corticosteroid, which is relatively contraindicated in psoriasis. We report here a patient with BP and psoriasis who achieved long-term remission of BP after 2 injections of rituximab, an anti-CD20 monoclonal antibody.

## CASE REPORT

An 83-year-old man presented with chronic plaque-type psoriasis, which had been well-controlled with topical treatment and ultraviolet B (UVB) phototherapy for over 10 years. He weighed 105 kg and could ambulate with assistance. In January 2005, some itching vesicles and urticarial plaques developed on his trunk and lower limbs over a period of 2 months. Skin biopsy revealed papillary dermal oedema with some perivascular infiltration of eosinophils. In addition, direct immunofluorescence revealed linear IgG and C3 deposition along the basement membrane (Fig. 1). Indirect immunofluorescence detected anti-basement membrane antibody at a titre of 1:20. A diagnosis of BP was then established. Initially, topical clobetasol propionate ointment and oral prednisolone (40 mg/day) were administered. The dosage of prednisolone was gradually tapered and eventually discontinued one year later. No new lesions were noted in the following 2 years. Methotrexate, 5 mg/week, was added from 2007 as a maintenance dose for psoriasis. In August 2008, the patient had another flare-up of BP, with numerous intense pruritic vesiculobullous eruptions on the extremities (Fig. 2). Due to the pre-existing skin atrophy and osteoporosis from his previous prednisolone use, he received 2 doses of rituximab 500 mg therapy weekly, together with a short course of oral prednisolone (20 mg daily for 2 weeks, then 30 mg every other

day for another 2 weeks). Concomitant methotrexate 7.5 mg weekly was given in the first 3 months and the dosage was then tapered to 5 mg weekly. No further vesicles occurred after 6 weeks, and the patient has remained free of BP for more than one year to date. No adverse events were experienced during rituximab treatment.

## DISCUSSION

Chronic disruption of the basement membrane layer in psoriasis may result in altered antigenicity and the subsequent production of autoantibodies (4). BP with psoriasis is typically associated with autoantibodies against type XVII collagen (Col17) (5). In addition, a novel 200-kDa protein (p-200) has been detected as another antigen for a subset of autoimmune subepidermal blistering diseases, which is often associated with psoriasis (6).

Systemic corticosteroid is usually the first-line treatment for BP. However, it is also known to trigger the development of erythrodermic or pustular psoriasis once discontinued. Rituximab is an anti-CD20 monoclonal antibody indicated for the treatment of rheumatoid arthritis and non-Hodgkin lymphoma. It is also increasingly used in the treatment of autoimmune bullous disorders, including BP and pemphigus (7). Thus, the use of rituximab in the treatment of BP in psoriasis is an attractive alternative. There are many papers on successful use of rituximab in patients with either psoriasis or psoriatic arthritis (8, 9). However, there is only one case report of the use of rituximab in the treatment of losartan-induced BP in a patient with psoriasis (10). In addition, there are reports of induced or aggravated psoriasis following the use of rituximab for other diseases

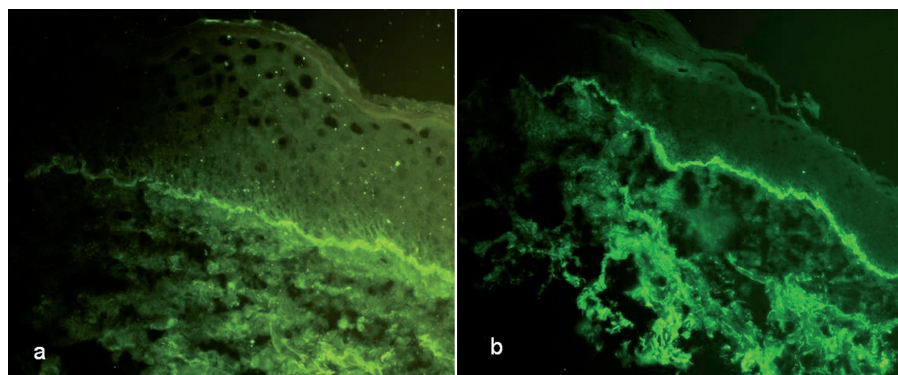


Fig. 1. (a) Linear IgG, and (b) C3 deposition along the basement membrane (a:  $\times 100$  and b:  $\times 40$ ).

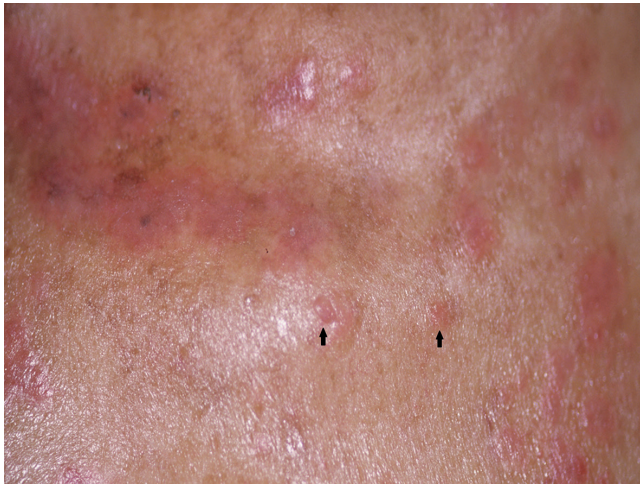

Fig. 2. Clear-fluid-containing, 1–1.5-cm, vesicles and well-defined erythematous scaly papules and plaques on the chest.

(11, 12). The paradoxical phenomenon of psoriasis exacerbation has also been reported for anti-tumour necrosis factors agents, which are well-recognized for their therapeutic benefits in psoriasis.

In addition to systemic prednisolone, BP can be treated with azathioprine or mycophenolate mofetil. However, both agents are used mainly as corticosteroid-sparing agents, and concomitant systemic corticosteroid is still needed, which might cause further skin atrophy and psoriasis aggravation following its discontinuation after prolonged use (13). Rituximab is mostly used on refractory BP, in particular mucous membrane pemphigoid (14). Although higher infectious complication may exist, compared with azathioprine and mycophenolate mofetil monotherapy most patients tolerated rituximab therapy well without increased risk of infections, cardiovascular events, malignancies or fatality over time (15). In addition, it has the added benefit of sustained clinical remission and reduced need for systemic prednisolone.

Although methotrexate has also been used for the treatment of BP, in our patient, methotrexate had been added for psoriasis control before the flare-up of BP. Thus, we believe that the clinical remission of BP was achieved mainly by rituximab. The use of methotrexate may have had only a minor additive role. In addition, oral prednisolone was tapered and discontinued in only one month, a much shorter time than the one-year course of oral prednisolone treatment in 2005.

Although the possible long-term side-effects and the high costs of rituximab compared with conventional treatment do not support its generalized use for BP, rituximab may offer a valuable therapeutic alternative for selected cases of BP, such as BP in psoriasis. Further large-scale study is needed to evaluate the efficacy and safety of rituximab in treating this group of patients.

## ACKNOWLEDGEMENTS

*Funding/support:* This study was sponsored by Centocor Research & Development, Inc., Malver, PA, USA.

*Financial disclosure:* T-FT has conducted clinical trials or received honoraria for serving as a consultant for Wyeth Pharmaceuticals (now Pfizer Pharmaceuticals), Serono International SA (now Merck Serono International), UniPharma/Biogen Idec, and Janssen-Cilag Pharmaceuticals and received speaking fees from Abbott. T-SW declares no conflict of interest.

## REFERENCES

- Bloom D. Psoriasis with superimposed bullous eruption. *Med J Rec* 1929; 130: 246.
- Tsai TF, Wang TS, Hung ST, Tsai PI, Schenkel B, Zhang M, et al. Epidemiology and comorbidities of psoriasis patients in a national database in Taiwan. *J Dermatol Sci* 2011; 63: 40–46.
- Koerber WA, Price NM, Watson W. Coexistent psoriasis and bullous pemphigoid. A report of six cases. *Arch Dermatol* 1978; 114: 1643–1646.
- Duong TA, Buffard V, André C, Ortonne N, Revuz J, Bagot M, et al. Efalizumab-induced bullous pemphigoid. *J Am Acad Dermatol* 2010; 62: 161–162.
- Yasuda H, Tomita Y, Shibaki A, Hashimoto T. Two cases of subepidermal blistering disease with anti-p200 or 180-kD bullous pemphigoid antigen associated with psoriasis. *Dermatology* 2004; 209: 149–155.
- Kawahara Y, Zillikens D, Yancey KB, Marinkovich MP, Nie Z, Hashimoto T, et al. Subepidermal blistering disease with autoantibodies against a novel dermal 200-kDa antigen. *J Dermatol Sci* 2000; 23: 93–102.
- Nigam R, Levitt J. Where does rituximab fit in the treatment of autoimmune mucocutaneous blistering skin disease? *J Drugs Dermatol* 2012; 11: 622–625.
- Chang YS, Lee HT, Chen WS, Hsiao KH, Chen MH, Tsai CY, et al. Treatment of psoriasis with rituximab. *J Am Acad Dermatol* 2012; 66: e184–e185.
- Jimenez-Boj E, Stamm TA, Sadlonova M, Rovinsky J, Rafayová H, Leeb B, et al. Rituximab in psoriatic arthritis: an exploratory evaluation. *Ann Rheum Dis* 2012; 71: 1868–1871.
- Saraceno R, Citarella L, Spallone G, Chimenti S. A biological approach in a patient with psoriasis and bullous pemphigoid associated with losartan therapy. *Clin Exp Dermatol* 2007; 33: 154–155.
- Olivieri I, D'Angelo S, Leccese P, Vertone D, Olivieri A. Worsening of psoriasis with rituximab therapy. *Clin Exp Rheumatol* 2010; 28: 926.
- Guidelli GM, Fioravanti A, Rubegni P, Feci L. Induced psoriasis after rituximab therapy for rheumatoid arthritis: a case report and review of the literature. *Rheumatol Int* 2013; 33: 2927–2930.
- Meurer M. Immunosuppressive therapy for autoimmune bullous diseases. *Clin Dermatol* 2012; 30: 78–83.
- Kasperkiewicz M, Shimanovich I, Ludwig RJ, Rose C, Zillikens D, Schmidt E. Rituximab for treatment-refractory pemphigus and pemphigoid: a case series of 17 patients. *J Am Acad Dermatol* 2011; 65: 552–558.
- Van Vollenhoven RF, Emery P, Bingham CO 3rd, Keystone EC, Fleischmann RM, Furst DE, et al. Long-term safety of rituximab in rheumatoid arthritis: 9.5-year follow-up of the global clinical trial programme with a focus on adverse events of interest in RA patients. *Ann Rheum Dis* 2013; 72: 1496–1502.