

QUIZ SECTION

Indurated Nodules Within a Tattoo: A Quiz

Karl K. Vance¹, Patricia M. Fishman², Sujata S. Gaitonde^{2,3} and Aleksandar L. Kronic¹Departments of ¹Dermatology, ²Pathology, and ³Hematology, University of Illinois, 808 S Wood St, #380, Chicago, IL 60610, USA. E-mail: kkvance@uic.edu

A 16-year-old African American male presented with an 18-month history of itchy growths within his professionally applied tattoos. The growths were limited to the red portions, and had developed a few months after the red ink was applied. His past medical and family histories were non-contributory. Physical examination revealed dark blue-black tattoos of lettering and flowers on the bilateral ventral forearms. Focally, on the red dyed areas, extremely indurated, exophytic, erythematous crusted nodules were noted (Fig. 1a). Biopsy sections demonstrated a dense, diffuse, band-like infiltrate of small lymphocytes in the upper dermis, admixed with numerous histiocytes and fewer eosinophils (Fig. 1b). Necrotic keratinocytes were focally evident at

the base of the epidermis. The reticular dermis showed an infiltrate of similar composition, with much less density, in a perivascular, peri-eccrine and focally interstitial distribution. Immunohistochemistry revealed a predominance of CD3⁺/CD4⁺ helper T cells, with fewer CD3⁺/CD8⁺ cytotoxic T cells and very few CD20 positive B cells (Fig. 2). CD163 highlighted numerous histiocytes.

What is your diagnosis? See next page for answer.

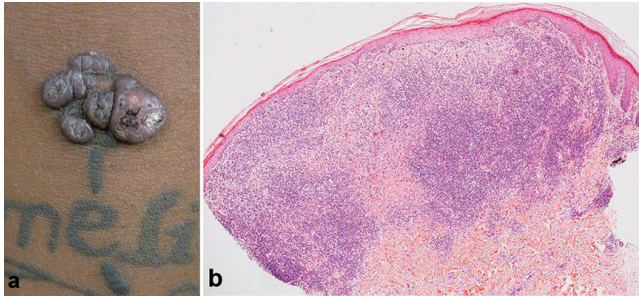


Fig. 1. (a) Indurated, erythematous, exophytic plaques within the red portion of professional tattoos on the right forearm. (b) Biopsy specimen from one of the nodules (H & E, original magnification $\times 20$).

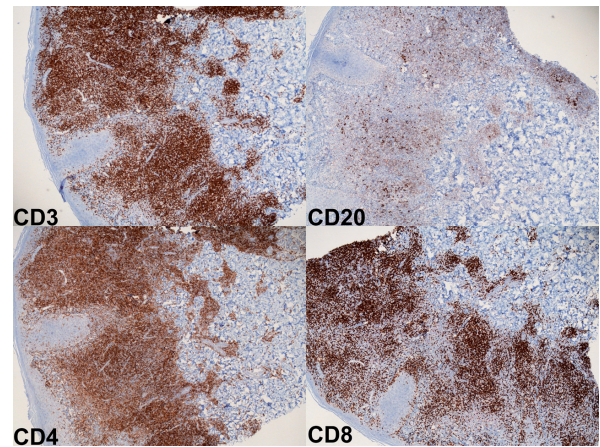


Fig. 2. Immunohistochemical stains for CD3, CD4, CD8 and CD20 (Immunohistochemical staining, magnification $\times 20$).

doi: 10.2340/00015555-1605

ANSWERS TO QUIZ

Indurated Nodules Within a Tattoo: A Comment

Diagnosis: Keloid-like pseudolymphomatous tattoo reaction

Acta Derm Venereol 2014; 94: 125–128

Pseudolymphomatous reaction is rarely reported in tattoos. More commonly seen complications are hypersensitivity reactions to tattoo pigments (1), including irritant and allergic contact dermatitis, photo-induced reactions, lichenoid reactions, granulomatous reactions, including sarcoidosis or foreign body reactions, as well as introduction of infection including bacterial, viral, mycobacterial and fungal (2). The Koebner phenomenon, as well as development of different neoplasia, has also been described in tattoos, including melanoma, basal cell carcinoma, squamous cell carcinoma, keratoacanthoma and dermatofibrosarcoma protuberans (1).

A cutaneous pseudolymphomatous reaction may be secondary to many different stimuli (medications, injected foreign substances, vaccinations, infections, arthropod assault, or photosensitivity) or may be completely idiopathic. Histologically, a superficial and deep nodular or diffuse infiltrate of polyclonal lymphocytes admixed with histiocytes and occasional plasma cells and eosinophils, is typically seen. Rarely, a band-like and perivascular dermal infiltrate, at times with epidermotropism may be seen, though epidermotropism is more typical for malignancy.

Pseudolymphomatous reaction typically appears from 6 months to 6 years after tattooing, and is most commonly seen as a reaction to red ink (cinnabar), though green and blue dyes have also been implicated (3–6). Treatment options include topical and intralesional corticosteroids, surgical excision or oral hydroxychloroquine (6). Laser therapy is not usually successful due to the incomplete removal of triggering pigment. Although pseudolymphomas may regress spontaneously, close follow-up is advised due to the rare potential for malignant transformation.

REFERENCES

1. Mataix J, Silvestre JF. Cutaneous adverse reactions to tattoos and piercings. *Actas Derosifilogr* 2009; 100: 643–656.
2. Desai NA, Smith ML. Body art in adolescents: paint, piercings and perils. *Adolesc Med State Art Rev* 2011; 22: 97–118.
3. Kahofer P, El Shabrawi-Caelen L, Horn M, Kern T, Smolle J. Pseudolymphoma in a tattoo. *Eur J Dermatol* 2003; 13: 209–212.
4. Kuo WE, Richwine EE, Sheehan DJ. Pseudolymphomatous and lichenoid reaction to a red tattoo: a case report. *Cutis* 2011; 87: 89–92.
5. Blumental G, Okun MR, Ponitch JA. Pseudolymphomatous reaction to tattoos. Report of three cases. *J Am Acad Dermatol* 1982; 4: 485–488.
6. Patrizi A, Roane B, Savoia F, Bacci F, Pileri A, Gurioli C, et al. Tattoo-associated pseudolymphomatous reaction and its successful treatment with hydroxychloroquine. *Acta Derm Venereol* 2009; 89: 327–328.