

## SHORT COMMUNICATION

## Diagnostic and Molecular Genetic Challenges in Male Incontinentia Pigmenti: A Case Report

Pernille A. Gregersen<sup>1</sup>, Mette Sommerlund<sup>2</sup>, Mette Ramsing<sup>3</sup>, Hans Gjørup<sup>4</sup>, Anders A. Rasmussen<sup>5</sup> and Anni Aggerholm<sup>1,6\*</sup>Departments of <sup>1</sup>Clinical Genetics, <sup>2</sup>Dermato-Venereology, <sup>3</sup>Pathology <sup>4</sup>Centre for Oral Health in Rare Diseases, and <sup>6</sup>Haematology, Aarhus University Hospital, Brendstrupgårdsvej 21C, DK-8200 Aarhus, and <sup>5</sup>Department of Clinical Genetics, Vejle Hospital, Vejle, Denmark. E-mail: anniagge@rm.dk

Accepted Jan 9, 2013; Epub ahead of print Apr 10, 2013

Incontinentia pigmenti (IP) is an X-linked, dominantly inherited, multisystem disorder affecting the skin and other sites, including the teeth, nails, hair, eyes and central nervous system. IP is predominantly seen in females, with few male cases described. It is caused by mutations in the *IKBK*G gene located on Xq28 (1). We describe a male patient with IP caused by post-zygotic mosaicism for the common deletion of the *IKBK*G gene. We delineate the diagnostic challenges, and emphasize the importance of early clinical recognition and diagnosis in order to initiate appropriate treatment and offer genetic counselling.

## CASE REPORT

A now 4-year-old boy was born after 41+1 weeks of pregnancy as the first child of healthy unrelated parents with no family history of skin disorders. His Apgar score was 10, weight 3,700 g, length 53 cm, and he had no apparent birth defects. Shortly after birth the parents noticed small blisters on the extremities. The blisters progressed and spread in a linear fashion during the following 3 weeks. At 20 days of age the boy was admitted to a paediatric department and treated with systemic and local antibiotics for suspected bullous impetigo. Leukocyte count and C-reactive protein was not raised. He was re-admitted shortly afterwards with the same clinical course. Treatment with different antibiotics had no effect. At day 30 the right wrist, dorsal aspect of the right hand and underarm, left leg, left and right knee were involved. At day 34, a dermatologist examined the boy and noticed vesicles and blisters and older lesions covered with crusts, following the lines of Blaschko, and suggested the diagnosis of IP. Later, linear erythematous skin lesions developed on the trunk. Hyperkeratotic, verrucous lesions developed on the extremities (Fig. 1a) and the penis. At

the age of 2 years, hyperpigmented linear lesions had evolved (Fig. 1b) and at 3 years, the linear skin hyperpigmentation was fading and hypopigmented atrophic lesions appeared (Fig. 1c). Skin lesions followed the classical 4 stages of IP: first the bullous or vesicular stage, followed by the verrucous stage, the hyperpigmented and, finally, the hypopigmented stage (2).

Dental examination at the age of 22 months, revealed the presence of 7 maxillary (3 molars, 2 canines, 2 incisors) and 6 mandibular (2 molars, 2 canines, 2 incisors) primary teeth. Incisors and canines were all peg-shaped (Fig. 1d). The surface of the enamel and colour of the teeth were normal. Dental X-rays indicated absence of 2 permanent incisors, both in the maxilla and in the mandible, but the total number of dental agenesis was not revealed. The morphology of the permanent incisors and canines was abnormal.

The boy is thriving and no increased frequency of infections has been observed. He has no developmental delay or seizures, and his hearing is normal.

Ophthalmic examination at the age of 3 months revealed strabismus. Re-examination at 2 years showed a malformation of the corpus vitreum of the left eye (persisting primary corpus vitreum). The boy is blind in the left eye.

Although the clinical presentation of skin suggested IP, the initial skin biopsy was not conclusive. The pathologist initially evaluating the biopsy suggested Franceschetti-Jadassohn's syndrome. Later, this biopsy, and a second skin biopsy at 9 months, examined by 2 dermato-pathologists, were suggestive of a dyskeratotic dermatosis without eosinophilia, but compatible with IP in the verrucous stage.

The clinical and histological suspicion of IP led to molecular genetic screening for mutations in the *IKBK*G gene. As the common delta*IKBK*G4–10 mutation is lethal to males, we initially performed mutation screening by bidirectional sequencing to search for hypomorphic mutations. No mutation was found in DNA extracted from peripheral blood.

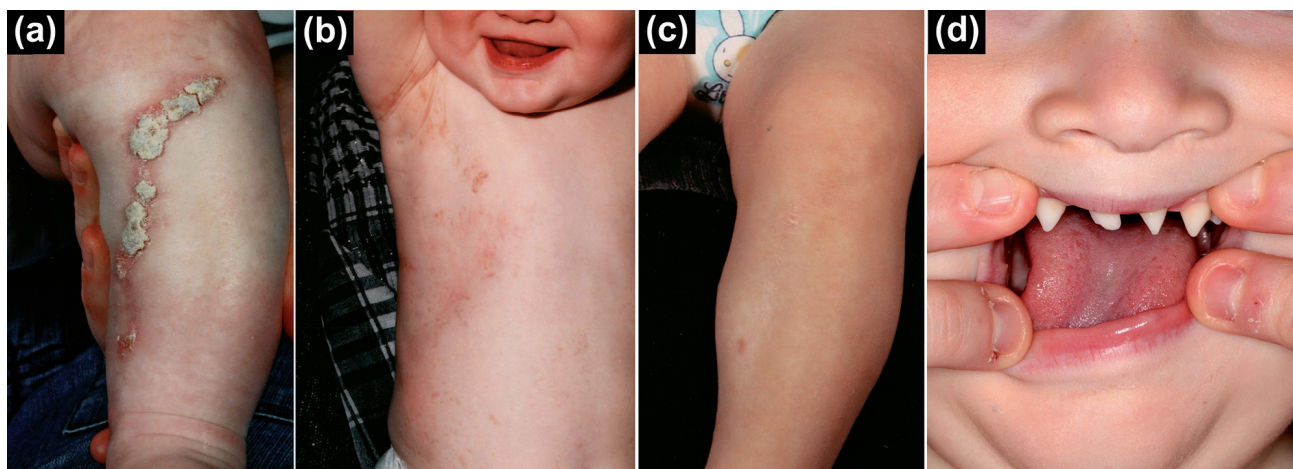


Fig. 1. Clinical presentation of the skin and teeth. (a) Hyperkeratotic, verrucous lesions at left leg, (b) hyperpigmented linear lesions at age 2 years, (c) hypopigmented, atrophic lesions at age 3 years, and (d) peg-shaped incisors and canines.

Karyotyping and fluorescence *in situ* hybridization (FISH) on leukocytes from peripheral blood showed normal male karyotype (46,XY). Array comparative genomic hybridization (Agilent, 180 kb) performed on DNA from peripheral blood revealed no abnormalities.

The mild, but typical, clinical symptoms of IP made us suggest mosaicism for the common deletion in the *IKBK*G gene. PCR was performed for detection of the delta*IKBK*G4–10 deletion (3), and the mutation as well as the normal gene was detected in peripheral blood from the patient. The deletion could not be confirmed by an in-house multiplex ligation-dependent probe amplification (MLPA) analysis designed for detection of deletions in the *IKBK*G gene and pseudogene (7 probes for *IKBK*G added to kit P096 from MRC-Holland). This indicates that the *IKBK*G deletion is only present in a very small fraction of cells.

To analyse whether the patient has a mosaic 46,XY/47,XXY karyotype, that is not evident by normal karyotyping and FISH on leukocytes from peripheral blood, DNA was extracted from paraffin-embedded tissue from affected skin. Semi-quantitative fluorescence PCR for 5 polymorphic short tandem repeat (STR) markers on the X chromosome and the non-polymorphic amelogenin marker on X and Y chromosomes was performed. No indication of an extra X chromosome was detected, as all X chromosome markers were hemizygous and the amelogenin marker showed equal amounts of X and Y chromosomes.

The initial analysis for the delta*IKBK*G4–10 deletion was performed on DNA isolated from the patient at age 9 months. We repeated the analysis on a blood sample from the patient at age 4 years. The deletion could still be detected. The patient's mother, who had no signs of IP, was also analysed for the delta*IKBK*G4–10 mutation. The mutation was not detected in her peripheral blood.

## DISCUSSION

We found somatic mosaicism for the common deletion of the *IKBK*G gene in a male patient. The deletion could be detected in blood cells drawn from the patient at the age of 9 months, when he had verrucous skin lesions. At the age of 4 years, the skin only presented with atrophic lesions and no inflammation, while the deletion was still present in the blood. This indicates selection against the mutation-bearing cells occurring in skin, but not in peripheral blood.

*IKBK*G gene disruption as causative of IP was first described in 2000 (1). Since then, 28 cases of sporadic male IP patients have been molecular genetically analysed (literature search criteria: incontinentia pigmenti, NEMO, male). Eight of these patients (including the patient presented here) had mosaicism of the common delta*IKBK*G4–10 deletion and one patient had Klinefelter syndrome and delta*IKBK*G4–10. For the remaining 19 patients no *IKBK*G mutations/deletions were observed (4–9).

Surviving male patients with familial IP, but without 47,XXY karyotype, have not been described in families with inactivating mutations disrupting *IKBK*G protein function (4). Affected males with hypomorphic mutations in *IKBK*G have been reported, but with clinical symptoms of hypohidrotic ectodermal dysplasia associated with severe immunodeficiency (10), i.e. clearly distinct from classical IP.

In sporadic male IP cases 2 mechanisms have been proposed for patients to survive deleterious mutations in the *IKBK*G gene; 47,XXY karyotype or post-zygotic mosaicism (4). That no molecular genetic diagnosis could be achieved in 19 of 28 reported male IP patients could be due to analysis of peripheral blood and not affected skin (11). Depending on at what stage during embryogenesis the mutation arose, tissues not derived from the ectodermal layer could be involved to a varying degree.

In conclusion, a diagnosis of IP should be considered in male patients with clinical signs of IP, despite the limited number of reported cases (a diagnostic algorithm is proposed in Fig. S1; available from: <http://www.medicaljournals.se/acta/content/?doi=10.2340/00015555-1593>). When no mutation is detected in blood, additional genetic analysis of affected tissue, achieved early in the cause of disease, before cells bearing the mutated gene are selectively eliminated, is consequently recommended.

*The authors declare no conflicts of interest.*

## REFERENCES

- Smahi A, Courtois G, Vabres P, Yamaoka S, Heurtz S, Munnich A, et al. Genomic rearrangement in NEMO impairs NF-kappaB activation and is a cause of incontinentia pigmenti. The International Incontinentia Pigmenti (IP) Consortium. *Nature* 2000; 405: 466–472.
- Landy SJ, Donnai D. Incontinentia pigmenti (Bloch-Sulzberger syndrome). *J Med Genet* 1993; 30: 53–59.
- Bararo T, Falco G, Sparago A, Mercadante V, Gean Molins E, Tarantino E, et al. Two cases of misinterpretation of molecular results in incontinentia pigmenti, and a PCR-based method to discriminate NEMO/IKKgamma gene deletion. *Hum Mutat* 2003; 21: 8–11.
- Kenwrick S, Woffendin H, Jakins T, Shuttleworth SG, Mayer E, Greenhalgh L, et al. Survival of male patients with incontinentia pigmenti carrying a lethal mutation can be explained by somatic mosaicism or Klinefelter syndrome. *Am J Hum Genet* 2001; 69: 1210–1217.
- Fusco F, Fimiani G, Tadini G, Michele D, Ursini MV. Clinical diagnosis of incontinentia pigmenti in a cohort of male patients. *J Am Acad Dermatol* 2007; 56: 264–267.
- Ardelean D, Pope E. Incontinentia pigmenti in boys: a series and review of the literature. *Pediatr Dermatol* 2006; 23: 523–527.
- DeVetten G, Ells A. Fluorescein angiographic findings in a male infant with incontinentia pigmenti. *J AAPOS* 2007; 11: 511–512.
- Zou CC, Zhao ZY. Clinical and molecular analysis of NF-kappaB essential modulator in Chinese incontinentia pigmenti patients. *Int J Dermatol* 2007; 46: 1017–1022.
- Li L, Song GW, DU JB, Liu JR, Xu FS, Liu XY, et al. NEMO Delta 4-10 deletion of NEMO gene in Chinese incontinentia pigmenti cases. *Zhonghua Er Ke Za Zhi* 2005; 43: 89–92.
- Doffinger R, Smahi A, Bessia C, Geissmann F, Feinberg J, Durandy A, et al. X-linked anhidrotic ectodermal dysplasia with immunodeficiency is caused by impaired NF-kappaB signaling. *Nat Genet* 2001; 27: 277–285.
- Scheuerle A, Ursini MV. Incontinentia pigmenti. In: Pagon RA, Bird TD, Dolan CR, Stephens K, Adam MP, editors. *GeneReviews*. Seattle (WA): University of Washington, Seattle, 1993.