

## SHORT COMMUNICATION

### Metastatic Melanoma with Leukaemia-like Evolution

Antoine Bertolotti<sup>1</sup>, H el ene Conte<sup>1</sup>, Emmanuelle Amazan<sup>1</sup>, Caroline Dutriaux<sup>1</sup>, Khaled Ezzedine<sup>1</sup>, Marie Parrens<sup>2</sup>, Beatrice Vergier<sup>2</sup>, Alain Taieb<sup>1</sup> and Thomas Jouary<sup>1\*</sup>

<sup>1</sup>Service de Dermatologie, H opital Saint Andr e, 1 rue Burguet, FR-33075 Bordeaux, and <sup>2</sup>Service d'Anatomopathologie, H opital Haut L ev eque, Pessac, France. \*E-mail: thomas.jouary@chu-bordeaux.fr

Accepted Dec 10, 2012; Epub ahead of print Mar 25, 2013

Melanoma is well-known for its aggressiveness, with rapid spreading of metastases and poor stage IV prognosis. We report here a case of a metastatic melanoma with super-acute dissemination and dramatic evolution.

#### CASE REPORT

A 52-year-old woman with no previous medical history presented with a tumour on her left forearm of 3 months' duration (Fig. 1A). Clinical examination revealed a 5 × 4 × 2-cm heterogeneous pigmented, bleeding erythematous tumour. An enlarged left axillar lymph node was present. Two biopsies were taken from the lesion and ulcerated melanoma was diagnosed, with a 4.8 mm-Breslow index, and positivity of MelanA, HMB45 and PS100 on immunohistochemistry. The BRAF mutation V600E was present. Computed tomography (CT) scan showed one left axillar and multiple lung metastases. Blood tests were normal. At that time, complete excision of the tumour was requested by the patient because of pain and bleeding. Two weeks after excision, the patient presented with dyspnoea. The blood test showed a non-regenerative anaemia (7 g/dl), thrombocytopenia (13 g/l), lactate dehydrogenase (LDH)=2,450 U/l, ferritin=2,540 µg/l, and triglyceride=2.21 mmol/l. The CT-scan with angiography showed multiple spleen infarctions without pulmonary embolism. The myelogram showed a bone-marrow necrosis (Fig. 1B). Blast-like atypical cells were isolated from the blood smear. Immunohistochemistry was positive for MelanA, HMB45 and PS100 staining, both on a pellet of cells isolated from centrifugation of a blood sample (Fig. 2) and on the bone-marrow biopsy (Fig. 1C). Lung, liver, bone-marrow and intra-vascular metastatic dissemination then

occurred from the patient's melanoma in less than one month. The patient died of multi-organ failure some days later without the opportunity to start anti-BRAF therapy.

#### DISCUSSION

Bone-marrow infiltration in melanoma is estimated at 7% of cases in alive patients, while post-mortem studies have found bone-marrow infiltrate in 45% of patients (1). Bone-marrow necrosis is usually induced by acute leukaemia and lymphoma. Anaemia is the most common haematological manifestation, followed by thrombocytopenia, pancytopenia and leukoerythroblastosis (2). In the latter article, diagnosis was confirmed by morphology and immunohistochemistry (2). Bhagwati et al. (3) described a melanoma with haemolytic anaemia by microangiopathy and intra-vascular dissemination, leading to the death of the patient in 3 weeks. In our case, no haematological criteria for microangiopathy were present, and the patient died from multi-organ failure by melanoma cell infiltration into the lung, bone-marrow and vessels.

The doubling time of a tumour can be estimated using the Ki-67 index. This proliferative index is estimated by immunochemistry staining on paraffin-embedded samples from primary tumour or metastasis. The proliferation Ki-67 marker is a nuclear antigen expressed in all active phases of the mitotic cell cycle (G1, S1, G2 and M phases), but not detected in the resting phase (G0). Quatresooz et al. (4) showed that the Ki-67 index of fast-growing and metastatic melanomas was particularly high. Various molecular techniques have been developed recently to detect circulating free melanoma cells or tumour-specific circulating cell-free DNA. The

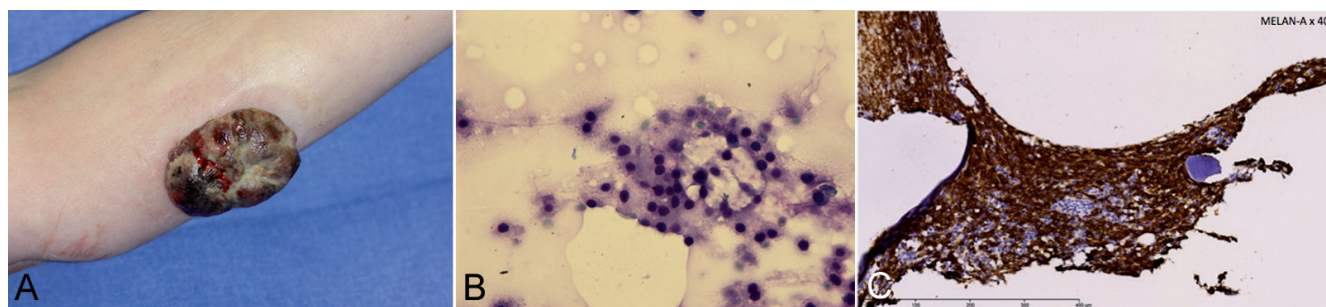


Fig. 1. (A) Large melanoma on the left forearm of the 52-year-old woman. (B) Bone-marrow necrosis observed on myelogram (HES × 100). (C) Bone-marrow infiltration by melanoma cells with positivity (Melan-A staining × 40).

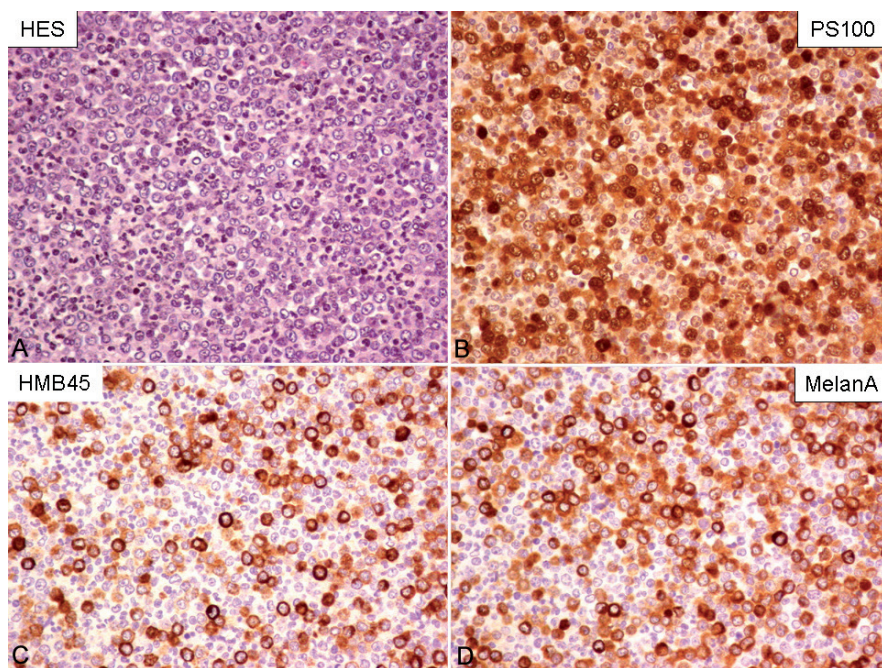


Fig. 2. Pellet of melanoma cells isolated by blood sample centrifugation with HES coloration (A), and PS100 (B), HMB45 (C) and MelanA (D) immunostaining (A–D  $\times 100$ ).

aim of these techniques is to predict clinical outcome of patients receiving target therapies or to detect early resistance to these therapies (5, 6). These prognostic markers are under investigation in the translational programmes of the target therapies trials in melanoma.

To the best of our knowledge, this is the first published case of a patient presenting with a super-acute melanoma with metastatic spread revealed on a blood smear with high density of circulating melanoma cells. This case demonstrated a very high doubling time of melanoma cells, as seen in leukaemia evolution, leading to the death of the patient < 4 months after the onset of the primary tumour.

## REFERENCES

1. Stewart WR, Gelberman RH, Harrelson JM, Seigler HF. Skeletal metastases of melanoma. *J Bone Joint Surg Am* 1978; 60: 645–649.

2. Jain D, Singh T, Kumar N, Daga MK. Metastatic malignant melanoma in bone marrow with occult primary site – a case report with review of literature. *Diagn Pathol* 2007; 2: 38.
3. Bhagwati N, Seno R, Dutcher JP, Oleksowicz L. Fulminant metastatic melanoma complicated by a microangiopathic hemolytic anemia. *Hematopathol Mol Hematol* 1998; 11: 101–108.
4. Quatresooz P, Pierard GE, Pierard-Franchimont C; Mosan Study group of pigmented tumors. Molecular pathways supporting the proliferation staging of malignant melanoma (review). *Int J Mol Med* 2009; 24: 295–301.
5. Shinozaki M, O'Day SJ, Kitago M, Amersi F, Kuo C, Kim J, Wang HJ, Hoon DS. Utility of circulating B-RAF DNA mutation in serum for monitoring melanoma patients receiving biochemotherapy. *Clin Cancer Res* 2007; 13: 2068–2074.
6. Palmer SR, Erickson LA, Ichetovkin I, Knauer DJ, Markovic SN. Circulating serologic and molecular biomarkers in malignant melanoma. Review. *Mayo Clin Proc* 2011; 86: 981–990.