

## SHORT COMMUNICATION

## Skin Discoloration Caused by Iron Salts

Iara Trocoli Drakensjö, Ingvar Lengstam and Mari-Anne Hedblad

*Dermatology and Venereology Unit, Department of Medicine Solna, Karolinska Institute, and Karolinska University Hospital Solna, SE-171 76 Stockholm, Sweden. E-mail: iara.rocha-trocoli-drakensjo@karolinska.se**Accepted Dec 11, 2012; Epub ahead of print Jul 1, 2013*

Monsel's solution (ferric subsulphate) is an iron salt first described in the literature in 1856 by Leon Monsel (1). Since then it has been widely used by dermatologists as a haemostatic agent in minor surgical procedures, such as tangential excision and punch biopsy (2). Ferric chloride is also a source of ferric ions, which is used in dermatological procedures and is considered more convenient because of its higher solubility compared with ferric subsulphate (1). It has been described previously that iron salts may produce hyperpigmentation of the skin (3). Microscopically, iron salts present as pigmented artefacts in the dermis with foreign-body reaction that may resemble malignant melanoma (3, 4). We describe here a case of extensive reddish-brown discoloration following topical application of ferric chloride solution after dermabrasion.

## CASE REPORT

A 66-year-old Caucasian woman was referred to the Department of Dermatology at Karolinska Hospital because of redness of the nose. Clinical examination showed telangiectasias and discrete sebaceous hyperplasia of the dorsum and lateral aspects of the nose. The clinical diagnosis was rosacea and early rhinophyma. The area was treated with dermabrasion, followed by the application of ferric chloride solution for haemostasis. Two weeks later the treated area presented with an intense reddish-brown discoloration with a sharp demarcation to untreated skin (Fig. 1). A punch biopsy from the periphery of the brownish area showed a band-like fibrosis in the papillary dermis with ferrugination

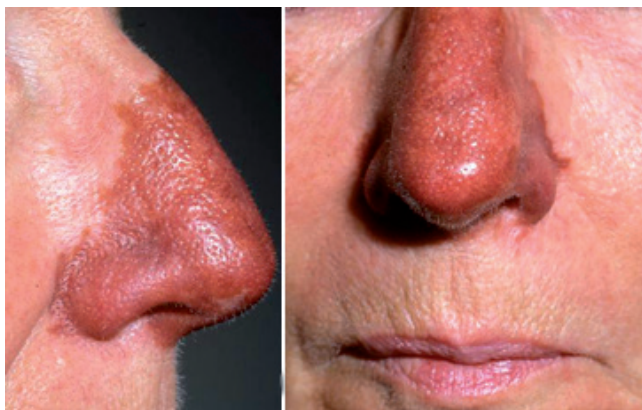

Fig. 1. Intense reddish-brown discoloration with sharp margins to healthy skin.

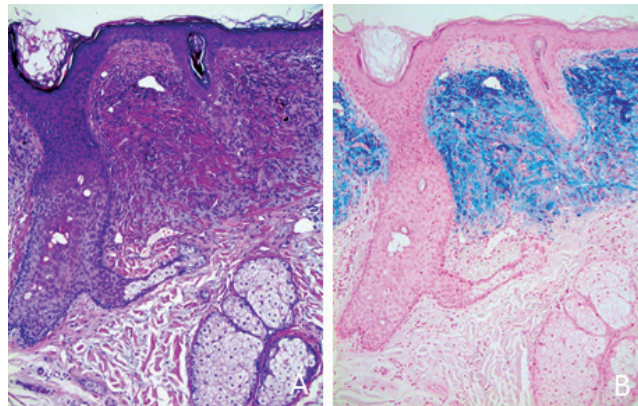


Fig. 2. (A) Band-like fibrosis in the papillary dermis with ferrugination of collagen bundles and siderophages (haematoxylin and eosin  $\times 100$ ). (B) Prussian blue staining ( $\times 100$ ) confirmed the presence of iron in the papillary dermis.

of collagen bundles and numerous siderophages (Fig. 2A). The presence of iron was confirmed by Prussian blue staining (Fig. 2B). A small test patch was then treated with carbon dioxide laser ( $\text{CO}_2$  laser) and showed no improvement regarding discoloration during the following months (Fig. 3). In an attempt to increase the cellular turnover of the skin, and thus enhance the wash-out of the pigment, adapalene 0.1% cream was applied on a regular basis. An almost complete clearance of the skin discoloration was achieved after twenty months.

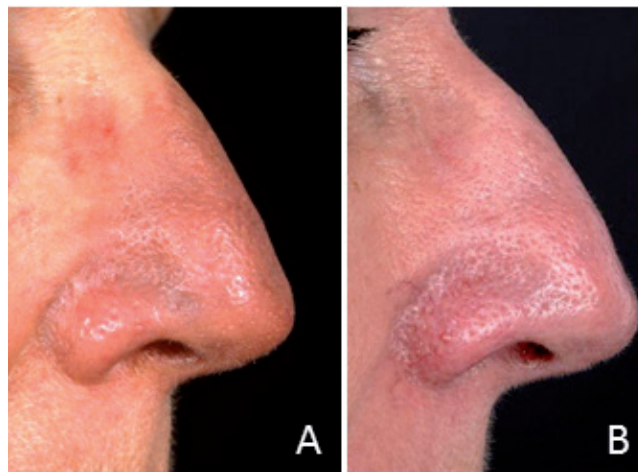

Fig. 3. Follow-up after treatment with adapalene at (A) 2 months and (B) 20 months.

## DISCUSSION

Iron salts (Monsel's solution and ferric chloride) have been widely used in dermatology because of their haemostatic properties. They heat and coagulate the proteins at a wound sealing small blood vessels (1). Amazon et al. (2) confirmed the ability of the Monsel's solution to produce ferrugination of collagen fibres and skeletal muscle when experimentally tested at biopsy sites in rabbits. In addition, these fibres may act as foreign bodies and induce a granulomatous reaction.

Olmstead et al. (3) described the use of Monsel's solution in diagnostic skin biopsies of 4 pigmented lesions, which were re-excised. The histological appearance of the tumours showed a microscopic pigmented artefact (Monsel's artefact) when stained with haematoxylin-eosin. The pigmentary alterations were brown discolourations with varied intensity with the pigment mainly distributed in macrophages, fibroblasts and collagen bundles. Degenerative changes, such as shrinkage and discolouration of collagen bundles, and reactive changes, such as fibrohistiocytic proliferations, were also described. Special stains (Prussian blue) for iron salts were used to determine the type of the pigment in order to establish a correct diagnosis.

Hanau et al. (5) also described a case in which iron sesquioxide was used in the treated area of a recurrent dermatofibrosarcoma protuberans, producing a brown discolouration at the scar site. A new excision was performed in order to discard a recurrence and the histopathology showed nodular scar tissue with ferrugination of the dermis and a macrophagic foreign-body reaction towards the brownish particles.

Wood & Severin (4) reported an unusual histiocytic reaction after the use of Monsel's solution at the biopsy site of a basal cell carcinoma. The re-excised specimen showed histiocytes with pronounced nuclear atypia and multinucleated giant cells that resembled a melanoma.

Our case presented similar histological features with ferrugination of collagen bundles and siderophages. The treatment with adapalene probably increased the transepidermal elimination of these collagen fibres, thus improving the aesthetic appearance (2, 4). Nevertheless, during this period the patient was emotionally distressed and dissatisfied with the cosmetic outcome.

We would like to emphasize that iron salts should be avoided in surgical procedures involving the face in general and are absolutely contraindicated in diagnostic procedures involving pigmented lesions. Moreover, the pathologist should be informed if iron salts were previously used, in order to avoid misinterpretation of the histopathological findings and choice of appropriate staining method.

## REFERENCES

1. Epstein E, Maibach HI. Monsel's solution. History, chemistry and efficacy. *Arch Dermatol* 1964; 90: 226–228.
2. Amazon K, Robinson MJ, Rywlin AM. Ferrugination caused by Monsel's solution. Clinical observations and experimentations. *Am J Dermatopathol* 1980; 2: 197–205.
3. Olmstead PM, Lund HZ, Leonard DD. Monsel's solution: a histologic nuisance. *J Am Acad Dermatol* 1980; 3: 492–498.
4. Wood C, Severin GL. Unusual histiocytic reaction to Monsel's solution. *Am J Dermatopathol* 1980; 2: 261–264.
5. Hanau D, Grosshans E. Monsel's solution and histological lesions. *Am J Dermatopathol* 1981; 3: 418–419.