

SHORT COMMUNICATION

Acquired Reactive Perforating Collagenosis: A Rare Association with Dermatomyositis

Nobuyuki Kikuchi, Mikio Ohtsuka and Toshiyuki Yamamoto

Department of Dermatology, Fukushima Medical University, Fukushima 960-1295, Japan. E-mail: nobuyuk@fmu.ac.jp

Accepted Nov 19, 2012; 2013 Epub ahead of print Mar 5, 2013

Acquired reactive perforating collagenosis (ARPC) presents with a number of umbilicated papules and nodules with central keratotic plugs on the trunk and extremities. Histopathology shows necrobiotic basophilic collagen bundles running transversely through the epidermis. ARPC is seen in association with various systemic disorders, in particular uncontrolled diabetes mellitus or renal failure (1). We describe here 2 patients with clinically amyopathic dermatomyositis, who developed ARPC on the back.

CASE REPORTS

Case 1

A 74-year-old woman visited our hospital, with itchy eruptions on her head and neck, trunk and extremities. Physical examination revealed erythema on the eyelids, forehead, and nasolabial areas (Fig. 1a). Coalescent erythema was found on the trunk and extremities. Nodular lesions with keratotic plugs were scattered on the lower back, which gradually worsened and increased in number (Fig. 1b). Electromyography of her biceps and quadriceps femoris showed no significant changes. Results of laboratory examination showed elevated creatine

kinase (CK) level (462 IU/l; normal <200 IU/l), aldolase level (9.3 U/l; normal <5.0 U/l), myoglobin (103.5 ng/ml; normal <60 ng/ml), C-reactive protein (CRP) and erythrocyte sedimentation rate (ESR) (33 mm/h). Renal function was normal. Antinuclear antibody and anti-Jo-1 antibody were within normal ranges, while anti-hepatitis C virus (HCV) antibody was detected. Blood glucose was 129 mg/dl (normal 70–109 mg/dl) and HbA1c was 5.8% (normal 4.3–5.8%). No lung fibrosis was revealed. A skin biopsy of a nodule showed a cup-shaped depression in the epidermis, and transepidermal elimination of basophilic collagen bundles, surrounded by a lymphocytic and neutrophilic infiltration (Fig. 1c). Elastica van Gieson staining revealed degenerated collagen fibres transversely eliminated through the epidermis (Fig. 1d).

Case 2

A 56-year-old woman with lung fibrosis was referred to our department for cutaneous manifestations. Physical examination showed eyelid erythema, mechanic's hand on the lateral aspects of the second fingers, and seborrhoeic dermatitis-like erythema on the face (Fig. 2a, b). Muscle weakness was not observed. Serum CK was normal, and abnormal laboratory data included increased levels of ESR (63 mm/h), AST (178 U/l; normal 13–33 U/l), ALT (86 U/l, 6–27 U/l), lactate dehydrogenase (LDH) (648 U/l, 119–229 U/l), and KL-6 (1,315 U/ml; <500 U/ml). Renal function was normal. Blood glucose was 101 mg/dl, and HbA1c (5.5%) were within upper limits. Antinuclear antibody and anti-Jo-1 antibody were within normal ranges, while anti-SS-A antibody was positive (49.0 U/ml, <7 U/ml). The patient reported having pruritus, and four weeks later several nodules, which increased in number, appeared on the lower back (Fig. 2c). Histological examination revealed transversely eliminated necrotic collagen bundles through a cup-shaped depression of epidermis (Fig. 2d).

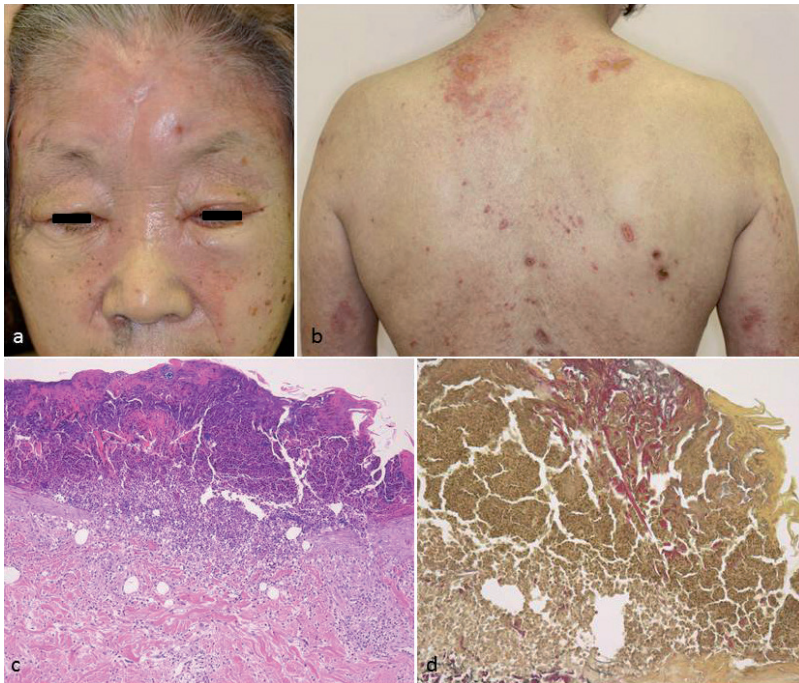


Fig. 1. (a) Seborrhoeic dermatitis-like facial erythema and upper eyelid oedema. (b) Scattered keratotic nodules on the back. (c) Histopathology of the hyperkeratotic nodule (H&E \times 100). (d) Elastica van Gieson stain reveals dermal collagen perforating through the epidermis (\times 200).

DISCUSSION

We describe here 2 cases of ARPC in patients with clinically amyopathic dermatomyositis. ARPC is triggered by minor trauma, such as folliculitis, arthropod bites, and scabies infection, in susceptible individuals. In particular, koebnerization seems to play an important role. Many patients with dermatomyositis have severe pruritus (2), which may disturb their quality of life. In the cases described here, systemic prednisolone had not yet been administered and the patients reported severe pruritus. Scrat-

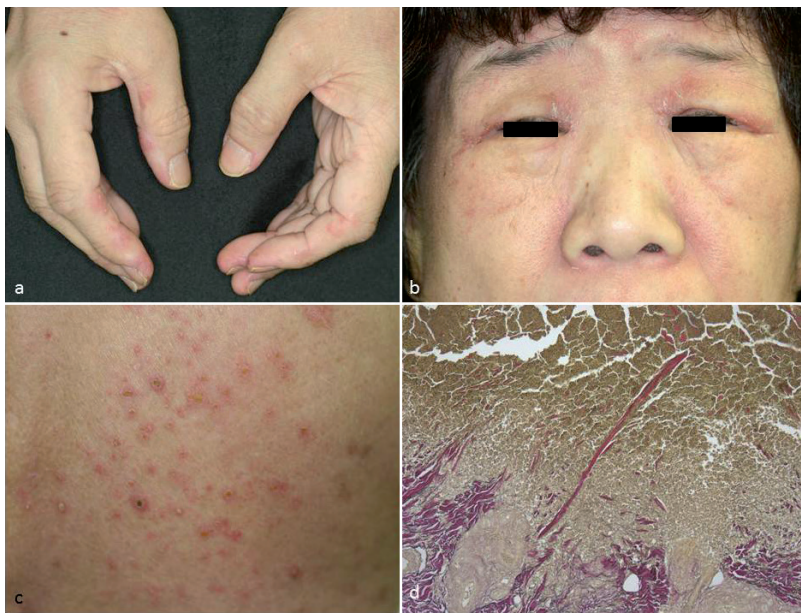

Fig. 2. (a) Keratotic erythema on the bilateral radial aspects of the fingers. (b) Facial erythema and heliotrope rash. (c) Multiple hyperkeratotic umbilicated nodules on the back. (d) Histopathology showing degenerated collagen bundles vertically eliminated through the epidermis (Elastica van Gieson stain) ($\times 400$).

ching may cause microtrauma and necrobiosis of the dermal structures. Follicular occlusion caused by altered differentiation of the epithelium may induce ARPC; however, it is rare for ARPC to occur in patients with dermatomyositis. Only one case of ARPC, occurring in a patient with dermatomyositis who had no diabetes, has been reported recently (3). In this case, nodular lesions developed within the poikiloderma, in parallel with relapse of myositis. The authors speculate that scratching due to severe itching and inadequate dermal circulation caused by interstitial oedema may induce ARPC. In our 2 cases, HbA1c levels were within the upper limits, but neither patient had uncontrolled diabetes or renal dysfunction. The other reported case (3) and our 2 cases were females, and systemic examination by computed tomography (CT), magnetic resonance imaging, Gallium scintigraphy, and positron emission tomography-CT did not reveal any internal malignancies.

The pathogenesis of ARPC is unknown. Overexpression of transforming growth factor-3 (TGF- β 3) has been shown around the cup-shaped epidermal depression in the lesion of ARPC (4). TGF- β plays a crucial role in connective tissue metabolism, and is involved in wound healing. TGF- β , matrix metalloproteinase-1 (MMP-1) and tissue inhibitor of metalloproteinase-1 (TIMP-1) immunoreactivity was significantly increased in the lesions of ARPC (5), suggesting that these factors may play an important role in the regulation of epidermal homeostasis, delay in re-epithelialization and remo-

delling, and alterations in extracellular matrix protein metabolism. Also, other studies suggest a correlation of serum TGF- β levels in dermatomyositis with the extent of microvascular injury and with the severity of lung fibrosis (6). Thus, although serum TGF- β levels were not examined in our cases, TGF- β in association with dermatomyositis may also be related to the induction of ARPC.

Case 1 was positive for HCV. HCV is associated with a variety of skin manifestations, including nodular prurigo (7), although the role is unknown. In a case series of acquired perforating dermatosis, anti-HCV antibody-positivity was observed in nearly 13% (8, 9). HCV infection may be relevant to the development of nodular lesions, i.e. ARPC.

In conclusion, ARPC may be one of the rare cutaneous lesions found in association with active dermatomyositis with pruritus.

The authors declare no conflicts of interest.

REFERENCES

1. Karpouzis A, Giatromanolaki A, Sivridis E, Kouskoukis C. Acquired reactive perforating collagenosis: current status. *J Dermatol* 2010; 37: 585–592.
2. Shirani Z, Kucenic MJ, Carroll CL, Fleischer AB Jr, Feldman SR, Yosipovitch G, et al. Pruritus in adult dermatomyositis. *Clin Exp Dermatol* 2004; 29: 273–276.
3. Amano H, Nagai Y, Kishi C, Ishikawa O. Acquired reactive perforating collagenosis in dermatomyositis. *J Dermatol* 2011; 38: 1199–1201.
4. Kawakami T, Soma Y, Mizoguchi M, Saito R. Immunohistochemical analysis of transforming growth factor-beta3 expression in acquired reactive perforating collagenosis. *Br J Dermatol* 2001; 144: 197–199.
5. Gambichler T, Birkner L, Stücker M, Othlinghaus N, Altmeyer P, Kreuter A. Up-regulation of transforming growth factor- β 3 and extracellular matrix proteins in acquired reactive perforating collagenosis. *J Am Acad Dermatol* 2009; 60: 463–469.
6. Funauchi M, Shimadsu H, Tamaki C, Yamagata T, Nozaki Y, Sugiyama M, et al. Role of endothelial damage in the pathogenesis of interstitial pneumonitis in patients with polymyositis and dermatomyositis. *J Rheumatol* 2006; 33: 903–906.
7. Yamamoto T, Yokoyama A. Hepatitis C virus and nodular prurigo. *Br J Dermatol* 1996; 135: 499.
8. Saray Y, Seçkin D, Bilezikçi B. Acquired perforating dermatosis: clinicopathological features in twenty-2 cases. *J Eur Acad Dermatol Venereol* 2006; 20: 679–688.
9. Satti MB, Aref AH, Raddadi AA, Al-Ghamdi FA. Acquired reactive perforating collagenosis: a clinicopathologic study of 15 cases from Saudi Arabia. *J Eur Acad Dermatol Venereol* 2010; 24: 223–227.