

## SHORT COMMUNICATION

## A Case of Tuberculous Cellulitis Lacking Epithelioid Granuloma

Shinichi Koba<sup>1</sup>, Takeshi Okawa<sup>1</sup>, Noriyuki Misago<sup>1</sup>, Asuka Yokoyama<sup>1</sup>, Yosuke Aoki<sup>2</sup>, Shigehisa Aoki<sup>3</sup> and Yutaka Narisawa<sup>1</sup><sup>1</sup>Division of Dermatology, Department of Internal Medicine, <sup>2</sup>Department of Pathology & Microbiology, Faculty of Medicine, Saga University, 5-1-1 Nabeshima, Saga, Saga, Japan, 849-8501, and <sup>3</sup>Division of Infection Control and Prevention, Saga University Hospital, Saga, Japan. E-mail: kobashi@cc.saga-u.ac.jp

Accepted Nov 5, 2012; Epub ahead of print Feb 28, 2013

Tuberculosis (TB) is globally more prevalent today than in any period in the past. Although the estimated number of deaths due to TB each year is 1.5–2 million, cutaneous TB accounts for a small percentage (< 1–2%) of all cases of TB. Cutaneous TB has a wide variety of clinical features, with increasing numbers of immunocompromised patients. Bullous pemphigoid, which was observed in the case described here, is a disease often seen in elderly people. Immunosuppressive treatment, such as systemic steroid therapy, is one of the standard treatments for bullous pemphigoid. In the present case, we considered whether systemic steroid therapy could induce cutaneous TB. Although cutaneous TB is divided into multibacillary and paucibacillary forms in the current classification, the clinical features of this case, such as cellulitis, did not fit into any forms. Moreover, although cutaneous TB is histologically characterized by epithelioid granuloma with caseous necrosis, epithelioid granuloma was not seen in this case. We draw attention here to the presence of atypical cutaneous TB that exhibits a clinical profile of cellulitis depending on the host condition.

## CASE REPORT

An 86-year-old man was admitted with a fever of around 39°C and an ill-defined, tender, erythematous, warm and swelling plaque in the left thigh (Fig. 1A). Five months earlier, he had been diagnosed with bullous pemphigoid and underwent pulse steroid therapy. One month after pulse steroid therapy for bullous pemphigoid, he developed unexplained nephritis

syndrome due to crescentic glomerulonephritis and underwent pulse steroid therapy again and subsequent oral prednisolone at a dosage of 20 mg/day. Whether he had a history of TB was unclear. On admission, no respiratory symptoms were noted and an initial chest X-ray did not show any specific evidence of tuberculosis. Laboratory studies revealed an elevated white blood cell count of 8,300 IU/l, C-reactive protein of 10.0 mg/dl, aspartate aminotransferase of 66 IU/l, alanine aminotransferase of 78 IU/l, total protein of 5.3 g/dl, albumin of 2.8 g/dl, blood urea nitrogen of 41.5 mg/dl, and creatinine of 2.15 mg/dl. He was diagnosed with cellulitis. Despite wide-spectrum antibiotic treatments (ampicillin/sulbactam and clindamycin), no response was observed.

Using subsequent investigation of histopathology, inflammatory cell infiltration, consisting mostly of neutrophils mixed with small numbers of lymphocytes, histiocytes, and eosinophils, was noted through the entire dermis and subcutis. However, no caseous necrosis or epithelioid cell granuloma was present (Fig. 1B and C). Periodic acid-Schiff (PAS) and Grocott stains were negative. Since Weber-Christian disease was a differential diagnosis, steroid pulse therapy was performed. However, an erythematous plaque gradually enlarged. One month after admission, a chest X-ray, performed to follow up thoracic effusion associated with nephritic syndrome, revealed a large number of nodular and granular shadows in both lung fields. Since chest X-ray suggested pulmonary tuberculosis, we examined the patient's sputum with Ziehl-Neelsen staining and observed a large number of acid-fast bacilli, which were identified as *Mycobacterium tuberculosis* complex by polymerase chain reaction (PCR) assay and culture.

At this point, since cutaneous TB was considered a possibility, past biopsy samples were examined by Ziehl-Neelsen staining (Fig. 1D). As a result, acid-fast bacilli were detected in the skin, but not in the kidney tissue sampled at the diagnosis of nephritic syndrome. In addition, the skin specimen was exami-

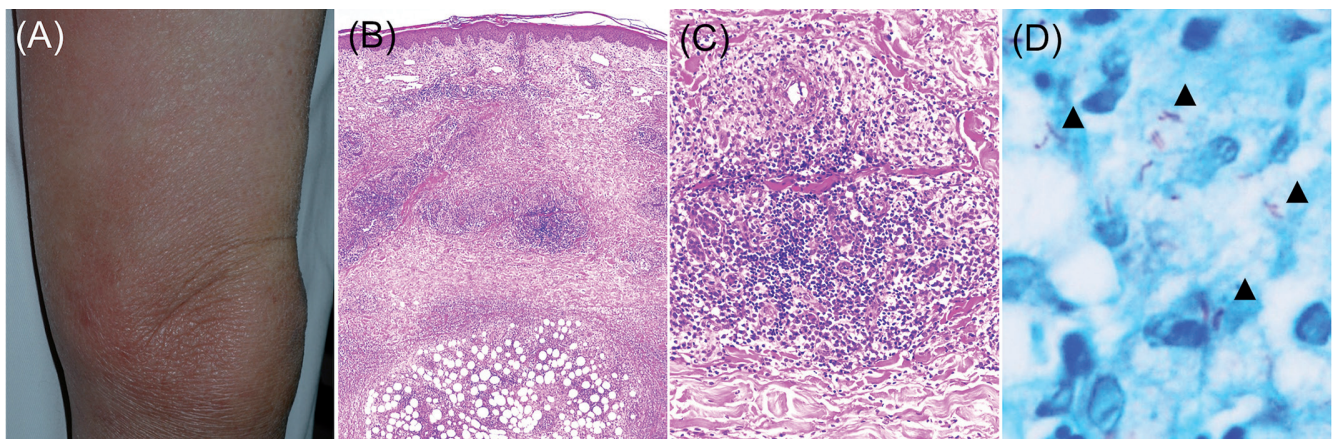


Fig. 1. (A) Clinical features of the medial side of the left femoral region before therapy. (B) Inflammatory cells infiltrated from the upper dermis to the subcutaneous tissue. (C) There was no caseous necrosis or epithelioid granuloma, but numerous neutrophils with a few lymphocytes, histiocytes and eosinophils. (D) Ziehl-Neelsen staining demonstrated acid-fast bacilli (arrowheads).

ned using PCR and culture, which revealed the presence of *M. tuberculosis*. The blood was not cultured for acid-fast bacilli, and the serum was negative for  $\beta$ -D glucan and *Candida* antigen.

On the basis of these findings, a diagnosis of tuberculous cellulitis with pulmonary miliary tuberculosis was made. However, although anti-tuberculous treatment was performed immediately, the patient died.

## DISCUSSION

The present case had a clinicohistopathological profile of cellulites due to common bacteria and lacked findings characteristic of cutaneous TB, such as epithelioid granuloma, caseous necrosis, and Langhans-type giant cells. Recently, with increasing numbers of immunocompromised patients, unusual presentations of tuberculosis may be observed more often. Since the reduction in immunocompetence due to steroid therapy may induce an atypical clinical presentation, such as cellulitis, it was difficult to make a diagnosis of tuberculous cellulitis. Several cases of tuberculous cellulites have been reported (1–5). Histopathologically, most cases showed epithelioid granuloma and/or caseous necrosis. Similar to our case, Kim et al. (5) reported a case of miliary tuberculosis that had been revealed approximately 3 weeks after the onset of tuberculous cellulitis without epithelial granuloma. Moreover, in immunocompromised hosts, tuberculous cellulitis occasionally shows a unique histological profile lacking

findings characteristic of cutaneous TB, such as epithelioid granuloma, caseous necrosis, and Langhans-type giant cells. In addition, particular attention must be paid to the history of TB in patients with this condition.

Cutaneous TB exhibiting atypical clinical and histological features, as in this case, often leads to an unfavourable course due to a delay in the diagnosis. We emphasize that tuberculous cellulitis not accompanied by epithelioid granuloma should be recognized as a clinical type of cutaneous TB.

*The authors declare no conflicts of interest.*

## REFERENCES

1. Rosenfeldt V, Jensen KE, Valerius NH. Tuberculous cellulitis in a child demonstrated by magnetic resonance imaging. *Scand J Infect Dis* 1999; 31: 417–419.
2. Seyahi N, Apaydin S, Kahveci A, Mert A, Sariyar M, Erek E. Cellulitis as a manifestation of miliary tuberculosis in a renal transplant recipient. *Transpl Infect Dis* 2005; 7: 80–85.
3. Bayazit YA, Ozer E, Kanlikama M, Mumbuc S, Bayazit N, Yilmaz M. Tuberculous deep neck infection in a soldier, preceding miliary tuberculosis: a diagnostic dilemma. *Mil Med* 2005; 170: 1066–1068.
4. Lee NH, Choi EH, Lee WS, Ahn SK. Tuberculous cellulitis. *Clin Exp Dermatol* 2000; 25: 222–223.
5. Kim JE, Ko JY, Bae SC, Ro YS. Tuberculous cellulitis as a manifestation of miliary tuberculosis in a patient with malignancy-associated dermatomyositis. *J Am Acad Dermatol* 2011; 65: 450–452.