

## Antisynthetase Syndrome: A Different Diagnosis to Dermatomyositis

Zsanett Csoma<sup>1</sup>, László Kovács<sup>2</sup>, Erika Varga<sup>1</sup>, Zsuzsanna Bata-Csörgő<sup>1</sup> and Lajos Kemény<sup>1</sup>

Departments of <sup>1</sup>Dermatology and Allergology, and <sup>2</sup>Rheumatology, University of Szeged, HU-6720 Szeged, Hungary. E-mail: csomazs@mail.derma.szote.u-szeged.hu

Accepted Sep 17, 2012; Epub ahead of print Dec 6, 2012

Antisynthetase syndrome (AS) is a rare systemic autoimmune disorder, classified among the idiopathic inflammatory myopathies. It has a generally poor prognosis, mainly due to irreversibly progressing pulmonary involvement. Skin symptoms are sometimes present, but are often mild and uncharacteristic. Early diagnosis followed by immunosuppressive therapy can significantly increase both the quality of life and life expectation of patients. We report here a case of a 48-year-old woman in whom an early diagnosis was made despite non-specific dermatological symptoms, which allowed the introduction of systemic therapy in the early stage of the disease.

### CASE REPORT

A 48-year-old woman presented at our General Dermatological Outpatient Unit in May 2011 with an intensive burning-tensing dermal pain localized to the upper extremities, décolleté, neck, face and knees, together with erythema and mild oedema. Apart from a several-year history of known photosensitivity, her medical history was unremarkable. Physical examination revealed red-to-violaceous discoloration and a marked telangiectatic character of sun-exposed skin areas (Fig. 1).

After a few days, she experienced severe and symmetrical pain and swelling of the small joints of the hands, wrists, elbows,

shoulders and knees, in addition to myalgia of the forearms. Extensive laboratory testing demonstrated a slightly elevated CK level (593 U/l) and strong anti-nuclear antigens (enzyme-linked immunoassay (ELISA) screening tests, Orgentec Diagnostika GmbH Mainz, Germany), anti-Sjögren antigen A (>200 U/ml), anti-Sjögren antigen B (>200 U/ml), anti-Jo-1 antibody (>200 U/ml) and rheumatoid factor (58.9 IU/ml) positivity. Other laboratory parameters were within normal levels. The symptoms and serological findings primarily supported the diagnosis of AS. In addition to symptom of Raynaud's phenomenon disease, physical examination revealed movement restriction, tenderness and swelling, mainly of the wrists and the proximal interphalangeal and metacarpophalangeal joints. On auscultation, diminished respiratory sounds were detectable over the right pulmonary base. High-resolution computed tomography (CT) of the thorax revealed a moderate dorsal sickle-shaped mixed ground-glass opacity, ranging from the middle third to the base of the right lung, interlobular septal thickening, intralobular fibrosis and a slight traction-type bronchiectasis. The latter morphological changes were characteristic of mixed alveolitis and interstitial fibrosis. Tumour screening revealed no pathological findings. A biopsy was taken from the skin of the upper arm and from the underlying deltoid muscle for histological examination (Fig. 1 C, D).

After diagnosis, pulse therapy with intravenous methylprednisolone (dose range 125–1,000 mg) and cyclophosphamide (dose range 600–1,000 mg; total administered dose: 4,300 mg) was initiated, followed by methylprednisolone maintenance therapy with a starting daily dose of 48 mg. In the course of the first cycle, 500 mg methylprednisolone was administered for 2 consecutive days, followed by a single dose of 700 mg cyclophosphamide on the third day. In the second cycle, the patient received 375 mg methylprednisolone, and the steroid dose was then reduced to 125 mg/cycle. The intravenous cyclophosphamide dose was 800 mg in the second cycle, 1,000 mg in the third cycle, and 600 mg/cycle subsequently. To date, the 6 cycles of immunosuppressive therapy have resulted in significant improvements in both the articular and the muscular symptoms.

The patient's obstetric history is noteworthy, with 5 pregnancies. The first pregnancy resulted in the birth of a normal male infant in the 40<sup>th</sup> gestational week in 1983; the second in the birth of an extremely premature female neonate with a birth weight of 600 g (24<sup>th</sup> gestational week), who died at the age of 2 days; the third in the birth of a male infant with mitochondrial encephalomyopathy (NADH-CoA-oxidoreductase deficiency) in the 40<sup>th</sup> gestational week in 1990; and the fourth in 2003 in the birth of a male infant with congenital vitia (aortic coarctation and patent ductus arteriosus) and multiple developmental abnormalities, who died at the age of 8 months. A further pregnancy ended in spontaneous abortion. No evidence of anti-phospholipid syndrome was found.

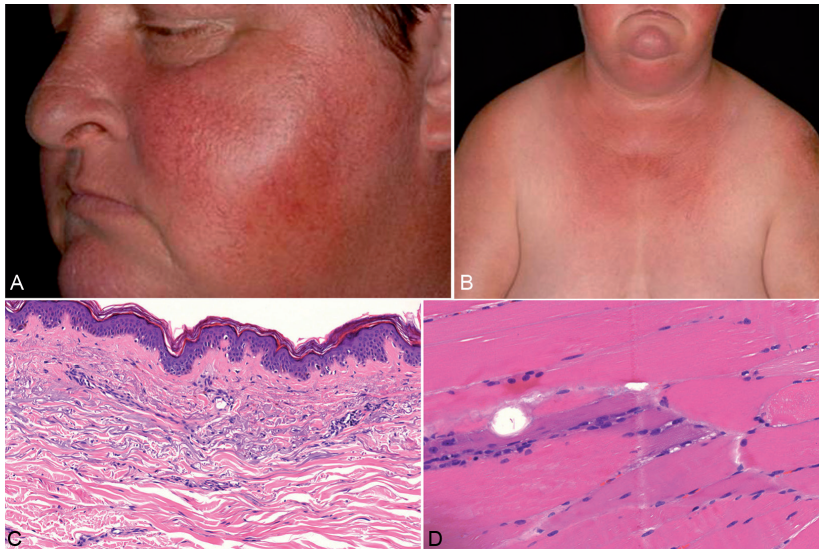


Fig. 1. (A, B) Red-to-violaceous discoloration and a marked telangiectatic character of sun-exposed skin areas. Permission to publish this photo is given from the patient. (C) Histological examination of a skin biopsy specimen demonstrated mild epidermal atrophy and elastic degeneration and minimal pigment incontinence in the upper layers of the dermis, accompanied by a mild perivascular lymphocytic infiltration and the presence of a low amount of extracellular mucin (HE, original magnification approximately  $\times 40$ ). (D) The striated muscle biopsy specimen was characterized by increased variability of the muscle fibre diameter and the presence of a few degenerated or homogeneously staining fibres and nuclear internalization (HE, original magnification approximately  $\times 70$ ).

## DISCUSSION

AS is a serological subtype of idiopathic inflammatory myositis characterized by the production of antisynthetase antibodies and the development of dermatomyositis or polymyositis, symmetrical non-erosive arthritis or arthralgia, interstitial lung disease, mechanic's hand, fever, Raynaud's phenomenon, the shawl (or V) sign and photosensitivity, accompanied by some less frequent manifestations, such as cutaneous vasculitis, calcinosis cutis, periungual telangiectasia, sclerodactylia, glomerulonephritis, pulmonary hypertension, carditis and cardiomyopathy (1–6). The adverse clinical outcome, with relatively high morbidity and mortality rates compared with those of other forms of inflammatory myositis, is primarily due to irreversible damage of the lung parenchyma, manifested as interstitial lung disease (2, 3, 7–9).

As this is a rare condition, no controlled clinical trials have been performed for assessment of the different treatment options. Currently, the first-line therapy of the AS includes methylprednisolone at a starting daily dose of 1 mg per kg body weight. As second-line treatment, the administration of cyclophosphamide as pulse therapy, cyclosporin A, azathioprine, tacrolimus, mycophenolate mofetil, intravenous immunoglobulin, rituximab, anakinra and leflunomide can be considered (1–5, 8–10).

Only limited data are available on the possible impacts of AS on the outcome of pregnancy. In general, approximately 14% of idiopathic inflammatory myopathies affect women of reproductive age, and the presence of active signs significantly increases the risk of spontaneous abortion, intrauterine death or retardation, and premature birth (11–13). It is not known how long the appearance of myositis-specific and myositis-associated autoantibodies precedes the onset of clinical symptoms, or, in this particular case, whether the autoimmune disease might have affected the outcome of the patient's pregnancies. However, it is well known that autoantibodies are typically present in systemic lupus erythematosus many years before diagnosis of the disease (14).

The autoantibodies produced in different forms of myositis can be divided into myositis-specific and myositis-associated autoantibodies. A subgroup of myositis-specific autoantibodies consists of antibodies directed against aminoacyl tRNA synthetase, i.e. the antisynthetase antibodies. The most common type of antisynthetase antibodies is the anti-histidyl-tRNA synthetase (anti-Jo-1) antibody; nevertheless, a further 7, much less frequent antisynthetase antibodies have also been identified (anti-PL-7, anti-PL-12, anti-OJ, anti-EJ, anti-KS, anti-YRS and anti-ZO antibodies) (1, 4, 9, 14).

The most commonly detected type of myositis-associated antibodies in the AS is the anti-Ro/SSA antibody (4, 15). It has been demonstrated that the presence of antisynthetase antibodies is the strongest predictive factor for the development of interstitial lung disease in

idiopathic inflammatory myositis, and the coexistence of anti-Jo-1 and anti-Ro/SSA antibodies is associated with a more severe, rather therapy-resistant form of pulmonary involvement (as in the patient reported here) (2, 3, 7, 8, 10). Thus, early clinical diagnosis and timely aggressive immunosuppressive therapy is essential to prevent the development of severe respiratory failure and pulmonary hypertension in these patients (3, 7–9). In our patient, the lungs were recognized to be affected in an early, clinically asymptomatic phase, when spirometry revealed only a slightly decreased diffusion capacity and muscle biopsy indicated merely a mild degree of muscular degeneration.

## REFERENCES

- Solomon J, Swigris JJ, Brown KK. Myositis-related interstitial lung disease and antisynthetase syndrome. *J Bras Pneumol* 2011; 37: 100–109.
- Katzap E, Barilla-LaBarca ML, Marder G. Antisynthetase syndrome. *Curr Rheumatol Rep* 2011; 13: 175–181.
- Shinjo SK, Levy-Neto M. Anti-Jo-1 antisynthetase syndrome. *Rev Bras Reumatol* 2010; 50: 492–500.
- Yang CJ, Sheu CC, Ou TT, Hwang JJ, Huang MS. Combined lung fibrosis and 'mechanic's hand': a clinical diagnostic clue to amyopathic antisynthetase syndrome. *Respirology* 2008; 13: 611–614.
- Furlan A, Botsios C, Ruffatti A, Todesco S, Punzi L. Antisynthetase syndrome with refractory polyarthritis and fever successfully treated with the IL-1 receptor antagonist, anakinra: a case report. *Joint Bone Spine* 2008; 75: 366–367.
- Yazici Y, Kagen LJ. Clinical presentation of the idiopathic inflammatory myopathies. *Rheum Dis Clin North Am* 2002; 28: 823–832.
- La Corte R, Lo Mo NA, Locaputo A, Dolzani F, Trotta F. In patients with antisynthetase syndrome the occurrence of anti-Ro/SSA antibodies causes a more severe interstitial lung disease. *Autoimmunity* 2006; 39: 249–253.
- Vancsa A, Csipo I, Nemeth J, Devenyi K, Gergely L, Danko K. Characteristics of interstitial lung disease in SS-A positive/Jo-1 positive inflammatory myopathy patients. *Rheumatol Int* 2009; 29: 989–994.
- Imbert-Masseau A, Hamidou M, Agard C, Grolleau JY, Cherin P. Antisynthetase syndrome. *Joint Bone Spine* 2003; 70: 161–168.
- Labirua A, Lundberg IE. Interstitial lung disease and idiopathic inflammatory myopathies: progress and pitfalls. *Curr Opin Rheumatol* 2010; 22: 633–638.
- Vancsa A, Ponyi A, Constantin T, Zeher M, Danko K. Pregnancy outcome in idiopathic inflammatory myopathy. *Rheumatol Int* 2007; 27: 435–439.
- Pasrija S, Rana R, Sardana K, Trivedi SS. A case of autoimmune myopathy in pregnancy. *Indian J Med Sci* 2005; 59: 109–112.
- Ishii N, Ono H, Kawaguchi T, Nakajima H. Dermatomyositis and pregnancy. Case report and review of the literature. *Dermatologica* 1991; 183: 146–149.
- Arbuckle MR, McClain MT, Rubertone MV, Scofield RH, Dennis GJ, James JA, et al. Development of autoantibodies before the clinical onset of systemic lupus erythematosus. *N Engl J Med* 2003; 349: 1526–1533.
- Ghirardello A, Zampieri S, Tarricone E, Iaccarino L, Bendo R, Briani C, et al. Clinical implications of autoantibody screening in patients with autoimmune myositis. *Autoimmunity* 2006; 39: 217–221.