

Successful Treatment with Alitretinoin of Dissecting Cellulitis of the Scalp in Keratitis-Ichthyosis-Deafness Syndrome

Sumangali Chandra Prasad and Anette Bygum

Department of Dermatology and Allergy Centre, Odense University Hospital, DK-5000 Odense C, Denmark. E-mail: sumangali@hotmail.co.uk

Accepted Sep 7, 2012; Epub ahead of print Nov 13, 2012

Keratitis-ichthyosis-deafness (KID) syndrome is a congenital disorder, which is associated with mutations in the *GJB2* gene encoding connexin 26 or in the closely related connexin 30 gene, *GJB6*. To date, approximately 100 cases have been described, mainly sporadic, but autosomal dominant inheritance has been reported in a small number of families. The syndrome is characterized by profound sensorineural hearing loss accompanied by vascularizing keratitis and erythrokeratoderma-like skin lesions. Palmoplantar hyperkeratosis, alopecia, dystrophic nails, and increased susceptibility to bacterial, viral and fungal infections and squamous cell carcinoma are other common features of this syndrome (1, 2). Treatment of patients with KID syndrome is difficult and often disappointing. Systemic retinoids, acitretin or isotretinoin have been used in patients with KID syndrome with variable success (3–6). We report here a case of KID syndrome where dissecting cellulitis of the scalp was treated successfully with alitretinoin.

CASE REPORT

A 15-year-old boy, born of non-consanguineous healthy parents, presented to our department in 2002 with a history of red and dry skin since birth, sensorineural deafness, red-brown hyperkeratotic plaques on his face and extremities, and sparse hair. Paronychia with nail dystrophy affected most of his fingers and all his toes. In 2003 he was the first Danish patient in whom KID syndrome was verified by mutation analysis, showing a heterozygous missense mutation D50N (148G >A) in *GJB2* (6).

The patient had a history of several unsuccessful treatments. Topical treatments with calcipotriol, corticosteroids and tar had been used with no effect. Pulsed dye laser had also been tried with no effect. Etretinate (Tigason, Betapharma, Shanghai) 10 mg per week was introduced when he was only one year of age.

He continued this treatment for 4 months with no effect. From the age of 5 to 7 years he was treated with acitretin (Neotigason, Actavis, UK) 10 mg daily, but had to stop the treatment because of erosive skin lesions in his auditory canals. In the following years, his skin lesions and nail surroundings had often been infected with dermatophytes, *Candida* and pyogenic bacteria, thus he needed frequent treatments with topical and systemic antibiotics and antimycotic drugs. At the age of 17 years, treatment with acitretin was resumed as he showed a follicular occlusion triad, with dissecting cellulitis of the scalp, cystic acne and hidradenitis in his axillary regions and groins. Acitretin 20 mg daily for 2 months did not alter his condition and a higher dose was not possible because of side-effects. As the treatment did not improve his condition, isotretinoin (Roaccutan, Roche, Switzerland) 20–30 mg daily in combination with prednisolone 25 mg daily were initiated and combined with dicloxacillin. In this period he was regularly examined by an ophthalmologist, to ensure that systemic retinoids did not provoke a keratitis or other ophthalmic side-effects. He had continuous painful dissecting cellulitis of his scalp (Fig. 1A) and was regularly receiving wound care in the outpatient clinic. A plastic surgeon was consulted, who considered transplantation of skin on his whole scalp. Photodynamic therapy was also tried with no effect. However, some improvement was seen after systemic treatment with clindamycin (Dalacin) and rifampicin (Rimactan) given for 3 months, followed by the antimycotic drug itraconazole (Sporanox). In 2009 the patient developed an ulcer on his left leg. The sudden onset of the ulcer and its slow healing resulted in several biopsies being taken from the ulcer in order to exclude malignant or premalignant changes. The hyperkeratotic plaques on his leg hampered healing of the ulcer, thus he resumed treatment with acitretin. Within 2 months acitretin was discontinued, because of aggravation in his skin condition. It was clear that the patient's condition would not improve with acitretin, thus alitretinoin (Toctino, Basilea, Switzerland) was considered. The ulcer continued for almost one year. Once the ulcer was healed, we decided to initiate alitretinoin off-label at an initial dose of 10 mg daily for 2 months, followed by a maintenance dose of 20 mg daily. Blood tests, including thyroxin (T4) and thyroid-stimulating

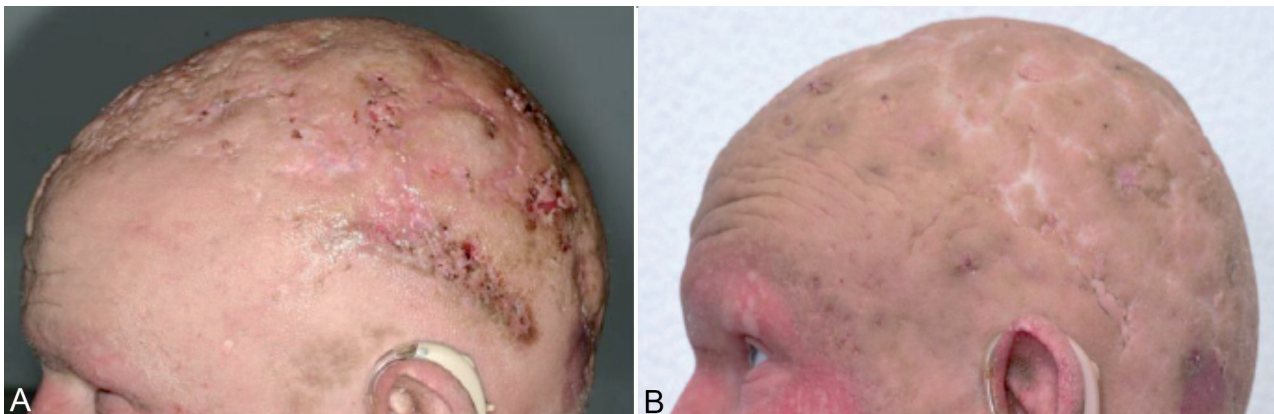


Fig. 1. Clinical images showing dissecting cellulitis of the scalp (A) before and (B) after treatment with alitretinoin 10–20 mg/day for 5 months.

hormone (TSH) levels, were taken before and during the therapy at regular intervals, with normal results. A significant improvement in all of his skin lesions was detectable after 5 months of therapy (Fig. 1B). The red-brown hyperkeratotic plaques on his face and extremities, dissecting cellulitis of the scalp and hidrosadenitis were significantly decreased, and a longstanding tendency to fissuring of his hands and feet stopped. During the course of treatment there were no detectable adverse effects, except a slight tendency to erosive skin lesions in his auditory canals. As the dose was reduced to 10 mg/day these symptoms subsided and treatment could be continued. The patient is still receiving treatment with alitretinoin, and currently he is less troubled by his skin symptoms. Only moisturizing ointment (Locobase), soothing baths with wheat-bran, and occasional potassium permanganate baths, are administered.

DISCUSSION

We describe here a case of KID syndrome showing a significant treatment response to low-dose alitretinoin. Patients with KID are often resistant to treatments, thus a variety of treatments may be tried, with variable and often limited success. Systemic retinoids interfere with the terminal differentiation of keratinocytes, and have been shown to be effective in many disorders of keratinization. However, the potential side-effects of systemic retinoids are of concern (4). Several case reports on the use of acitretin or isotretinoin, with variable results, have been published (3–6).

Retinoids regulate a variety of metabolic processes that promote cell growth and function, such as cellular differentiation, proliferation and apoptosis. Retinoids exert their effects on target cells by activating nuclear retinoid receptors. Alitretinoin is capable of binding to all known retinoic acid receptors (RARs) and retinoid X receptors (RXRs), in contrast to acitretin, which activates but does not bind to RARs, and isotretinoin, which shows low affinity for RARs. Alitretinoin is therefore expected to have more diverse effects in a different spectrum of diseases (7).

In most European countries alitretinoin is hitherto only legislated for chronic hand eczema (8). The effect of alitretinoin in KID syndrome has been published previously in only one case report (5). The patient in this case received alitretinoin 30 mg per day as a maintenance dose for 5 months, and during the course of treatment there were no detectable adverse effects. After 5 months of therapy the infiltrated erythema on the face had decreased, and the hyperkeratotic plaques had almost completely disappeared (5). In our patient the hyperkeratotic skin lesions were treated with topical moisturizers, keratolytic agents, potassium permanganate baths, and alitretinoin. Alitretinoin reduced the severity of the hyperkeratotic plaques during the first months of treatment, and had a positive effect on the dissecting cellulitis, and thus improved our patient's

quality of life. Our patient showed a significant improvement in his scalp and skin symptoms, which indicated that long-term continuous therapy with alitretinoin may be a possibility in patients with KID with severe dissecting cellulitis.

The prognosis of KID syndrome depends on early diagnosis of infections and skin cancers. These patients need lifelong follow-up for early diagnosis of malignant tumours, especially squamous cell carcinomas of the hyperkeratotic skin and mucosa (4, 6). Systemic retinoids reduce the hyperkeratosis and may reduce the incidence of skin cancer. We conclude that treatment with systemic alitretinoin may be an option for KID syndrome in cases complicated with follicular occlusion and dissecting cellulitis. Continuous monitoring for adverse effects remains essential, and more research into alitretinoin therapy is needed in order to determine the most effective dosage and the long-term safety of this medication in disorders of keratinization (9).

The authors declare no conflicts of interest.

REFERENCES

1. Koppelhus U, Tranebjaerg L, Esberg G, Ramsing M, Lodahl M, Rendtorff ND, et al. A novel mutation in the connexin 26 gene (GJB2) in a child with clinical and histological features of keratitis-ichthyosis-deafness (KID) syndrome. *Clin Exp Dermatol* 2010; 36: 142–148.
2. Maintz L, Betz RC, Allam JP, Wenzel J, Jaksche A, Friedrichs N, et al. Keratitis-ichthyosis-deafness syndrome in association with follicular occlusion triad. *Eur J Dermatol* 2005; 15: 347–352.
3. Bondeson M-L, Nyström A-M, Gunnarsson U, Vahlquist A. Connexin 26 (GJB2) mutations in two Swedish patients with atypical Vohwinkel (mutilating keratoderma plus deafness) and KID syndrome both extensively treated with acitretin. *Acta Derm Venereol* 2006; 86: 503–508.
4. Zhang X, He Y, Zhou H, Luo Q, Li C. Severe ichthyosis-related disorders in children: response to acitretin. *J Dermatol Treat* 2007; 18: 118–122.
5. Werchau S, Toberer F, Enk A, Helmbold P. Keratitis-ichthyosis-deafness syndrome: response to alitretinoin and review of literature. *Arch Dermatol* 2011; 147: 993–995.
6. Bygum A, Betz RC, Kragballe K, Steiniche T, Peeters N, Wuyts W, et al. KID syndrome: report of a Scandinavian patient with connexin-26 gene mutation. *Acta Derm Venereol* 2005; 85: 152–155.
7. Cheng C, Michaels J, Scheinfeld N. Alitretinoin: a comprehensive review. *Expert Opin Investig Drugs* 2008; 17: 437–443.
8. Ruzicka T, Lynde CW, Jemec GB, Diepgen T, Berth-Jones J, Coenraads PJ, et al. Efficacy and safety of oral alitretinoin (9-cis retinoic acid) in patients with severe chronic hand eczema refractory to topical corticosteroids: results of a randomized, double-blind, placebo-controlled, multicentre trial. *Br J Dermatol* 2008; 158: 808–817.
9. Gånemo A, Sommerlund M, Vahlquist A. Oral Alitretinoin in Congenital Ichthyosis: A Pilot Study Shows Variable Effects and a Risk of Central Hypothyroidism. *Acta Derm Venereol* 2012; 92: 256–257.