

Electron-microscopy of Cherry Haemangioma in the Early Diagnosis of Fabry Disease

Atsushi Tokuriki, Takahiro Kiyohara and Masanobu Kumakiri

Department of Dermatology, Faculty of Medical Sciences, University of Fukui, 23-3 Matsuoka-Shimoaizuki, Eiheiji, Fukui 910-1193, Japan. E-mail: tokuriki@u-fukui.ac.jp

Accepted Sep 3, 2012; Epub ahead of print Nov 7, 2012

Fabry disease (FD) is a chronically progressive, congenital metabolic disease. Deficiency of α -galactosidase A (α -gal A) results in the accumulation of glycosphingolipids in various types of cell. Most male patients with FD develop renal failure, cardiac and cerebrovascular disease, which are the major causes of morbidity and mortality, occurring in the fourth or fifth decade of life (1). Thus, it is important to diagnose and start to treat FD as promptly as possible (2). We describe here a patient with FD who presented with only a few red papules, pathologically consistent with cherry haemangioma.

CASE REPORT

A 27-year-old Japanese man presented with a few, solitary, 2–3-mm diameter, bright-red papules on the chest and left shoulder (Fig. 1A). His mother, a 52-year-old

Japanese woman, had been diagnosed with FD due to asymptomatic cardiomegaly detected during a regular medical check-up. This prompted her son also to undergo examination. A detailed medical history revealed that he had been aware of relatively mild numbness and tingling in his extremities, and oligohidrosis after strenuous exertion, since approximately 10 years of age. Histologically, the papules showed numerous moderately dilated vessels lined with flattened endothelial cells and pericytes in the subpapillary region, sparing the papillary dermis. The intervascular stroma showed homogenization of the collagen. The overlying epidermis was slightly thinned and there was no vessel invagination into the epidermis (Fig. 1B). We could recognize neither vacuolations nor toluidine blue-stained deposits in the cytoplasm of endothelial cells or sweat gland cells. We then performed electron-microscopy of the papules, demonstrating uneven dense and lamellar deposits in the cytoplasm of the endothelial cells and pericytes (Fig. 2). This finding is characteristic of lysosomal storage diseases, such as FD. Laboratory tests gave the following results; plasma α -gal A activity, 0.2 nmol/h/ml (normal 6.0–10.8 nmol/h/ml); urinary GL-3, 7.06 mg/mgCr (normal <0.26 mg/mgCr); urinary α -gal A protein, 11.2 ng/mgCr (normal >38.2 ng/mgCr). Finally, the patient was diagnosed with FD and has been receiving enzyme replacement therapy (agalsidase beta; 1 mg/kg) for nearly 3 years, given every other week, starting from 2 months after his initial consultation at our institution. To date, this therapy has prevented the disease from progressing and the patient has been able to carry out his normal activities of daily living.

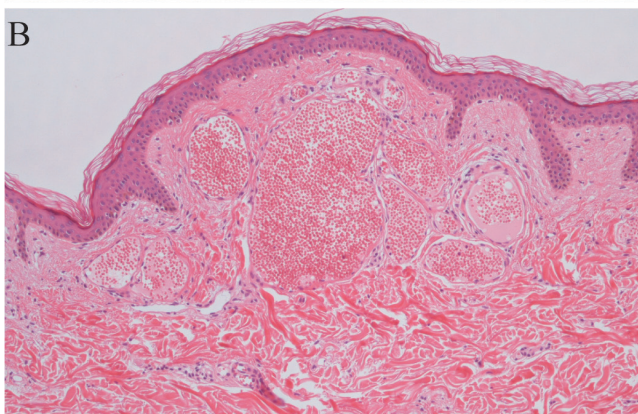
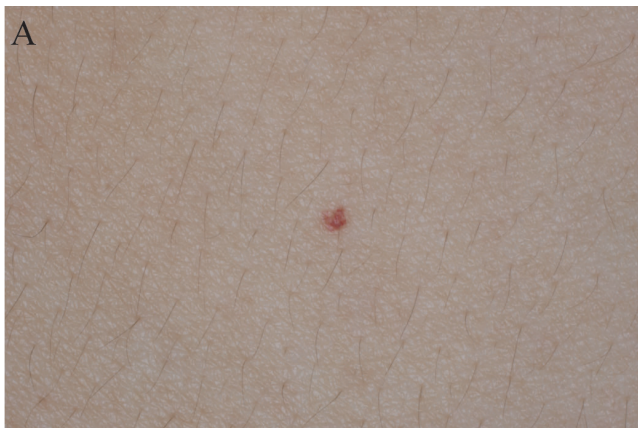

Fig. 1. (A) Clinical presentation: 2-mm diameter, solitary, red papule on the right chest. (B) Histologically, red papule shows the features of cherry haemangioma rather than those of angiokeratoma (haematoxylin-eosin staining \times 100).

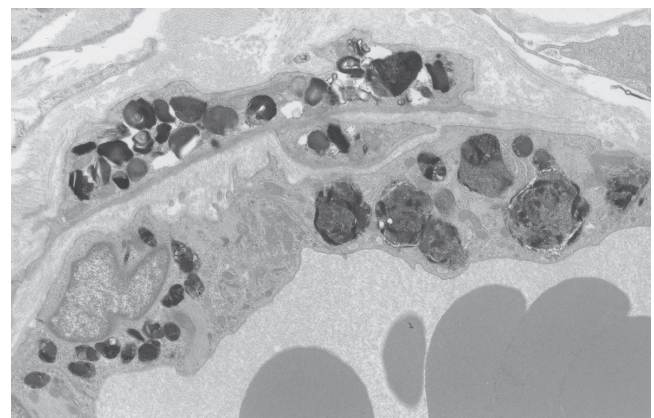


Fig. 2. Electron-dense cytoplasmic inclusion bodies within vascular endothelial cells and pericytes (lead hydroxide staining, original magnification \times 4,000).

DISCUSSION

FD is a rare X-linked inherited disorder, which affects approximately 1 in 40,000–60,000 males in Europe and United States (3). Affected males usually present in childhood with episodes of acroparaesthesia and oligohidrosis, followed by angiokeratoma corporis diffusum, which appears as tiny, clustered, hyperkeratotic and coalescing red papules. Angiokeratomas are vascular ectasia, demonstrating histologically dilated vessels mainly in the papillary dermis underlying the acanthotic epidermis, with hyperkeratosis and elongation of the rete ridges which partially or completely enclose the vessels (4). They are found in 65–70% of male patients with FD and usually start to appear shortly before puberty (5, 6). They are clustered and numerous in some patients, but sparse in most women and many men (7). Electron microscopy of angiokeratoma corporis diffusum shows cytoplasmic inclusion bodies, which are dense and lamellar with a periodicity of 4–6 nm, in vascular endothelial cells and pericytes (8). On the other hand, cherry haemangiomas are true haemangiomas, which demonstrate histologically dilated, thin-walled vessels in the subpapillary regions sparing the papillary dermis. There is loss of rete ridges and atrophy of the overlying epidermis. Homogenization of the collagen may be seen in the intervascular stroma. They are very common single or multiple bright-red papules, up to several millimetres in diameter. These lesions may start to appear in early adulthood, and the number of lesions increases with age (9).

In the case described here, the patient with FD presented with a few, 2–3-mm diameter, bright-red papules, pathologically compatible with cherry haemangioma rather than angiokeratoma, because they are true haemangioma sparing the papillary dermis. They are not a vascular ectasia. Hogarth et al. (10) reported a 76-year-old man with FD who had widespread cherry haemangiomas on his trunk and angiokeratomas localized on his scrotum. They concluded that a diagnosis of FD should be considered in patients with cherry haemangiomas and cardiac disease. Our case and their report suggest the possibility that cherry haemangioma correlates with FD.

Satoh et al. (11) showed the clinical usefulness of performing biopsy of cherry haemangiomas for the diagnosis of intravascular lymphoma (IVL). IVL is a rare subtype of extranodal diffuse large B-cell lymphoma

with an aggressive clinical course, characterized histologically by predominant proliferation of lymphoma cells within the blood vessel. However, as the clinical symptoms are highly variable, IVL can take a long time to diagnose. The poor prognosis is thought to reflect delays in diagnosis and in the start of chemotherapy. Since FD can also be considered a progressive and life-threatening disease, we recommend that electron microscopy is performed on cherry haemangiomas of patients with suspected FD. This may contribute to the early diagnosis of FD and thus improve prognosis.

REFERENCES

1. Ashton-Prolla P, Tong B, Shabbeer J, Astrin KH, Eng CM, Desnick RJ. Fabry disease: twenty-two novel mutations in the alpha-galactosidase A gene and genotype/phenotype correlations in severely and mildly affected hemizygotes and heterozygotes. *J Investig Med* 2000; 48: 227–235.
2. Brady RO, Schiffmann R. Clinical features of and recent advances in therapy for Fabry disease. *JAMA* 2000; 284: 2771–2775.
3. Desnick RJ, Ioannou YA, Eng CM. α -Galactosidase deficiency: Fabry disease. In: Scriver CR, Beaudet AL, Sly WS, Valle D, editors. *The metabolic and molecular bases of inherited disease*. 8th edn. Vol. 3. New York: McGraw-Hill, 2001: p. 3733–3774.
4. Schiller PI, Itin PH. Angiokeratomas: an update. *Dermatology* 1996; 193: 275–282.
5. MacDermot KD, Holmes A, Miners AH. Anderson-Fabry disease. Clinical manifestations and impact of disease in a cohort of 98 hemizygous males. *J Med Genet* 2001; 38: 750–760.
6. Deegan PB, Baehner AF, Barba Romero MA, Hughes DA, Kampmann C, Beck M. Natural history of Fabry disease in females in the Fabry Outcome Survey. *J Med Genet* 2006; 43: 347–352.
7. Orteu CH, Jansen T, Lidove O, Jaussaud R, Hughes DA, Pintos-Morell G, et al. Fabry disease and the skin: data from FOS, the Fabry outcome survey. *Br J Dermatol* 2007; 157: 331–337.
8. Hashimoto K, Lieberman P, Lamkin N. Angiokeratoma corporis diffusum (Fabry's disease): a lysosomal disease. *Arch Dermatol* 1976; 112: 1416–1423.
9. Calonje E, Wilson-Jones E. Vascular tumors. In: Elder D, editor. *Lever's histopathology of the skin*. 10th edn. Philadelphia: Raven Publishers; 2009: p. 900.
10. Hogarth V, Dhoat S, Mehta AB, Orteu CH. Late-onset Fabry disease associated with angiokeratoma of Fordyce and multiple cherry angiomas. *Clin Exp Dermatol* 2011; 36: 506–508.
11. Satoh S, Yamazaki M, Yahikozawa H, Ichikawa N, Saito H, Hanyuu N, et al. Intravascular large B cell lymphoma diagnosed by senile angioma biopsy. *Intern Med* 2003; 42: 117–120.