

QUIZ SECTION

Intertriginous Orange-to-Brownish Papules and Plaques: A Quiz

Ferdinand Toberer, Wolfgang Hartschuh, Mathias Witzens-Harig, Alexander H. Enk and Anke S. Lonsdorf

Department of Dermatology, Ruprecht-Karls-University of Heidelberg, DE-69115 Heidelberg, Germany. E-mail: anke.lonsdorf@med.uni-heidelberg.de

A 74-year-old man was referred to our dermatology clinic with a 10-year history of slowly increasing, widespread red-orange to red-brown papules that tended to coalesce, especially in the axillae. Physical examination revealed multiple, round-to-oval papules and plaques on his axillae, neck and upper chest (Fig. 1). His facial skin and oral mucosa were not affected. Despite occasional pruritus, the skin lesions were largely asymptomatic and the patient did not report any further symptoms. The patient's family history for cutaneous diseases was negative, and he did not report any concomitant disease. Besides a mild renal insufficiency, further clinical examination and basic laboratory tests were normal. Histopathology revealed a dense, granulomatous dermal infiltrate in upper dermis consisting of histiocytes, lymphocytes, and a few eosinophils and multinucleated giant cells (Fig 1b). "Foamy" histiocytes stained negative for S-100 and CD1a, but positive for CD68.

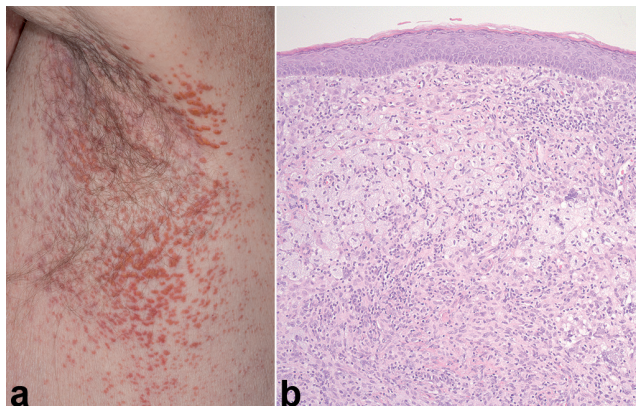


Fig. 1. Left axilla showing multiple, orange-to-brown papules, tending to coalesce into plaques (a). Skin specimen stained with H&E $\times 10$ (b).

What is your diagnosis? See next page for answer.

doi: 10.2340/00015555-1495

ANSWERS TO QUIZ

Intertriginous Orange-to-brownish Papules and Plaques: Comment

Acta Derm Venereol 2013; 93: 493–495.

Diagnosis: Xanthoma disseminatum

Xanthoma disseminatum (XD) is a rare, mucocutaneous disorder belonging to the cutaneous non-Langerhans' cell histiocytoses. XD was first defined in 1938 by Montgomery and Osterberg (1). XD can occur at any age and in either sex. The male:female ratio is 2.4:1 (2). While the age of onset of XD ranges from 8 months to 85 years (2), in 50% of cases skin lesions appear before 25 years of age, and 36% of the patients are children (3). In contrast to other xanthomatoses, XD is classically normolipaeamic; nevertheless, some deviations from normal lipid profile have been reported in 20% of cases (2). The clinical course of XD can be self-healing (lesions resolving spontaneously after years), persistent (as in our patient) or progressive (exacerbation of skin lesions and development of systemic involvement) (4). While XD is considered to be generally benign, internal involvement and associated disorders may result in extensive morbidity.

In addition to the characteristic skin lesions, involvement of mucous membranes and internal organs is not uncommon. Mucous membrane involvement has been reported in 39–60% of cases (2). In cases of severe affection of the larynx and the upper airway tract, patients may develop hoarseness and dyspnoea; some patients may require tracheostomy (2). Ocular involvement is mostly corneal and epibulbar and can cause visual impairment (5). Central nervous system (CNS) involvement carries a particularly poor prognosis, with a mortality rate as high as 63% in cases with intracranial disease outside the pituitary and hypothalamus, and 100% in those with posterior fossa involvement (2). Extensive xanthomatous infiltration of the CNS (e.g. the hypothalamic-pituitary axis) is thought to cause symptoms such as diabetes insipidus, epilepsy, cerebellar ataxia, ophthalmoplegia or growth retardation. Diabetes insipidus is reported in up to 40% of patients with XD (Montgomery syndrome) (6). Since an association of XD with multiple myeloma or Waldenström's macroglobulinaemia have been reported (2), patients should be assessed by a haematologist.

The differential diagnosis includes eruptive and papular xanthoma, juvenile xanthogranuloma, progressive nodular histiocytosis, multicentric reticulohistiocytosis and cutaneous Langerhans' cell histiocytoses.

Currently therapeutic options are limited to symptomatic and cosmetic improvement. Immunosuppressive drugs (e.g. cyclophosphamide, azathioprine, oral glucocorticoids) radiotherapy and surgical procedures (i.e. excision, dermabrasion, electrocoagulation and carbon-dioxide laser) have been used in the past, with moderate effect (2). Owing to the potential of XD to undergo spontaneous

resolution, reports of clinical responses should be interpreted with caution. Successful target-oriented strategies should focus on the therapeutic modulation of xanthoma formation, the local recruitment of histiocytes, and their transformation into lipidized, "foamy" cells, respectively.

In our patient serum lipids, complete blood count, basic metabolic panel, and parameters for thyroid, kidney and liver function were without pathological findings. Neurological and ophthalmological examination revealed no systemic involvement. Haematological examination revealed increased β_2 -microglobulin levels (4.1 mg/l, normal ≤ 2.5 mg/l) and increased serum values of free monoclonal lambda and kappa light chains (lambda: 29.5 mg/l, normal 5.7–26.3 mg/l; kappa: 56.4 mg/l, normal 3.3–19.4 mg/l). Serum protein electrophoresis showed a slight increase in alpha-2 globulin (11.1%, normal 7.0–11.0%), gamma-globulin (17.7%, normal 9.0–16.0%) and a slight decrease in albumin (59.2%, normal 60–71%).

As serum immunofixation was without pathological findings in our patient, the moderate elevation of light chain values and the elevation of β_2 -microglobulin were first and foremost interpreted as unspecific; most likely resulting from a mild renal insufficiency (7, 8). Nevertheless, these values should be monitored at regular intervals for the potential development of monoclonal gammopathy of undetermined significance or multiple myeloma.

As the skin lesions in our patient were largely asymptomatic and systemic involvement was absent, we decided not to initiate any therapy.

REFERENCES

1. Montgomery H, Osterberg AE. Xanthomatosis. Correlation of clinical histopathologic and chemical studies of cutaneous xanthoma. Arch Dermatol Syphilol 1938; 37: 375–402.
2. Carpo BG, Grevelink S, Brady S, Gellis S, Grevelink JM. Treatment of cutaneous lesions of xanthoma disseminatum with a CO₂ laser. Dermatol Surg 1999; 25: 751–754.
3. Altman J, Winkelmann RK. Xanthoma disseminatum. Arch Dermatol 1962; 86: 582–589.
4. Seaton ED, Pillai GJ, Chu AC. Treatment of xanthoma disseminatum with cyclophosphamide. Br J Dermatol 2004; 150: 346–349.
5. Caputo R. Juvenile xanthogranulomas and xanthoma disseminatum-variations on a single theme [reply letter]. J Am Acad Dermatol 1986; 15: 109.
6. Knobler RM, Neumann RA, Gebhart W, Radaskiewicz T, Ferenci P, Widhalm K. Xanthoma disseminatum with progressive involvement of the central nervous and hepatobiliary systems. J Am Acad Dermatol 1990; 23: 341–346.
7. Sölling K. Polymeric forms of free light chains in serum from normal individuals and from patients with renal disease. Scand J Clin Lab Invest 1976; 36: 447–452.
8. Evrin PE, Wibell L. Serum β_2 -microglobulin in various disorders. Clinica Chimica Acta 1973; 43: 183–187.