

## Combination Therapy of Infliximab and Granulocyte/Monocyte Adsorption Apheresis for Refractory Pustular Psoriasis with Psoriatic Arthritis

Tomomi Fujisawa, Chie Moriya, Yoshinao Shibuya, Hiroyuki Kanoh and Mariko Seishima\*

Department of Dermatology, Gifu University Graduate School of Medicine, 1-1 Yanagido, Gifu, 501-1194, Japan. \*E-mail: marikoseishima@yahoo.co.jp  
Accepted July 2, 2012; Epub ahead of print Sep 25, 2012

Infliximab, a chimeric monoclonal immunoglobulin G (IgG) antibody against tumour necrosis factor alpha (TNF- $\alpha$ ), is effective in patients with psoriasis, including pustular psoriasis and psoriatic arthritis (1). Infliximab results in a Psoriasis Area Sensitivity Index (PASI) 75 remission in 79% of psoriatic patients by 10 weeks of treatment, and this effect persists in 74% and 53% of patients at 6 and 12 months, respectively (2). Efficacy is lost by various means, sometimes by development of antibodies to infliximab, which occurs in 19% of patients (2). Co-medication with methotrexate is recommended to improve efficacy or to reduce the development of antibodies to infliximab, especially in psoriatic arthritis (3). However, methotrexate could not be given to our patient due to previous adverse effects of the drug.

Granulocyte/monocyte adsorption therapy (GMA) was originally used weekly as an effective therapy for ulcerative colitis, for a total of 10 sessions, and is also an effective treatment for pustular psoriasis (4, 5); this therapy involves the removal of activated leukocytes from the peripheral blood and other undefined mechanisms. We report here a case of pustular psoriasis with psoriatic arthritis, in which remission was successfully achieved with a combination of infliximab and GMA.

### CASE REPORT

A 60-year-old Japanese woman presented with a history of psoriasis vulgaris with psoriatic arthritis for 50 years. She had experienced frequent pustular psoriasis from the

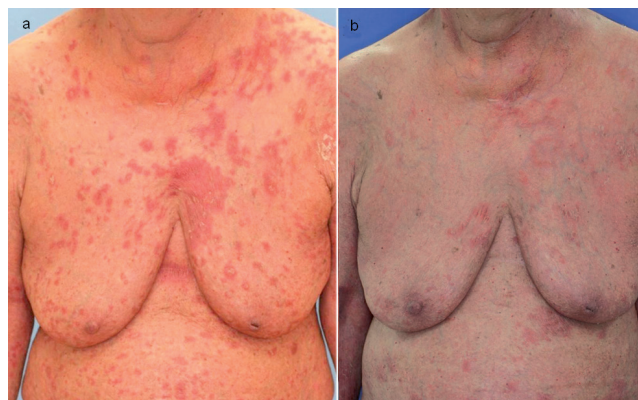

Fig. 2. Clinical findings of skin eruption exacerbation after (a) the fifth infliximab injection and (b) after 5 sessions of granulocyte/monocyte adsorption therapy (GMA). Skin eruption was considerably improved after GMA, with alleviation of fever.

age of 16 years. She had undergone various topical and systemic therapies: topical steroids and vitamin D3, ultraviolet therapy, etretinate 10 mg/day, cyclosporine 150 mg/day, methotrexate 7.5 mg/week, and prednisolone 20 mg/day. None of these therapies was sufficiently effective. Moreover, the patient experienced various adverse effects: hyperostotic changes in the femurs induced by etretinate, osteoporosis and diabetes mellitus induced by prednisolone, hypertension induced by cyclosporine, and liver dysfunction induced by methotrexate. When the PASI was 35.4 and disease activity score (DAS) 28 was 5.45, 5 mg/kg/day of infliximab showed remarkable efficacy. Thus, infliximab was additionally administered after 2 and 6 weeks, and then every 8 months, resulting in PASI of 0.9 and DAS28 of 4.2 (Fig. 1). However, the skin eruption was exacerbated, with swelling of the lower extremities, multiple severe arthralgia, and fever of 38.5°C at 3 weeks after the fifth injection of infliximab. Additional therapy with prednisolone 20 mg/day and loxoprofen improved arthralgia and reduced body temperature, but no change was observed in erythema with pustules. Skin eruption, arthralgia, and fever were improved at 6 weeks after the sixth injection of infliximab at 6 mg/kg/day. Thereafter, the dose of prednisolone was finally reduced to 5 mg/day. However, eruption with fever and severe arthralgia recurred after 3 weeks, and the dose of prednisolone was increased to 10 mg/day, without effect. After obtaining

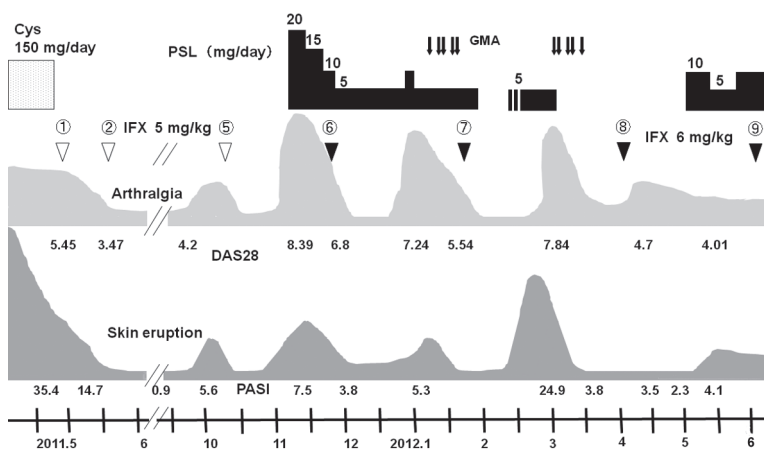


Fig. 1. Clinical course and treatments in this case. Cys: cyclosporine; IFX: infliximab; PSL: prednisolone; GMA: granulocyte/monocyte adsorption therapy; DAS: disease activity score. White arrowheads: IFX 5 mg/kg; black arrowheads: IFX 6 mg/kg.

informed consent, GMA was administered twice a week, for a total of 5 sessions. Erythema with pustules rapidly disappeared, with reduced arthralgia and fever after GMA (Fig. 2). The second course of co-therapy with GMA and infliximab was also effective. After secondary amyloidosis was found on the mucous membrane of the stomach and intestine by gastroenteroscopy, prednisolone was administered daily at 10 mg/day with infliximab therapy every 6 weeks (Fig. 1).

## DISCUSSION

Pustular psoriasis, a subtype of psoriasis, is a rare disorder with skin eruption of erythema, sterile pustules, and oedema on the whole body, associated with episodes of fever, leukocytosis, and increased levels of C-reactive protein. Histopathologically, it is characterized by neutrophil infiltration into the epidermis, forming Kogoj's spongiotic pustules. Although cyclosporine, etretinate and TNF- $\alpha$  inhibitors are often administered to patients with this disease, some cases are refractory to these therapies. The immunopathogenesis of psoriasis has been extensively reviewed; helper T (Th) 1 and Th17 lymphocytes contribute to the pathogenesis of psoriasis through the release of inflammatory cytokines that promote further recruitment of immune cells, keratinocyte proliferation, and sustained inflammation. The innate immune system, including macrophages, dendritic cells, monocytes, neutrophils, natural killer T cells and  $\gamma\delta$  T cells, can direct the development of pathogenic Th cells in psoriasis.

GMA-apheresis is designed to remove granulocytes and monocytes, which are a major source of inflammatory cytokines, from peripheral blood in order to attenuate inflammation. GMA is an extracorporeal therapy using a column filled with cellulose acetate beads, which adsorbs 28.3% of granulocytes, 18.1% of monocytes, and 7.8% of lymphocytes from blood in the column (6). It has been reported that CD16+ myeloid dendritic cells (mDC), activated in ulcerative colitis, are removed by GMA, probably resulting in a reduction in serum TNF- $\alpha$  levels (7). Adsorptive depletion of CD14+/CD16+ mDC may suggest a mechanism for the beneficial effect of GMA in pustular psoriasis (8). In our patient, GMA could have removed activated mDC, followed by reduced cytokine levels including TNF- $\alpha$ , at a point when TNF- $\alpha$  levels were gradually increasing because of loss of infliximab efficacy.

Remission in a case of Crohn's disease has been reported to have been achieved by a combination of infliximab and GMA (9). Intensive GMA (2 sessions

per week) has been reported to be strikingly better than weekly GMA, both in remission rate and days to remission (10). This is the first report of pustular psoriasis treated with a combination of these therapies. In our patient, no adverse effects were observed during or after intensive GMA. We conclude that GMA can be effective for treating refractory pustular psoriasis in a combination therapy with infliximab.

*The authors declare no conflicts of interest.*

## REFERENCES

1. Lisby S, Gniadecki R. Infliximab (Remicade) for acute, severe pustular and erythrodermic psoriasis. *Acta Derm Venereol* 2004; 84: 247–248.
2. Reich K, Nestle FO, Papp K, Ortonne JP, Evans R, Guzzo C, et al. Infliximab induction and maintenance therapy for moderate-to-severe psoriasis: a phase III, multicentre, double-blind trial. *Lancet* 2005; 366: 1367–1374.
3. Smith CH, Anstey AV, Barker JN, Burden AD, Chalmers RJ, Chandler DA, et al. British Association of Dermatologists' guidelines for biologic interventions for psoriasis 2009. *Br J Dermatol* 2009; 161: 987–1019.
4. Kanekura T, Yoshii N, Yonezawa T, Kawabata H, Saruwatari H, Kanzaki T. Treatment of pustular psoriasis with granulocyte and monocyte adsorption apheresis. *J Am Acad Dermatol* 2003; 49: 329–332.
5. Fujisawa T, Murase K, Okumura Y, Kanoh H, Doi T, Yoshida S, et al. Generalized pustular psoriasis successfully treated with granulocyte and monocyte adsorption apheresis. *Ther Apher Dial* 2011; 15: 374–378.
6. Hiraishi K, Takeda Y, Shiobara N, Shibusawa H, Jimma F, Kashiwagi N, et al. Studies on the mechanisms of leukocyte adhesion to cellulose acetate beads: an in vitro model to assess the efficacy of cellulose acetate carrier-based granulocyte and monocyte adsorptive apheresis. *Ther Apher Dial* 2003; 7: 334–340.
7. Sanchez-Garcia J, Serrano-López J, García-Sánchez V, Alvarez-Rivas MA, Jimenez-Moreno R, Perez-Seoane C, et al. Tumor necrosis factor- $\alpha$ -secreting CD16+ antigen presenting cells are effectively removed by granulocyte adsorption apheresis in ulcerative colitis patients. *J Gastroenterol Hepatol* 2010; 25: 1869–1875.
8. Fujisawa T, Murase K, Kanoh H, Takemura M, Ohnishi H, Seishima M. Adsorptive depletion of CD14+/CD16+ proinflammatory monocyte phenotype in patients with generalized pustular psoriasis: clinical efficacy and effects on cytokines. *Ther Apher Dial* 2012; 16: 436–444.
9. Fukunaga K, Yokoyama Y, Kamikozuru K, Yoshida K, Kikuyama R, Nagase K, et al. Selective depletion of peripheral granulocyte/monocyte enhances the efficacy of scheduled maintenance infliximab in Crohn's disease. *J Clin Apher* 2010; 25: 226–228.
10. Kato S, Kani K, Takabayashi H, Yamamoto R, Ogawa T, Matsuda A, et al. Treatment of refractory Crohn's disease by intensive granulocyte and monocyte adsorption apheresis: A report on two drug refractory cases. *Intern Med* 2011; 50: 1591–1593.