

Deep Pseudocystic Dermatophytosis Caused by *Trichophyton rubrum* in a Patient with Myasthenia Gravis

Yasushi Matsuzaki¹, Kazuko Ota², Kentaro Sato², Syoetsu Nara², Takashi Yaguchi³, Hajime Nakano¹ and Daisuke Sawamura¹

¹Department of Dermatology, Hirosaki University Graduate School of Medicine, 5 Zaifu-cho, Hirosaki, 036-8562, ²Department of Clinical Laboratory, Odate Municipal General Hospital, Odate, and ³Medical Mycology Research Center, Chiba University, Chiba, Japan. E-mail: ymatsu@cc.hirosaki-u.ac.jp
Accepted June 13, 2012; Epub ahead of print Sep 5, 2012

Trichophyton rubrum is the most frequently encountered dermatophyte that causes minor skin infections in keratinized epithelial structures, such as skin and nails, even in healthy individuals (1). Deep dermatophytosis caused by *T. rubrum* is a rare clinical entity characterized by infection of the dermis, subcutis, and internal visceral organs (1–7). It follows an atypical aggressive course, particularly in immunocompromised patients (2–4). We describe here a rare case of a patient with *T. rubrum* infection that manifested as deep dermatophytosis with multiple subcutaneous cysts.

CASE REPORT

A 44-year-old woman presented with a one-year history of multiple nodules and erythematous plaques on her face, extremities, buttocks and pubic region. She had been diagnosed with acne vulgaris and was treated with antibacterial ointment, but the lesions continued to grow. Physical examination revealed multiple subcutaneous cystic tumours and erosive erythematous plaques on her cheek, neck, extremities and buttocks (Fig. 1a). The pubic region showed well-demarcated, multilocular, subcutaneous cysts with discharge (Fig. 1b). The inguinal lymph nodes were swollen. Some of the cysts discharged a yellowish purulent fluid. Although direct microscopic potassium hydroxide slides of the epidermal scales of the feet demonstrated fungal elements, the nails on her fingers and toes had no features of tinea unguium. Two years prior to presentation, she had been diagnosed with myasthenia gravis and was treated with systemic prednisolone (25 mg) and tacrolimus (3 mg) daily after thymectomy. In a medical interview she disclosed that she had bathed hot water that had not been changed for 6 months, but which had been filtered through a water filter intended for use in tropical fish tanks. Although the biopsy tissue and the material from the cystic tumours were cultured several times, no mycobacterial infection was identified. Direct microscopy of potassium hydroxide preparations of the purulent matter showed septate hyphae. Blood analysis yielded normal results, except for a high beta-d-glucan level (> 300 pg/ml). The culture of purulent matter taken from the cystic tumours yielded *T. rubrum*. Microscopic examination of the *T. rubrum* colonies with cotton blue stain showed teardrop-shaped microconidia on long septate hyphae. This identification was confirmed by sequence analysis of the ribosomal internal transcribed spacer (ITS) 1, 5.8S and ITS2 region (8). A skin biopsy specimen was taken from the patient's buttocks. Histological examination showed a pseudocyst containing numerous neutrophils and necrotic debris in the subcutaneous tissue (Fig. 2a). The pseudocyst wall comprised multinucleated giant cells, histiocytes, lymphocytes and neutrophils. The epidermis and dermis were almost normal. Periodic acid-Schiff staining confirmed the presence of multiple narrow, septate, branching hyphae in the pseudocyst wall, but not in the epidermis or hair follicles (Fig. 2b). Thoracic computed tomography showed no abnormalities in the chest cavity. However, multiple cystic tumours were detected in the dorsal subcutis (Fig. 2c). Endoscopic examination did not show any evidence of fungal

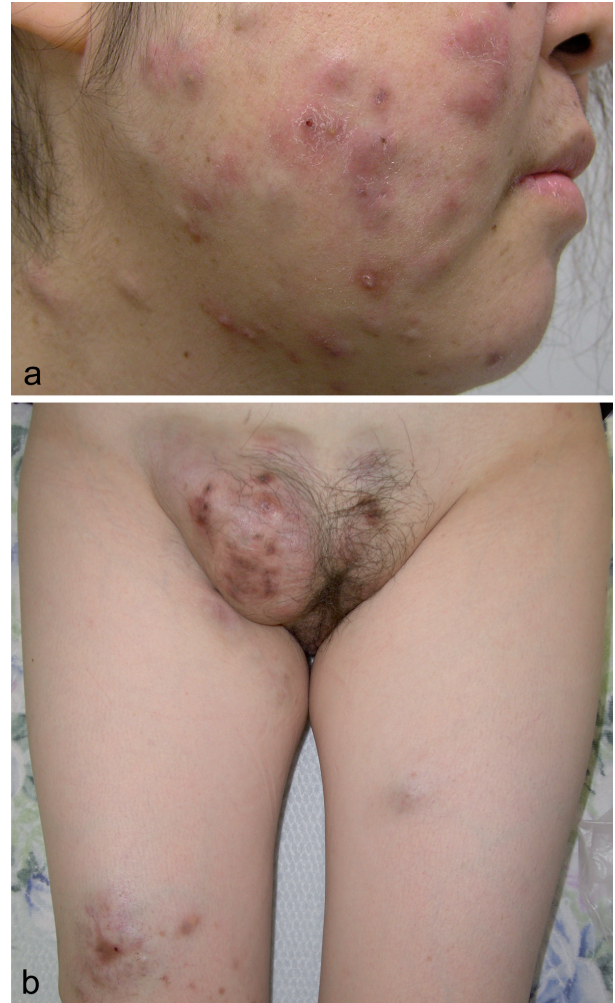

Fig. 1. Clinical features. (a) Multiple subcutaneous cystic tumours and erythematous plaques on the cheek and neck. (b) Well-demarcated, multilocular, subcutaneous cysts in the pubic region and on the right thigh.

infection. Thus, deep pseudocystic dermatophytosis caused by *T. rubrum* was diagnosed. Large cystic tumours were aspirated and excised to remove the purulent matter. The patient was treated with itraconazole (200 mg daily) for 4 months. Because the serum concentration of tacrolimus gradually increased due to the itraconazole, the patient was treated with terbinafine hydrochloride for 2 years. Finally, most of the cystic tumours disappeared, and the serum beta-D-glucan level returned to normal.

DISCUSSION

Dermatophytes are common fungal pathogens that give rise mainly to superficial infections of the skin,

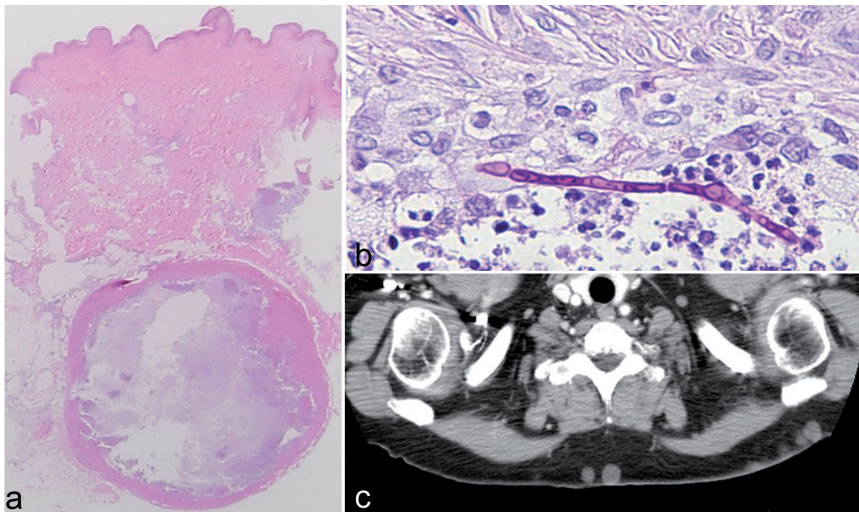


Fig. 2. (a) Pseudocyst in the subcutis (haematoxylin and eosin (H&E) stain; original magnification $\times 1$). (b) Narrow, septate hyphae in the pseudocyst wall (Periodic acid-Schiff stain; original magnification $\times 400$). (c) Thoracic computed tomography showing multiple cystic tumours in the dorsal subcutis.

nails and hair (1–7). One of the most prevalent species belonging to this group is *T. rubrum*. Rarely, deep dermatophytosis caused by *T. rubrum* becomes more aggressive and invasive in immunocompromised patients (2–4). Most of these cases have co-incident nail infection, suggesting that dermatophytes may invade the dermis by autoinoculation (2, 3). Although our patient was immunosuppressed, she did not exhibit tinea unguium. However, she had bathed in hot water that had not been changed for 6 months. Although we did not obtain a sample of the water for culture, we suspect that it contained a large amount of keratinous debris and hair with dermatophytes. It is possible that, in our patient, dermatophytosis was initiated via the hair follicles during bathing. However, our observations did not show any affected hair follicles or sweat ducts. Nevertheless, we assume that the dermatophytes invaded the dermis through the hair follicle and developed completely before being captured by the infiltrating cells. Subsequently, granulomas containing histiocytes and neutrophils appeared in the subcutis and finally changed to the pseudocystic forms containing necrotic debris.

Her healthy family was unaffected despite using the same bathtub, suggesting that her immunosuppressed condition induced this deep dermatophytosis. Majocchi's granuloma is one of the representative deep dermatophytosis, and presents as fungal suppurative folliculitis and nodular granulomatous perifolliculitis (4). However, the formation of pseudocyst in the subcutaneous tissue is not commonly seen. To the best of our knowledge, there is only one other report of multiple pseudocysts caused by *T. rubrum* (3). This previous case

was also of an immunosuppressed patient with multiple cysts in the pubic region (3). In this case self-injection of insulin for diabetes mellitus may have triggered the transfer of superficial dermatophytes to the dermis (3).

REFERENCES

1. Smith KJ, Welsh M, Skelton H. *Trichophyton rubrum* showing deep dermal invasion directly from the epidermis in immunosuppressed patients. *Br J Dermatol* 2001; 145: 344–348.
2. Seçkin D, Arikan S, Haberal M. Deep dermatophytosis caused by *Trichophyton rubrum* with concomitant disseminated nocardiosis in a renal transplant recipient. *J Am Acad Dermatol* 2004; 51: 173–176.
3. Kobayashi M, Ishida E, Yasuda H, Yamamoto O, Tokura Y. Tinea profunda cysticum caused by *Trichophyton rubrum*. *J Am Acad Dermatol* 2006; 54: 11–13.
4. Gong JQ, Liu XQ, Xu HB, Zeng XS, Chen W, Li XF. Deep dermatophytosis caused by *Trichophyton rubrum*: report of two cases. *Mycoses* 2007; 50: 102–108.
5. Tsang P, Hopkins T, Jimenez-Lucho V. Deep dermatophytosis caused by *Trichophyton rubrum* in a patient with AIDS. *J Am Acad Dermatol* 1996; 34: 1090–1091.
6. Nir-Paz R, Elinav H, Pierard GE, Walker D, Maly A, Shapiro M, et al. Deep infection by *Trichophyton rubrum* in an immunocompromised patient. *J Clin Microbiol* 2003; 41: 5298–5301.
7. Sentamilselvi G, Janaki C, Kamalam A, Thambiah AS. Deep dermatophytosis caused by *Trichophyton rubrum* – a case report. *Mycopathologia* 1998; 142: 9–11.
8. White TJ, Bruns TD, Lee SB, Taylor JW. Amplification and direct sequencing of fungal ribosomal DNA for phylogenetics. In: Innis MA, Gelfand DH, Sninsky JJ, White TJ, editors. *PCR protocols: a guide to the methods and application*. San Diego: Academic Press; 1990, p. 315–322.