

CLINICAL REPORT

Effective Control of Recalcitrant Pruritus by Bevacizumab: A Possible Role for Vascular Endothelial Growth Factor in Chronic Itch?

Karoline KRAUSE, Clemens KRULL, Birgit KESSLER, Bernhard LANGE-ASSCHENFELDT, Marcus MAURER and Martin METZ
Allergie-Centrum-Charité, Department of Dermatology and Allergy, Charité – Universitätsmedizin Berlin, Berlin, Germany

Prurigo is a difficult to treat condition characterized by severe pruritus presenting with chronic secondary scratch lesions. We report here a dramatic improvement in pruritus in a patient with prurigo simplex who was being treated with bevacizumab, a monoclonal vascular endothelial growth factor (VEGF) antibody. On the basis of the increased VEGF expression measured in the skin of this patient, serum levels of VEGF were subsequently analysed in 27 consecutive patients with prurigo and 19 healthy controls. VEGF levels were significantly increased in the serum of patients with prurigo. Moreover, VEGF concentrations correlated with physician-assessed disease activity. Based on these observations, we speculate that VEGF is involved in the pathophysiology of prurigo. Key words: VEGF, pruritus, itch, prurigo.

Accepted May 23; Epub ahead of print Aug 29, 2012

Acta Derm Venereol 2013; 93: 175–179.

Martin Metz, Allergie-Centrum-Charité, Department of Dermatology and Allergy, Charité – Universitätsmedizin Berlin, Charitéplatz 1, DE-10117 Berlin, Germany. E-mail: martin.metz@charite.de

Chronic pruritus, i.e. itching for longer than 6 weeks, is a major therapeutic problem, which can have a severe impact on quality of life. According to the International Forum for the Study of Itch (IFSI), chronic pruritus should be classified as: (i) pruritus on inflamed skin, (ii) pruritus on non-inflamed skin, and (iii) pruritus presenting with chronic secondary scratch lesions (1). The last group consists mainly of patients with prurigo, a condition that is frequently associated with chronic itching that is refractory to therapy, and which may continue for several years. Prurigo can present either with hyperkeratotic nodules as prurigo nodularis or without nodules as prurigo simplex. In some patients with prurigo the severe pruritus can be associated with different dermatological or systemic diseases. Iking and colleagues reported recently that in 87% of patients with prurigo nodularis, an underlying disease can be detected (2). Reported underlying diseases range from various dermatological diseases, metabolic diseases, hepatic or renal diseases to malignancies and psychological factors (2). However, the pathomechanisms underlying chronic itch in prurigo are

largely unknown, regardless of the potential underlying disease. Fukushi et al. (3) demonstrated recently that a high rate of STAT3 (signal transducer and activator of transcription 3) and STAT6 (signal transducer and activator of transcription 6) activation can be detected in the epidermis of patients with prurigo nodularis, indicating a potential role for Th2 cytokines and other unknown factors leading to STAT3 activation in prurigo nodularis.

Lack of knowledge of the pathophysiological mechanisms responsible for prurigo means that no efficient, targeted therapy is available. Therefore, the management of patients with prurigo is often difficult and frustrating for both patients and physicians. Although various therapeutic approaches have been reported, efficient and safe long-term treatment remains challenging. Current therapy consists mainly of topical anti-inflammatory treatment with potent steroids and additional ultraviolet (UV) therapy. To obtain a long-term improvement in the patients' symptoms, systemic anti-pruritic treatment is usually necessary. As antihistamines are not sufficient to suppress pruritus in these patients, immunosuppressive therapies, such as cyclosporine and various off-label drugs, for example anticonvulsants, opioid receptor antagonists, intravenous immunoglobulins, thalidomide or anti-emetics, have been used with varying results (4–7).

The observation of antipruritic effects of drugs targeting specific pathways in patients with chronic pruritus may shed light on some of the relevant signals in the condition and lead to more detailed studies aimed at identifying potential underlying mechanisms.

We report here a dramatic improvement in pruritus in a patient with prurigo with newly diagnosed breast cancer treated with a vascular endothelial growth factor (VEGF) antagonist. This observation led us to investigate further the potential role of VEGF in prurigo. VEGF and its receptors are known to be pro-angiogenic under physiological and pathological conditions. Furthermore, VEGF has been shown to be involved in the progression of various cancers, and VEGF inhibitors are used in the treatment of different types of cancer (8). Bevacizumab is a humanized monoclonal antibody targeting VEGF and thereby inhibiting its activity. It is approved in combination with chemotherapy for the treatment of many advanced cancers, for example colorectal cancer, non-small cell lung cancer, breast cancer, renal cell carcinoma, and glioblastoma multiforme (9, 10).

MATERIALS AND METHODS

Patients

Apart from 1 patient for whom data was collected retrospectively (see Case report), we prospectively evaluated a total of 27 consecutive patients with prurigo who were admitted to our department (12 males, 15 females, mean age 70.6 years), and 19 healthy volunteers. Serum was collected from all patients and healthy controls. Disease activity of prurigo was assessed by the attending physician on the ward prior to VEGF analysis. Disease activity was based on skin status (e.g. number and area of scratch lesions, erosions/ulcerations) and overall well-being of the patient, and was scored on a scale from 0 (no apparent disease) to 10 (maximum disease severity). Itch intensity was documented using a verbal rating scale (0–10, 0 = no itch, 10 = worst itch imaginable) at the time of admission. Laboratory analyses (in all patients) and histological analyses (in 13 patients) were performed during routine diagnostic workup. Blood eosinophilia was defined as eosinophil counts above 0.85/nl, and occurrence of eosinophils in lesional skin was defined as tissue eosinophilia. Written informed consent was given by all patients and healthy controls. The study was approved by the local ethics committee.

Immunohistochemistry

VEGF-immunoreactivity was studied in 5- μ m paraffin sections of lesional skin using a primary mouse monoclonal antibody (R&D Systems, Minneapolis, USA) and the Dako REAL TM Detection System (Dako Denmark A/S, Glostrup, Denmark). Slides were then counterstained with Papanicolaou's 1a Harris' haematoxylin (Merck, Darmstadt, Germany).

Vascular endothelial growth factor measurement

The concentration of VEGF in the serum was measured with an enzyme-linked immunosorbent assay (ELISA) according to the manufacturer's instructions (R&D Systems). Standards and samples were assayed in duplicate. The assay's detection limit is < 10 pg/ml.

Statistical analyses

For comparison of VEGF levels in healthy individuals and patients with prurigo and with different clinical characteristics, an unpaired Student's *t*-test was used. For correlational analysis of VEGF levels and disease activity or itch intensity, Pearson's correlation coefficient was calculated. For all analyses, a *p*-value < 0.05 was considered significant.

RESULTS

Case report of effective anti-vascular endothelial growth factor treatment of prurigo simplex

A 68-year-old woman with prurigo simplex since 2004, presented to our outpatient itch clinic in 2008 with severe chronic pruritus and a massive reduction in quality of life. Since 2004, the patient had received numerous systemic drugs, including various antihistamines, azathioprine, cyclosporine, gabapentin, and paroxetine, none of which had any significant effect. At that time, no underlying diseases had been identified.

In June 2009, the patient was diagnosed with a fast-growing breast cancer and was enrolled into the GeparQuinto

trial, a neoadjuvant chemotherapy regimen for primary breast cancer (11). Under the study protocol, the patient received 4 3-week cycles of epirubicin (an anthracycline cytostatic agent; 90 mg/m²), cyclophosphamide (an alkylating agent; 600 mg/m²) and bevacizumab (Avastin® Roche, Welwyn Garden City, UK, a humanized anti-VEGF monoclonal antibody; 15 mg/kg), followed by 4 3-week cycles of docetaxel (Taxotere® Sanofi-Aventis, Antony Cedex, France, a taxane chemotherapeutic; 100 mg/m²) and again bevacizumab (15 mg/kg), and subsequently underwent surgery. During chemotherapy, the patient received anti-emetic drugs (ondansetron, a serotonin receptor antagonist and aprepitant, a neurokinin-1-receptor antagonist). The severe pruritus, which constantly had the highest ratings on a verbal rating scale of itch severity, resolved after initiation of this treatment and was almost completely absent throughout the 8 cycles (Fig. 1). The patient reported the return of only mild itch towards the end of each cycle. At the end of the treatment the chronic secondary scratch lesions were virtually absent. After chemotherapy and tumour resection, the patient was considered tumour-free and, to date, has not developed metastasis or tumour recurrence. The pruritus, however, returned to maximal levels within 2 months after the end of docetaxel and bevacizumab treatment, indicating that the control of her chronic pruritus was not due to the anti-tumour effects of the therapy.

We hypothesized that the relief of her pruritus was due to the application of either the anti-VEGF antibody bevacizumab, which was the only drug given throughout the complete 8-cycle chemotherapy regimen, or the anti-emetics ondansetron and aprepitant. We first initiated treatment with ondansetron, which did not reduce itching in our patient. Subsequent treatment with aprepitant, which has been shown previously to be an efficient anti-pruritic drug in some patients (7), also did not improve the pruritus. This indicates that the blockade of VEGF by bevacizumab was likely to

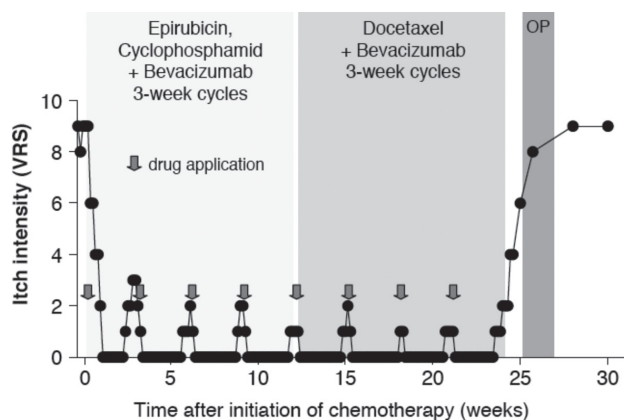


Fig. 1. Suppression of severe chronic pruritus during bevacizumab treatment. Itch intensity was assessed using a verbal rating scale (VRS) ranging from 0 (no itch at all) to 10 (maximum itch imaginable). Itch intensity was assessed retrospectively and thus reflects only an approximate estimation. OP: surgery.

be the cause of the abrogation of pruritus, although a placebo effect cannot be ruled out. We were not able to directly prove that VEGF blockade was responsible for the anti-pruritic effect, as the patient experienced severe, bevacizumab-induced side-effects after the chemotherapy and an additional bevacizumab infusion was contraindicated.

Vascular endothelial growth factor levels are increased in patients with prurigo

To determine whether increased expression of VEGF was detectable in our patient, we analysed VEGF expression in a skin biopsy obtained approximately one year prior to the chemotherapy. Using immunohistochemistry, strong expression of VEGF was detected in lesional epidermis of the patient (Fig. 2a), while only weak staining was observed in non-prurigo control skin (Fig. 2b).

Next, we aimed to characterize further the role and relevance of VEGF in prurigo, and assessed serum levels of VEGF in patients with prurigo in comparison with healthy controls. Overall, 27 inpatients with prurigo nodularis or prurigo simplex with different underlying diseases, such as chronic kidney disease, hepatic diseases, haematological malignancies or unknown causes of pruritus, and 19 healthy individuals were assessed for VEGF serum levels, eosinophilia, and disease activity. Patients with prurigo exhibited 4-fold higher VEGF levels than healthy controls (191.9 ± 38.5 pg/ml vs. 48.7 ± 8.4 pg/ml, $p < 0.001$; Fig. 3a), and VEGF concentrations correlated with levels of physician-assessed disease activity (Fig. 3b). Severity of pruritus alone, as assessed by a patient-based verbal rating scale ranging from 0 (no itch) to 10 (maximal itch imaginable), showed a similar trend, but this correlation did not reach statistical significance (Fig. 3c). While none of the underlying diseases was clearly associated with increased VEGF serum levels, patients with atopy displayed slightly higher VEGF concentrations than those without atopy (315 ± 97 vs. 130 ± 23 , $p < 0.05$; Fig. 3d). As atopic dermatitis is often associated with eosinophilia, and since eosinophils are known to produce

VEGF (12), we hypothesized that eosinophils might be responsible for the elevated VEGF levels. Therefore, we compared VEGF concentrations in patients with or without eosinophilia in the blood and with or without eosinophils in skin tissue. In all patients, the number of eosinophils in the blood ranged from 0.08/nl to 3.39/nl. Counts above 0.85/nl were considered as blood eosinophilia and any occurrence of eosinophils in the skin biopsy was defined as tissue eosinophilia. Overall, we identified some patients with blood (8 of 27, 29.6%) or tissue eosinophilia (5/13, 38.5%) but we did not detect any significant differences in VEGF levels between these groups (Fig. 3e and f). Furthermore, a comparison of patients with prurigo presenting with hyperkeratotic pruritic nodules (prurigo nodularis) and those without (prurigo simplex) revealed no significant differences in VEGF levels between these 2 subtypes.

DISCUSSION

To our knowledge this is the first report indicating that a pharmacological blockade of VEGF might efficiently suppress severe, therapy-refractory pruritus. Our data indicates that VEGF may be an important factor in the pathogenesis of chronic itch, at least in patients with prurigo.

The aetiology of prurigo is largely unknown, and it is still a matter of debate whether it is a separate entity or the result of a vicious circle of itching and scratching originally induced by different pruritogenic stimuli (2). It is possible that the increased VEGF levels detected in the serum of prurigo patients are secondary to skin damage and that VEGF may be involved in the chronic pruritus associated with prurigo, but not in the initial acute pruritus that led to the skin lesions. It has been shown previously that VEGF is constitutively expressed at low levels in epidermal keratinocytes (13, 14), and mechanical manipulation may stimulate keratinocytes to enhance VEGF production. It would therefore be interesting to investigate whether patients with prurigo exhibit increased expression of VEGF and/or VEGF receptor in both lesional and non-lesional skin.

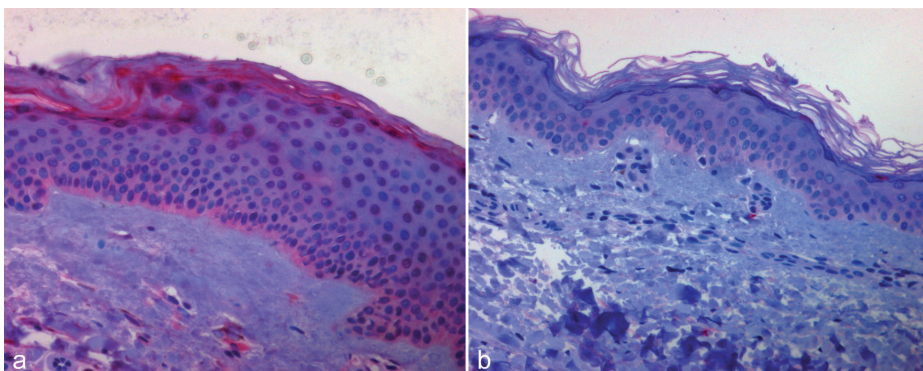


Fig. 2. Increased expression (red colour) of vascular endothelial growth factor (VEGF) in lesional prurigo skin (a) compared to healthy control skin (b).

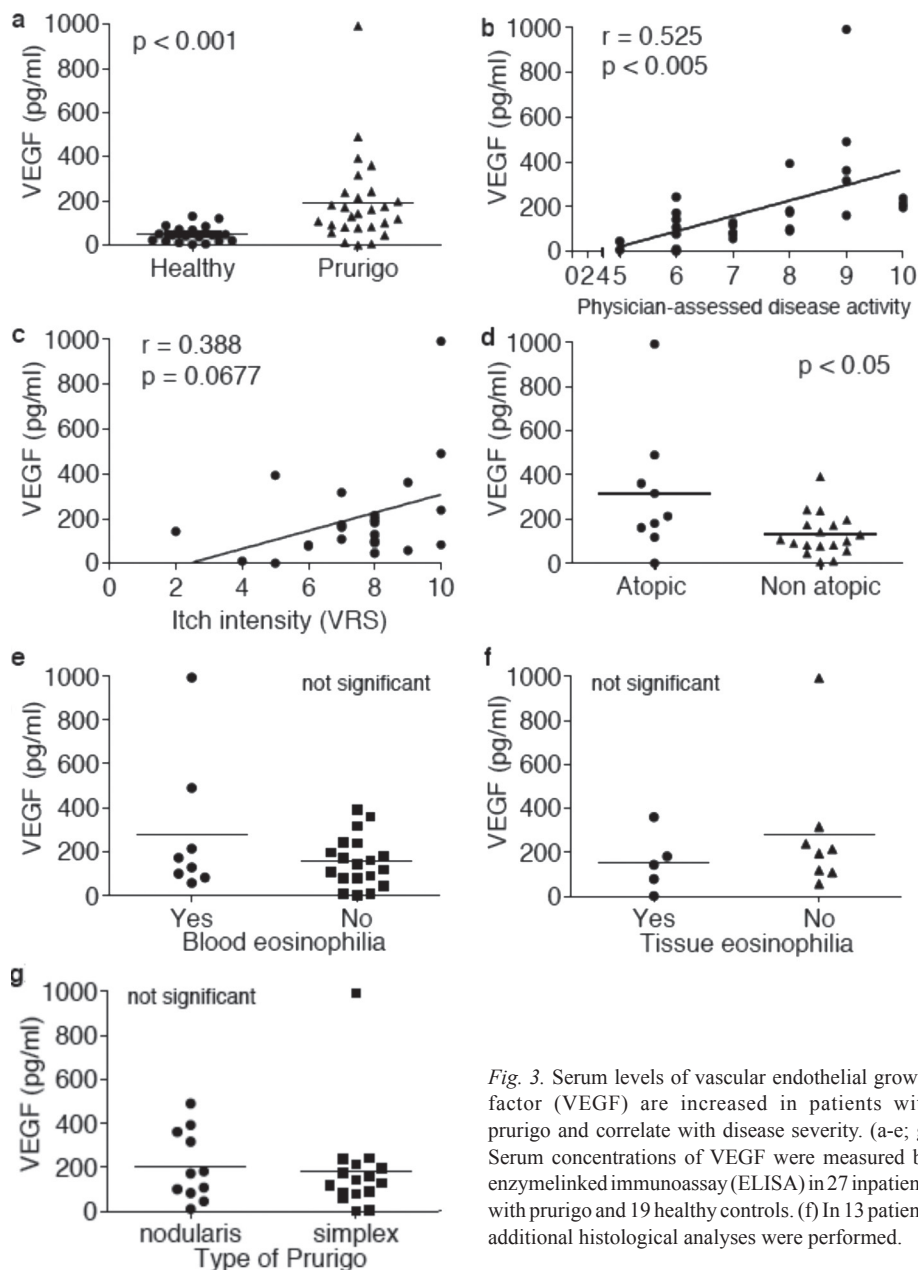


Fig. 3. Serum levels of vascular endothelial growth factor (VEGF) are increased in patients with prurigo and correlate with disease severity. (a-e; g) Serum concentrations of VEGF were measured by enzymelinked immunoassay (ELISA) in 27 inpatients with prurigo and 19 healthy controls. (f) In 13 patients additional histological analyses were performed.

How VEGF might contribute to severe pruritus is currently unknown. It has been postulated that activation of STAT6 by Th2 cytokines and STAT3 by unknown stimuli in the skin of patients is responsible for prurigo symptoms (3). Interestingly, VEGF is a known activator of STAT3 (15) and could therefore represent this unknown factor. Furthermore, VEGF has been shown to induce the production of autotaxin (16). Lysophosphatidic acid, an enzymatic product of autotaxin, has recently been demonstrated to be an important effector in pruritus associated with cholestasis (17). It would therefore be interesting to assess VEGF in these patients and correlate VEGF with autotaxin levels. In other causes of chronic pruritus, such as uraemia, Hodgkin's disease or atopic dermatitis, no increase in autotaxin has been

observed (17); therefore other mechanisms must be relevant in these diseases. It should also be noted that chronic pruritus in other diseases may not be associated with VEGF at all. For example, it was recently reported that pruritus associated with primary myelofibrosis does not correlate with VEGF levels (18). Future studies are necessary to determine whether keratinocytes are the primary source of VEGF or to identify other cellular sources responsible for the elevated VEGF levels in patients with prurigo. Furthermore, the pathomechanisms of VEGF-induced itch require further detailed investigation, and VEGF-mediated effects, i.e. on vasculature, in the skin of patients with prurigo should be characterized. Furthermore, based on our findings, anti-VEGF could present a potential new therapy in prurigo. To this end,

placebo-controlled clinical trials with drugs blocking VEGF activity are required. Apart from the monoclonal antibody bevacizumab, other drugs blocking VEGF or VEGF receptors are currently used in anti-tumour therapy (i.e. the kinase inhibitors sunitinib and sorafenib or the VEGF-trap aflibercept) (8).

ACKNOWLEDGEMENT

This work was funded in part by Dr med. Otto Eppenauer, MD, and Lieselotte Gutzeit Stiftung. We thank Marina Frömming and Sascha Petz for excellent technical assistance.

The authors declare no conflicts of interest.

REFERENCES

1. Ständer S, Weisshaar E, Mettang T, Szepletowski JC, Carstens E, Ikoma A, et al. Clinical classification of itch: a position paper of the International Forum for the Study of Itch. *Acta Derm Venereol* 2007; 87: 291–294.
2. Iking A, Grundmann S, Chatzigeorgakidis E, Phan NQ, Klein D, Stander S. Prurigo as a symptom of atopic and non-atopic diseases: aetiological survey in a consecutive cohort of 108 patients. *J Eur Acad Dermatol Venereol* (in press).
3. Fukushi S, Yamasaki K, Aiba S. Nuclear localization of activated STAT6 and STAT3 in epidermis of prurigo nodularis. *Br J Dermatol* 2011; 165: 990–996.
4. Feldmeyer L, Werner S, Kamarashev J, French LE, Hofbauer GF. Atopic prurigo nodularis responds to intravenous immunoglobulins. *Br J Dermatol* 2012; 166: 461–462.
5. Hammes S, Hermann J, Roos S, Ockenfels HM. UVB 308-nm excimer light and bath PUVA: combination therapy is very effective in the treatment of prurigo nodularis. *J Eur Acad Dermatol Venereol* 2011; 25: 799–803.
6. Metz M, Ständer S. Chronic pruritus – pathogenesis, clinical aspects and treatment. *J Eur Acad Dermatol Venereol* 2010; 24: 1249–1260.
7. Ständer S, Siepmann D, Herrgott I, Sunderkötter C, Luger TA. Targeting the neurokinin receptor 1 with aprepitant: a novel antipruritic strategy. *PLoS One* 2010; 5: e10968.
8. Takahashi S. Vascular endothelial growth factor (VEGF), VEGF receptors and their inhibitors for antiangiogenic tumor therapy. *Biol Pharmaceut Bull* 2011; 34: 1785–1788.
9. Ferrara N, Hillan KJ, Gerber HP, Novotny W. Discovery and development of bevacizumab, an anti-VEGF antibody for treating cancer. *Nature Rev Drug Discovery* 2004; 3: 391–400.
10. Ranpura V, Hapani S, Wu S. Treatment-related mortality with bevacizumab in cancer patients: a meta-analysis. *JAMA* 2011; 305: 487–494.
11. von Minckwitz G, Eidtmann H, Loibl S, Blohmer JU, Costa SD, Fasching PA, et al. Integrating bevacizumab, everolimus, and lapatinib into current neoadjuvant chemotherapy regimen for primary breast cancer. Safety results of the GeparQuinto trial. *Ann Oncol* 2011; 22: 301–306.
12. Horiuchi T, Weller PF. Expression of vascular endothelial growth factor by human eosinophils: upregulation by granulocyte macrophage colony-stimulating factor and interleukin-5. *Am J Respir Cell Mol Biol* 1997; 17: 70–77.
13. Kakurai M, Demitsu T, Umamoto N, Kobayashi Y, Inoue-Narita T, Fujita N, et al. Vasoactive intestinal peptide and inflammatory cytokines enhance vascular endothelial growth factor production from epidermal keratinocytes. *Br J Dermatol* 2009; 161: 1232–1238.
14. Smith JR, Lanier VB, Brazier RM, Falkenhagen KM, White C, Rosenbaum JT. Expression of vascular endothelial growth factor and its receptors in rosacea. *Br J Ophthalmol* 2007; 91: 226–229.
15. Wang H, Byfield G, Jiang Y, Smith GW, McCloskey M, Hartnett ME. VEGF-mediated STAT3 activation inhibits retinal vascularization by down-regulating local erythropoietin expression. *Am J Pathol* 2012; 180: 1243–1253.
16. Ptaszynska MM, Pendrak ML, Stracke ML, Roberts DD. Autotaxin signaling via lysophosphatidic acid receptors contributes to vascular endothelial growth factor-induced endothelial cell migration. *Mol Cancer Res* 2010; 8: 309–321.
17. Kremer AE, Dijk RV, Leckie P, Schaap FG, Kuiper EM, Mettang T, et al. Serum autotaxin is increased in pruritus of cholestasis, but not of other origin and responds to hepatic interventions. *Hepatology* 2012; 56: 1391–1400.
18. Vaa BE, Wolanskyj AP, Roeker L, Pardani A, Lasho TL, Finke CM, et al. Pruritus in primary myelofibrosis: clinical and laboratory correlates. *Am J Hematol* 2012; 87: 136–138.