

Concurrent Cytomegalovirus and Herpes Simplex Virus Infection in Pemphigus Vulgaris Treated with Rituximab and Prednisolone

Hsien-Yi Chiu¹, Chia-Ying Chang¹, Cheng-Hsiang Hsiao² and Li-Fang Wang^{1*}

Departments of ¹Dermatology and ²Pathology, National Taiwan University Hospital and National Taiwan University College of Medicine, 7 Chung-Shan South Road, Taipei 100, Taiwan. *E-mail: lifangwa@ntu.edu.tw

Accepted Apr 22, 2012; Epub ahead of print Aug 23, 2012

Cytomegalovirus (CMV) is a well-known opportunistic infection in immunocompromised hosts (1, 2). Cutaneous CMV infection has rarely been described and has variable clinical presentations (1–3), especially in patients with autoimmune bullous disease.

CASE REPORT

A 76-year-old man presented with a 1-month history of multiple vesicles and erosions. A diagnosis of pemphigus vulgaris was made by histopathology of intraepidermal vesicles, indirect immunofluorescence (IIF) examination of deposition of intercellular substance (ICS) antibody over epidermis (1:160 positive), and enzyme-linked immunosorbent assay (ELISA) of positive desmoglein 1 and 3 antibodies (185 U and 147 U, respectively, MBL, Nagoya, Japan). He was treated initially with oral prednisolone, 90 mg daily, and topical 0.05% clobetasol propionate. We also planned to give 4 doses of weekly rituximab 500 mg infusion, but he received only 2 doses due to rituximab-related anaemia and thrombocytopenia. Subsequently, he had no new blisters and most of the lesions healed gradually. His treatment course was complicated with bacteraemia and pneumonia, and the dose of prednisolone was tapered to 20 mg daily. However, after 6 weeks of oral and topical corticosteroid treatment, the lesions stopped healing and dry, yellowish necrotic tissues were noted on the previous unhealed erosions over his lower back, left shoulder and abdomen (Figs 1A and B).

A skin biopsy from these lesions showed focal suprabasal acantholysis, epidermal ulceration, upper dermal necrosis, and perivascular infiltration of lymphocytes with nuclear dusts. A few enlarged histiocytic cells with large nuclei, some with intranuclear and intracytoplasmic inclusions suggestive of CMV infection were seen in the underlying skin adnexal epithelium (Fig. 2A). In addition, some acantholytic keratinocytes multinucleated with ground glass nuclei and marginated chromatin suggestive of herpes virus infection were found (Fig. 2B). The enlarged histiocytic cells showed positive immunostaining for CMV antigen (Fig. 2C). The swab culture grew herpes simplex virus (HSV)-1, and the tissue culture was negative for CMV and HSV. CMV immunoglobulin G (IgG) was positive, but

CMV IgM was negative. The viral load was 1.63×10^5 copies/ml. He had no evidence of other organ involvement, such as eye, lung, or gastrointestinal tract. The prednisolone dose was tapered to 10 mg daily, and he was put on a 10-day course of valacyclovir, 3 g daily. Serial CMV viral load decreased gradually, and repeated testing for CMV IgM remained negative. His lesions started to re-epithelialize thereafter (Fig. 1C). The time-course of pemphigus disease area index, medications, body surface area of yellowish necrotic tissue, and results of laboratory examination are summarized in Fig. 3.

DISCUSSION

The most common cutaneous presentations of cutaneous CMV are genital, and perianal ulcers (1, 2). The actual incidence of cutaneous CMV is unknown, partly due to non-specific clinical feature and possible false negativity of routine haematoxylin and eosin staining (1). The hosts of previously reported cutaneous CMV have mainly been immunocompromised with human immunodeficiency virus (HIV) infection (3), haematological malignancy, or post-organ-transplantation (2). CMV diseases in patients with autoimmune bullous disease have rarely been reported. Only 2 cases, one CMV-associated gastric ulcer in a patient with pemphigus vulgaris (4) and another patient with bullous pemphigoid developing disseminated CMV disease (5), have been reported.

Co-infection of CMV with other human herpes virus, mostly HSV and varicella-zoster virus (VZV), is common in HIV-positive patients, putting the pathogenetic role of CMV in cutaneous lesions in question (3). However, Choi et al. (2) conducted a study in 9 non-AIDS, immunocompromised patients, which revealed that CMV skin lesions were not highly associated with HSV. They proposed instead that CMV contributes to skin lesions in these patients.

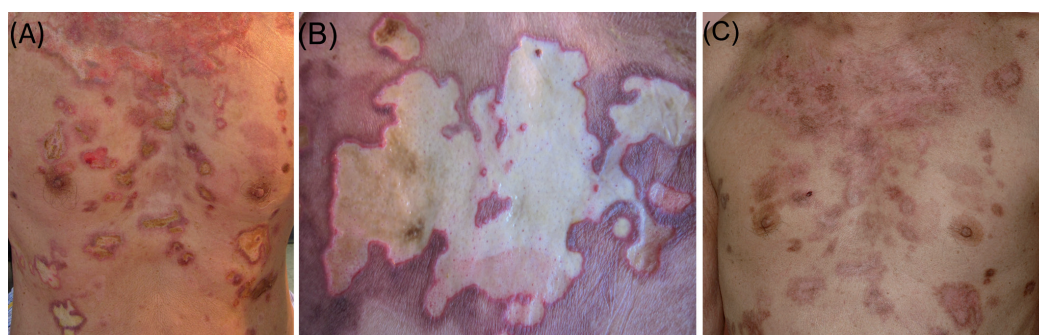

Fig. 1. (A) Several geographic-shaped unhealed ulcers covered with yellowish necrotic tissues on the chest and abdomen. (B) Close-up of one geographic-shaped ulcer on the lower back. (C) Complete re-epithelialization of lesions 3 months later.

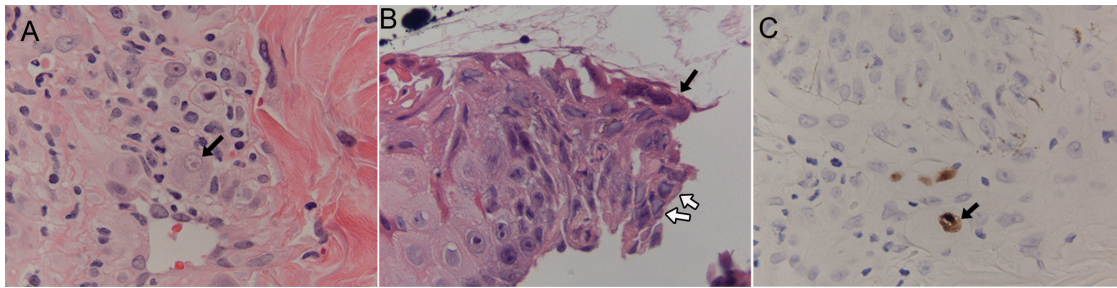


Fig. 2. Concurrent cutaneous cytomegalovirus (CMV) and HSV infections. (A) Markedly enlarged histiocytic cells with intranuclear inclusions and halo formation (owl's eye, black arrow) (haematoxylin and eosin (H&E), original magnification $\times 400$). (B) Multinucleated giant cells (black arrow) and some keratinocytes with ground glass nuclei and margined chromatin (white arrow) in the upper epidermis overhanging ulcer edge (H&E, original magnification $\times 200$). (C) CMV-positive cells in the immunohistochemistry stain (black arrow, original magnification $\times 100$).

Rituximab, a human/mouse chimeric IgG- κ monoclonal antibody directed against the CD20 antigen expressed on most B cells, is widely used to treat B-cell lymphomas, chronic lymphocytic leukaemia, transplant rejection, and various autoimmune diseases (6). CMV reactivation and disease after rituximab has been increasingly recognized (7, 8). In our case, 2 doses of rituximab were administered, but how much the rituximab contributed to the development of CMV infections is difficult to determine. Due to our concern about possible side-effects of cytopenia with ganciclovir, we used acyclovir instead to treat the patient. Acyclovir has been reported only in prophylaxis and not the treatment of CMV infections (9). The patient's lesions began to heal after a 10-day course of valacyclovir treatment, while tapering the dose of prednisolone to 10 mg daily and stopping the use of 0.05% clobetasol propionate ointment completely.

Because frequent use of immunosuppressive treatments and extensive skin barrier defects may facilitate viral infections in patients with autoimmune bullous disorders (10), a sudden resistance to treatment should prompt a search for CMV and/or HSV infections, especially in areas with high seroprevalence of CMV. In Taiwan, the seroprevalence rate of CMV, as determined

by a complement-fixation method, was 95% among adults (11).

REFERENCES

1. Toome BK, Bowers KE, Scott GA. Diagnosis of cutaneous cytomegalovirus infection: a review and report of a case. *J Am Acad Dermatol* 1991; 24: 860–867.
2. Choi YL, Kim JA, Jang KT, Kim DS, Kim WS, Lee JH, et al. Characteristics of cutaneous cytomegalovirus infection in non-acquired immune deficiency syndrome, immunocompromised patients. *Br J Dermatol* 2006; 155: 977–982.
3. Dauden E, Fernandez-Buezo G, Fraga J, Cardenoso L, Garcia-Diez A. Mucocutaneous presence of cytomegalovirus associated with human immunodeficiency virus infection: discussion regarding its pathogenetic role. *Arch Dermatol* 2001; 137: 443–448.
4. Orton DI, Orteu CH, Rustin MH. Cytomegalovirus-associated gastric ulcer in an immunosuppressed patient with pemphigus vulgaris. *Clin Exp Dermatol* 2001; 26: 170–172.
5. Casals DS, Nunes Ede A, Maruta CW, Aoki V, Santi CG, Simonsen Nico MM, et al. Disseminated cytomegalovirus disease as a cause of prolonged fever in a bullous pemphigoid patient under systemic steroid therapy. *J Dermatol* 2003; 30: 332–336.
6. Sharma M, Moore J, Nguyen V, Van Besien K. Fatal CMV pneumonitis in a lymphoma patient treated with rituximab. *Am J Hematol* 2009; 84: 614–616.
7. Lee MY, Chiou TJ, Hsiao LT, Yang MH, Lin PC, Poh SB, et al. Rituximab therapy increased post-transplant cytomegalovirus complications in non-Hodgkin's lymphoma patients receiving autologous hematopoietic stem cell transplantation. *Ann Hematol* 2008; 87: 285–289.
8. Suzan F, Ammor M, Ribrag V. Fatal reactivation of cytomegalovirus infection after use of rituximab for a post-transplantation lymphoproliferative disorder. *N Engl J Med* 2001; 345: 1000.
9. Winston DJ, Yeager AM, Chandrasekar PH, Snyderman DR, Petersen FB, Territo MC. Randomized comparison of oral valacyclovir and intravenous ganciclovir for prevention of cytomegalovirus disease after allogeneic bone marrow transplantation. *Clin Infect Dis* 2003; 36: 749–758.
10. Nikkels AF, Delvenne P, Herfs M, Pierard GE. Occult herpes simplex virus colonization of bullous dermatitides. *Am J Clin Dermatol* 2008; 9: 163–168.
11. Lee PI, Chang MH, Lee CY, Kao CL. Changing sero-epidemiological patterns of cytomegalovirus infection in children in Taiwan from 1984 to 1989. *J Med Virol* 1992; 36: 75–78.

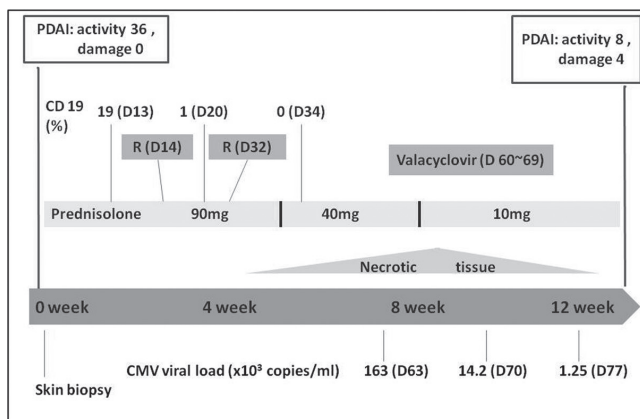


Fig. 3. Clinical course. CMV: cytomegalovirus; D: day; PDAI: pemphigus disease area index; R: rituximab.