

Extensive Chronic *Tuberculosis luposa* Treated Incorrectly with Long-term Course of Isoniazid Monotherapy

Ewa Plomer-Niezgoda¹, Anita Hryniewicz-Gwóźdź^{1*}, Robert Gołąb², Piotr Pluciński², Joanna Maj¹, Zdzisław Woźniak³ and Alina Jankowska-Konsur¹

Departments of ¹Dermatology, Venereology and Allergology and ³Pathomorphology, Wrocław Medical University, Wrocław, Chalubińskiego 1. 50-368 Wrocław, and ²Department of Dermatology, Clinical Military Hospital, Wrocław, Poland. *E-mail: anita.hryniewicz-gwozdz@am.wroc.pl
Accepted May 8, 2012; Epub ahead of print Sep 5, 2012

Tuberculosis (TB) is an infectious disease, its causative agent being Gram-negative, aerobic, acid-fast bacillus *Mycobacterium tuberculosis*, or, less frequently, *M. bovis*. Approximately 10% of patients with AIDS have TB. There are 8.8 million new cases worldwide per year, including 1.4 million fatalities, according to 2010 statistics (1). The WHO's TB estimates for 2015 are 1 billion infections, 200 million people ill, and 35 million fatalities (1, 2). Principally, these numbers reflect case numbers in resource-poor countries, such as in sub-Saharan Africa, where the incidence rate of TB is the highest, at 363/100,000. In the highly developed countries in Europe, the incidence rate is 10.4/100,000. In Poland, in 2009 the incidence rate is 21.6/100,000 (1–3). Apart from pulmonary infections (approximately 92% of all cases), TB may cause pleural effusion, lymph node infections, urinary tract infections and infections of the bone. Tuberculosis of the skin is rare. In Poland it represents <1% of the registered TB cases (3).

CASE REPORT

We describe here a 77-year-old man with extensive changes in the course of TB luposa on the skin of the right upper extremity, the right shoulder area, the chest area, and the right temporal-cheek area. The disease began in 1950, with small brownish-red plaques and enlargement of the nodes in the right armpit. The histopathological diagnosis was TB, to be treated with isoniazid. Following treatment, the skin lesions healed up. After several years, the changes recurred around the right armpit and right arm. Histological study identified recurrent TB. Repeated isoniazid monotherapy continued for 10 years. The patient then gave up the treatment and for over 40 years the lesions spread slowly. In 2009 the patient was registered with newly reported changes on the skin of the left cheek and the left temporal area. Admitted to hospital in 2009, he had sharply demarcated, vast brownish-red plaques with small satellite

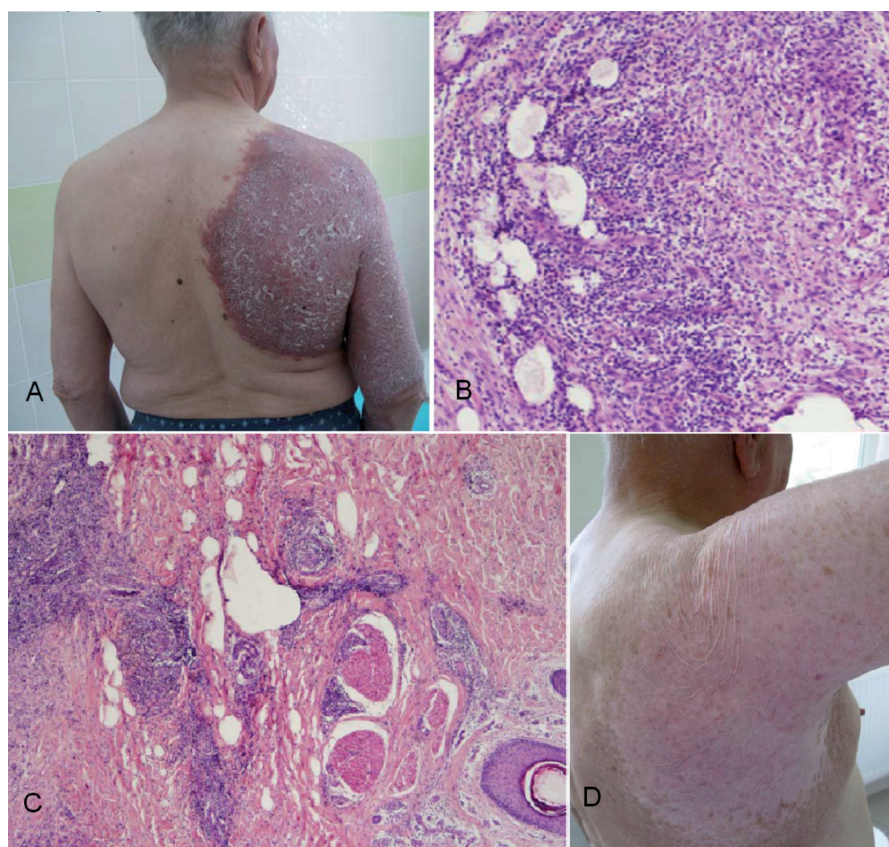


Fig. 1. (A) Sharply demarcated brownish-red plaques on the right upper extremity, right shoulder area. (B) Tuberculoid epithelioid granuloma with histiocytes, multinucleate giant cells and surrounding Langerhans' lymphocytes (haematoxylin and eosin (HE) $\times 100$). (C) Tuberculoid epithelioid granuloma. No neurotropism is observed (HE $\times 40$). (D) Post-treatment status: scars and skin atrophy of the right upper extremity and of the right shoulder area.

lesions on the skin of the right upper extremity, the right shoulder area, the chest area (Fig. 1A), and the right temporal-cheek area. Only slight scarring was observed. Diascopy revealed apple jelly colour. Peripheral lymph nodes were not enlarged. Mucous membranes available for physical examination showed no changes. Slightly elevated values of C-reactive protein (CRP): 8.49 mg/l and angiotensin-converting enzyme (ACE): 44.0 IU/l were observed, with no other deviations. Tests for hepatitis B, hepatitis C and HIV were negative. Imaging studies showed no *M. tuberculosis* infection of the internal organs. Histopathology of the lesion revealed typical TB tissue (Fig. 1B). Tuberculin skin test (PPD) showed 10 mm induration. *M. tuberculosis* was detected by polymerase chain reaction (PCR) (Gen Probe MTD). Bacterioscopy and Bactec 9000 MB of acid-fast mycobacteria were negative. There were no cases of TB in the patient's immediate family. After TB luposa had been diagnosed, combined isoniazid-rifampicin-ethambutol treatment was recommended for 12 months. Subsequently, the skin changes resolved completely, leaving scars and post-inflammatory hypopigmentation (Fig. 1D).

DISCUSSION

In Poland, TB of the skin is rare, representing <1% of all TB cases (3). The duration of the disease in our patient was 61 years. He had extensive skin lesions. Despite long, repeated isoniazid monotherapy (the first time for a few months and the second time for over 10 years) he was not completely cured. After this period, the treatment was interrupted and in the last 40 years the disease had progressed slowly. As the skin lesions were without intensive scarring, so not very typical of TB, family doctors may have suspected other dermatoses, such as psoriasis. The peripheral lymph nodes were not enlarged, precluding correct diagnosis. When the skin lesions appeared on the face, the patient sought dermatological help again. The skin symptoms, positive diascopy, positive tuberculin skin test (PPD), histopathological examination and positive DNA amplification test allowed us to diagnose TB luposa. Diagnosis of TB luposa is difficult, as the results of bacteriological tests are usually negative. Tuberculin test, histopathological examination, interferon release test and DNA amplification test are very important diagnostic tools in such cases (4–6). The results of the tuberculin test are considered positive when the infiltration is 5–15 mm in diameter. In our patient, the infiltration was 10 mm in diameter and the test result was positive. However, in a BCG-vaccinated population, as in Poland, a positive tuberculin skin test may be caused by vaccination. For that reason, a DNA amplification test was performed and *M. tuberculosis* infection was confirmed. The interferon

release test was not performed. Taking the diagnostic possibilities into consideration, tuberculoid leprosy was ruled out. The patient did not travel abroad and leprosy cases are not recorded in Poland. In histopathological examination the nerve structures within the granuloma were not fragmented in our case (Fig. 1C), while such fragmentation is observed in patients with leprosy. Diagnosis of TB and proper treatment are vital in the global fight against TB. In recent years, the number of patients with multidrug-resistant tuberculosis (MDR-TB), caused by bacterial strains resistant to at least isoniazid and rifampicin, has increased. In Europe this problem is observed mainly in eastern European countries (7). The world frequency rate of MDR-TB in all new TB cases is approximately 2.9% (7). In Poland 7% of TB cases were recorded as caused by drug-resistant strains (8). Inadequate treatment of TB contributes to the development of drug-resistant *M. tuberculosis* strains. In the 1950s our patient underwent isoniazid treatment. The lack of therapeutic effect of this treatment is not remarkable. Drug-resistance to isoniazid should be used in combination with other TB drugs. The combined isoniazid-rifampicin-ethambutol treatment was introduced in 2009 when the lesions were very extensive. The treatment was extended to 12 months and total recovery was achieved. No recurrence has been observed in 2 years since the treatment. Total recovery after one year of combination therapy proved that the diagnosis was correct.

REFERENCES

1. World Health Organization global tuberculosis control report 2010 summary. *Cent Eur J Public Health* 2010; 18: 237.
2. Dye C. Global epidemiology of tuberculosis. *Lancet* 2006; 367: 938–940.
3. Korzeniewska-Koseła M. Tuberculosis in Poland 2009. *Przegl Epidemiol* 2011; 65: 301–305.
4. Tan S, Tan B, Goh C. Detection of *Mycobacterium tuberculosis* DNA using polymerase chain reaction in cutaneous tuberculosis and tuberculids. *Int J Dermatol* 1999; 38: 122–127.
5. Silva RM, Bazzo M, Chagas M. Quality of sputum in the performance of polymerase chain reaction for diagnosis of pulmonary tuberculosis. *Braz J Infect Dis* 2010; 14: 116–120.
6. Lai C, Tan C, Lin S, Liu W, Liao C, Huang Y, Hsueh P. Diagnostic value of an enzyme-linked immunospot assay for interferon-gamma in cutaneous tuberculosis. *Diagn Microbiol Infect Dis* 2011; 70: 60–64.
7. World Health Organization. Anti-tuberculosis resistance in the world. Report no. 4. Geneva: WHO/HTM/TB/2008. 394.
8. Zwolska Z, Augustynowicz-Kopeć E, Klatt M. Primary and acquired drug resistance surveillance in Polish tuberculosis patient – results of study of the national drug resistance. Surveillance programme. *Int J Tuberc Lung Dis* 2000; 4: 832–838.