

Cutaneous Disseminated Sporotrichosis Complicated by Osteomyelitis

Karen E. Eustace¹, Felipe M. S. Sampaio², Marcelo R. Lyra², Leonardo Quintella² and Antonio C. F. do Valle²

¹Department of Dermatology, Mater Misericordiae University Hospital, Eccles St, Dublin 7, Ireland, and ²Evandro Chagas Clinical Research Institute, Fiocruz, Rio de Janeiro, Brazil. E-mail: kareneustace@physicians.ie
Accepted April 10, 2012.

Sporotrichosis is caused by a dimorphic fungus, *Sporothrix schenckii*, which exists in the environment in soil and decaying vegetable matter contaminated by the fungus (1). It favours tropical and subtropical climate zones and is the cause of the most common subcutaneous mycosis in South America. Zoonotic transmission is rare worldwide, but in Brazil epidemics of sporotrichosis have been reported in humans who have been in close contact with infected cats (2).

The mode of transmission is via cutaneous inoculation of the organism. We report here a rare case of osteoarticular sporotrichosis in a previously healthy 39-year-old woman, who was living in a shanty town in Rio de Janeiro, Brazil.

CASE REPORT

The patient initially presented to our dermatology outpatient clinic in March 2010 with painful papules and nodules on the dorsal aspect of her left foot. Sporotrichosis was confirmed with serology and culture. She was commenced on itraconazole 200 mg daily for treatment of lymphocutaneous sporotrichosis, the most common presentation of the disease. She re-presented to our clinic 12 months later with very poor compliance. The condition had progressed considerably and she was cachectic. She was otherwise previously well with no past medical history of note. Ulcerated and exudative nodules were now more extensive, profoundly tender and involved her entire left lower limb (Fig. 1a), extending to her groin, abdomen, back and left upper arm. Her presentation was complicated by tissue destruction of her left fifth digit (Fig. 1b).

The Gomori-Grocott technique and periodic acid-Schiff (PAS) staining showed sparse rounded fungal forms characteristic of sporotrichosis. A plain film radiograph of her left foot revealed thinning of the fifth metatarsal and an increase in the surrounding soft tissue. A computed tomography scan of her left foot and tibia showed underlying osteomyelitis and a deep abscess, which was subsequently drained.

The patient was treated successfully with intravenous amphotericin B for 16 days and liposomal amphotericin for 6 days.

She was prescribed a maintenance dose of 200 mg itraconazole twice daily, and to date is showing a good clinical response.

DISCUSSION

The cutaneous and lymphocutaneous forms of sporotrichosis are the most common forms of presentation, and patients usually remain afebrile and systemically well. Rarely, sporotrichosis can disseminate to involve bone, muscle, lungs and the central nervous system (3). This is predominantly observed in immunocompromised individuals (4). The osteoarticular form is the most commonly affected site after skin and can spread via direct inoculation of the fungus or haematogenously. It can involve single or multiple joints or bones. The most commonly affected bones are the tibia, small bones of the hands, radius, ulna, knee and ankle (5). An increasing number of fungal bone and joint infections has been reported (6). Freitas et al. (7) reported 2 cases of osteomyelitis in a study of 21 HIV-infected patients (8). Treatment options include itraconazole or amphotericin, which is less well tolerated and is associated with frequent relapses (9). Appenzeller et al. (5) reported 2 cases of sporotrichosis monoarthritis affecting the knees, which were successfully treated with itraconazole. Itraconazole is administered at initial doses of 200 mg twice daily for at least 12 months, followed by a maintenance dose of 200 mg daily (9). Govender et al. (10) noted that in localized osseous fungal lesions, surgical debridement alone without antifungal agents results in satisfactory outcome.

This case represents a rare presentation of osteomyelitis in an immunocompetent patient with cutaneous disseminated sporotrichosis. It demonstrates both an aggressive clinical evolution of the disease with osteoarticular destruction and a challenge to successful medical treatment.

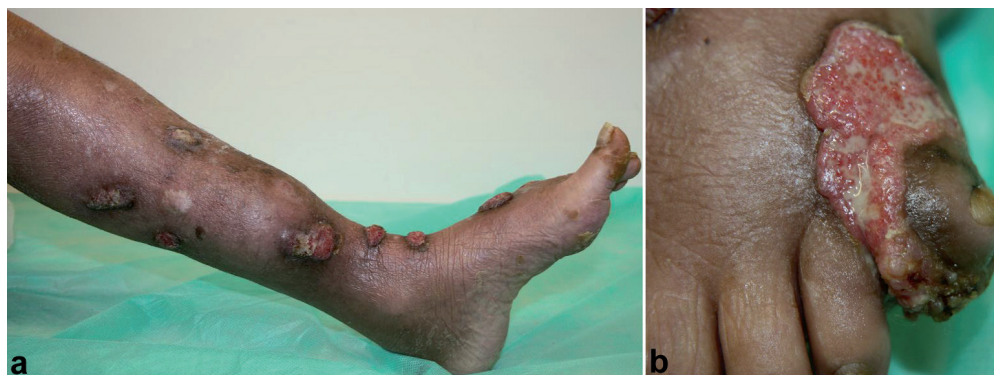


Fig. 1. (a) Multiple ulcerated papules and nodules on the left lower limb extending along the lymphatic channels. (b) Left fifth digit with marked ulceration and destruction of the underlying bone structure.

The authors declare no conflicts of interest.

REFERENCES

1. Zhang YQ, Xu XG, Zhang M, Jiang P, Zhou XY, Li ZZ, et al. Sporotrichosis: clinical and histopathological manifestations. *Am J Dermatopathol* 2011; 33: 296–302.
2. Barros MB, Schubach Ade O, do Valle AC, Gutierrez Galhardo MC, Conceição-Silva F, Schubach TM, et al. Cat-transmitted sporotrichosis epidemic in Rio de Janeiro, Brazil: description of a series of cases. *Clin Infect Dis* 2004; 38: 529–535.
3. Badley AD, Van Scoy RE. Long term follow-up of multifocal osteoarticular sporotrichosis treated with itraconazole. *Clin Infect Dis* 1996; 23: 394–395.
4. Edwards C, Reuther WL 3rd, Greer DL. Disseminated osteoarticular sporotrichosis: treatment in a patient with acquired immunodeficiency syndrome. *South Med J* 2000; 93: 803–806.
5. Appenzeller S, Amaral TN, Amstalden EM, Bertolo MB, Neto JF, Samara AM, et al. Sporothrix schenckii infection presented as monoarthritis: report of two cases and review of the literature. *Clin Rheumatol* 2006; 25: 926–928.
6. Howell SJ, Toohey JS. Sporotrichal arthritis in south central Kansas. *Clin Orthop Relat Res* 1998; 346: 207–214.
7. Freitas DF, de Siqueira Hoagland B, do Valle AC, Fraga BB, de Barros MB, de Oliveira Schubach A, et al. Sporotrichosis in HIV-infected patients: report of 21 cases of endemic sporotrichosis in Rio de Janeiro, Brazil. *Med Mycol* 2012; 50: 170–178.
8. Gutierrez-Galhardo MC, do Valle AC, Fraga BL, Schubach AO, Hoagland BR, Monteiro PC, et al. Disseminated sporotrichosis as a manifestation of immune reconstitution inflammatory syndrome. *Mycoses* 2010; 53: 78–80.
9. Kauffman CA, Bustamante B, Chapman SW, Pappas PG. Clinical practice guidelines for the management of sporotrichosis: 2007 update by the Infectious Diseases Society of America. *Clin Infect Dis* 2007; 45: 1255–1265.
10. Govender S, Rasool MN, Ngcelwane M. Osseous sporotrichosis. *J Infect* 1989; 19: 273–276.