

Prostaglandin E2 Increase in Pachydermoperiostosis Without 15-hydroprostaglandin Dehydrogenase Mutations

Kyoko Nakahigashi¹, Atsushi Otsuka^{1*}, Hiromi Doi¹, Satsuki Tanaka², Yoshiaki Okajima³, Hironori Niizeki⁴, Asami Hirakiyama⁴, Yoshiki Miyachi¹ and Kenji Kabashima^{1*}

¹Department of Dermatology, Kyoto University, Graduate School of Medicine, 54 Shogoin-Kawara, Sakyo, Kyoto 606-8507, ²Department of Diabetes and Endocrinology, and ³Department of Orthopedic Surgery, Osaka Saiseikai Nakatsu Hospital, Osaka, and ⁴Department of Dermatology, National Center for Child Health and Development, Tokyo, Japan. *E-mails: otsukamn@kuhp.kyoto-u.ac.jp, kaba@kuhp.kyoto-u.ac.jp
Accepted April 10, 2012.

Pachydermoperiostosis (PDP), a form of primary hypertrophic osteoarthropathy (PHO), is a rare hereditary disease diagnosed by the presence of the triad of digital clubbing, periostosis, and pachydermia (1, 2). Elevated prostaglandin E2 (PGE2) levels with cytokine-mediated tissue remodelling and vascular stimulation may underlie PHO and is associated with the features such as hyperhidrosis, acroosteolysis, pachydermia, periostosis and arthritis (3). Homozygous and compound heterozygous germline mutations in the 15-hydroxyprostaglandin dehydrogenase (HPGD) gene encoding the major PGE2 catabolizing enzyme have been described in familial PHO cases (4). We report here a case of primary PDP with increased serum PGE2 levels that was not accompanied by HPGD mutations.

CASE REPORT

A 53-year-old man was referred to our hospital. He began to experience idiopathic symmetrical arthralgias of both knees at around 20 years of age. Physical examination revealed thickened skin on the face and

head, and marked clubbing of the fingers (Fig. 1a, b). No other remarkable physical findings were observed, and he did not present seborrhoea, acne, folliculitis or hyperhidrosis. Family history was non-contributory. All laboratory tests including serum levels of growth hormone, insulin-like growth factor-1, thyroid function, immunoglobulins, haemoglobin A1c, and bone mineral metabolism were within normal ranges, which ruled out thyroid acropathy and acromegaly. Magnetic resonance imaging of the head revealed cutis verticis gyrate (Fig. 1c). X-ray examination of the knee region revealed periostosis with cortical thickening and ectopic ossification (Fig. 1d). Histology of the forehead skin revealed acanthosis in the epidermis, sebaceous and sweat gland enlargement, and mucin deposits in the dermis (Fig. 2). These findings met the diagnostic criteria of the complete form of PDP.

Since it has been reported that PGE2 is a mediator of this disorder, we examined PGE2 levels using a commercial enzyme immunoassay kit (Cayman, Cayman Biochemical, Ann Arbor, MI, USA). Consistent with the previous reports, PGE2 levels were elevated in plasma (401 pg/ml, normal 3–12) and urinary (6,086 ng/mmol creatinine, normal < 50). Intriguingly, mutational analysis using genomic DNA that was isolated from the peripheral blood did not detect HPGD mutations.

DISCUSSION

Mutations in HPGD have been identified in 4 families affected with PHO and in a single family with isolated congenital nail clubbing as an autosomal-recessive trait (4, 5). Impaired metabolism of PGE2 is considered critical in the pathogenesis of PHO. However, in our case, no mutations in HPGD were detected despite the elevated PGE2 levels. These findings suggest that another contributing factor may affect the PGE2 increase. Consistent with our findings, a report exists of a familial case of autosomal-dominant isolated digital clubbing without any mutations in HPGD (6). Furthermore, Seifert et al. (7) found another mutation in PG transporter (PGT) encoding gene, *SLCO2A1*, which presumably results in reduced metabolic clea-

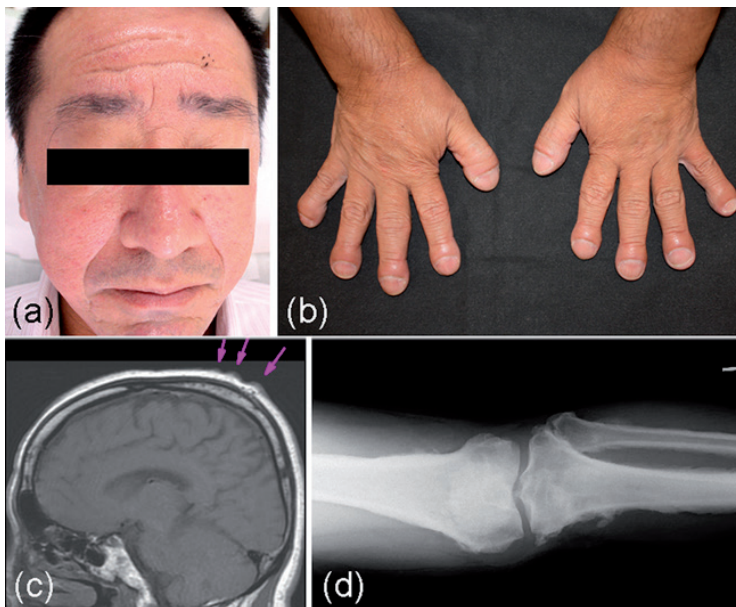


Fig. 1. Clinical findings. (a) Thickening and furrowing of the skin of the forehead. (b) Terminal broadening of the fingers. (c) Folds of the vertex scalp as revealed by magnetic resonance imaging (sagittal image of the head). (d) X-radiograph showing periosteal hyperostosis of the knee region.

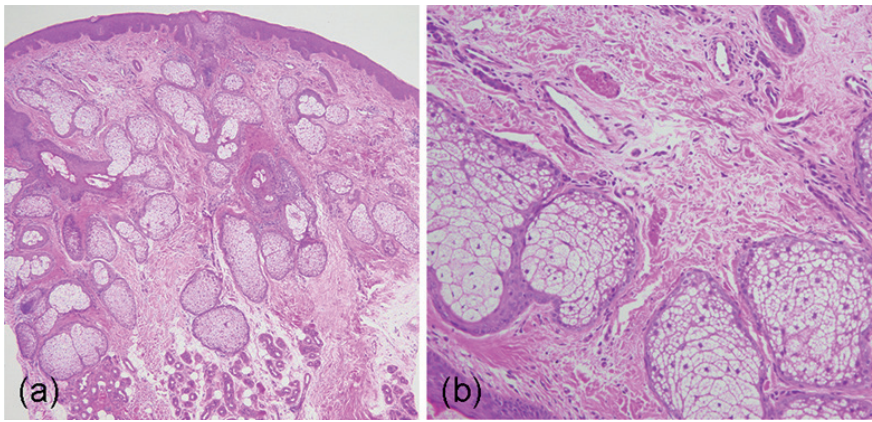


Fig. 2. Histological findings of the forehead skin revealed acanthosis in the epidermis, enlargement of sebaceous glands and sweat glands, and mucin deposits in the dermis (haematoxylin and eosin; original magnification (a) $\times 4$ and (b) $\times 200$).

rance of PGE₂ due to impaired cellular uptake of PGE₂ by mutant PGT. Considering that PGE₂ is a ubiquitous lipid mediator generated from membrane stores of arachidonic acid by the sequential actions of a number of enzymes, including cyclooxygenases and PGE synthases, the mutations in those enzymes may be candidates for the causative genes in its aetiology.

Thus far, only a few cases of PDP have been reported and its aetiopathogenesis has not yet been fully clarified. We report here a case of PDP with elevated PGE₂ levels with no associated HPGD mutations. Our findings suggest that this disorder may be induced by other mechanisms such as *SLCO2A1* and Wnt signalings (8), which is now under investigation. Considering the elevated PGE₂ levels in PDP and the effect of non-steroidal anti-inflammatory drugs (NSAIDs) on alleviation of pain caused by periostosis and arthritis, NSAIDs might be a possible therapy.

The authors declare no conflicts of interest.

REFERENCES

1. Rimoin DL. Pachydermoperiostosis (idiopathic clubbing and periostosis): genetic and physiologic considerations. *N Engl J Med* 1965; 272: 923–931.
2. Castori M, Sinibaldi L, Mingarelli R, Lachman RS, Rimoin DL, Dallapiccola B. Pachydermoperiostosis: an update. *Clin Genet* 2005; 68: 477–486.
3. Bergmann C, Wobser M, Morbach H, Falkenbach A, Wittenhagen D, Lassay L, et al. Primary hypertrophic osteoarthropathy with digital clubbing and palmoplantar hyperhidrosis caused by 15-PGHD/HPGD loss-of-function mutations. *Exp Dermatol* 2011; 20: 531–533.
4. Uppal S, Diggle CP, Carr IM, Fishwick CW, Ahmed M, Ibrahim GH, et al. Mutations in 15-hydroxyprostaglandin dehydrogenase cause primary hypertrophic osteoarthropathy. *Nat Genet* 2008; 40: 789–793.
5. Tariq M, Azeem Z, Ali G, Chishti MS, Ahmad W. Mutation in the HPGD gene encoding NAD⁺ dependent 15-hydroxyprostaglandin dehydrogenase underlies isolated congenital nail clubbing (ICNC). *J Med Genet* 2009; 46: 14–20.
6. Seifert W, Beninde J, Hoffmann K, Lindner TH, Bassir C, Aksu F, et al. HPGD mutations cause cranioosteopathy but not autosomal dominant digital clubbing. *Eur J Hum Genet* 2009; 17: 1570–1576.
7. Seifert W, Kuhnisch J, Tuysuz B, Specker C, Brouwers A, Horn D. Mutations in the prostaglandin transporter encoding gene *SLCO2A1* Cause primary hypertrophic osteoarthropathy and isolated digital clubbing. *Hum Mutat* 2012; 33: 660–664.
8. Kabashima K, Sakabe J, Yoshiki R, Tabata Y, Kohno K, Tokura Y. Involvement of Wnt signaling in dermal fibroblasts. *Am J Pathol* 2010; 176: 721–732.