

Successful Therapeutic Use of Targeted Narrow-band Ultraviolet B Therapy for Refractory Hailey-Hailey Disease

Toshihisa Hamada, Hiroshi Umemura, Yumi Aoyama and Keiji Iwatsuki

Department of Dermatology, Okayama University Graduate School of Medicine, Dentistry, and Pharmaceutical Sciences, 2-5-1 Shikata-cho, Okayama 700-8558, Japan. E-mail: t-hamada@cc.okayama-u.ac.jp

Accepted March 25, 2012.

Hailey-Hailey disease (HHD) is an autosomal dominant inherited disorder characterized by suprabasal acantholysis of the epidermis. In patients with HHD, itch and pain are common, with recurrent erosive erythema predominantly on the flexural areas, and quality of life may be reduced (1, 2). Treatment recommendations include the avoidance of skin friction and retention of a dry environment in the flexural area. Topical corticosteroids are usually effective only with concomitant use of antibacterial and/or antifungal agents. In some cases, however, those topical treatments may have no beneficial effect. Several new therapeutic approaches have been reported to be effective, although they lack an adequate evidence base obtained from controlled trials (3–7). While ultraviolet (UV) light may induce acantholysis in the epidermis in patients with HHD, previous investigators have been successful with the use of phototherapy (8). However, a major drawback of this treatment is the anatomical difficulty of full irradiation in the flexural area. Thus, a novel approach using Excimer irradiation, has been tested.

CASE REPORT

In July 2010, a 40-year-old man first experienced itching and burning sensation of the genitoperineal area. In October 2010, topical corticosteroid twice daily was started, resulting in some improvement for a short period. In December 2010, oral prednisone, 10 mg daily, was added with no efficacy. In January 2011, he was referred to us for 6-month history of recurrent erosion and fissure formation of the inguinal, perineal and perianal area (Fig. 1A). His medical and familial histories were not contributing factors. His body weight was 55 kg with-

out obesity (body mass index 22.6 kg/m²). Histopathological findings of the biopsy specimen from the inguinal erythema showed marked acanthosis, with suprabasal acantholysis and dyskeratotic keratinocytes in the epidermis, and dense lymphoid cell infiltration in the superficial dermis (Fig. 1B). Direct immunofluorescence study of the biopsy specimen showed no immune deposits in the intercellular spaces of the epidermis. Based on these findings, a diagnosis of Hailey-Hailey disease (HHD) was made. Although *Candida albicans* was detected on the inguinal erosive lesions, a 2-month treatment with topical corticosteroid twice daily and antifungal agent once daily showed no efficacy. In February 2011, oral etretinate 20 mg daily was added, resulting in no beneficial response. The skin lesions were confined to the flexural areas of the inguinal, perineal and perianal areas, and caused intractable exercise-induced pain, which interfered with his daily physical activity. The score on a 100-mm visual analogue pain intensity scale (VAS) was 82.

In March 2011, the patient underwent targeted narrow-band UVB therapy using the VTRAC Excimer Lamp system (Photo-Medex, Montgomeryville, PA, USA), for the purpose of resolving the weak point of the conventional UV irradiation system. This system, using a handheld instrument, enables the physician to treat the recalcitrant lesions on flexural or folded surfaces. The minimum erythematous dose (MED) was 300 mJ/cm². The therapy was performed 2–3 times a week at an initial irradiation dose of 100 mJ/cm². The dose was increased by 20 mJ/cm² at each visit, and reached 200 mJ/cm² 8 weeks after the start of treatment. In August 2011 (the summer season), the cumulative fluorescent dose was 7,850 mJ/cm², and erythemas were reduced considerably, with relief of exercise-induced pain of the flexural areas (Fig. 2A). A skin biopsy was then performed to verify the efficacy of the therapy histopathologically. Epidermal acanthosis and dermal inflammatory infiltrates were significantly reduced after treatment (Fig. 2B). After 8 months of treatment, the frequency of irradiation was successfully reduced to every second week, with no exacerbation of HHD, and the score on the 100-mm VAS was markedly decreased to 5, a reduction of 94%.

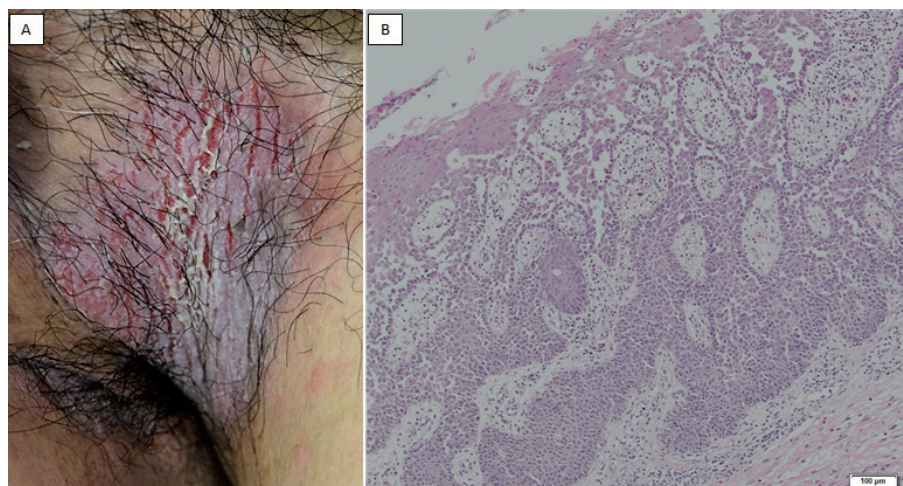


Fig. 1. (A) Clinical picture before excimer light therapy. Multiple fissures and erosions of the inguinal area on a macerated erythematous base. (B) Histopathological findings showed marked acanthosis, with suprabasal acantholysis and dyskeratotic keratinocytes in the epidermis, and numerous lymphoid cells in the superficial dermis. The depth of the epidermis was 0.92 mm, and the density of the infiltrating lymphoid cells in the dermis was $1.2 \times 10^5/\text{mm}^2$.

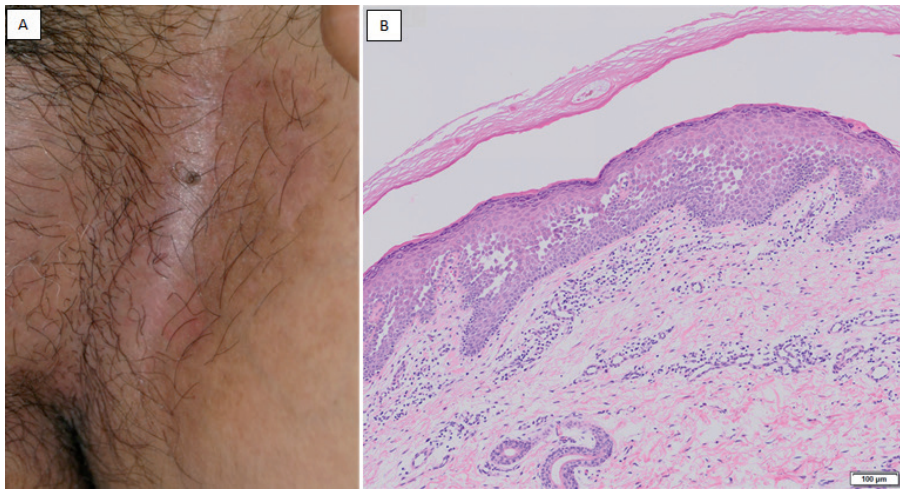


Fig. 2. (A) Clinical picture after excimer light therapy. Erythemas were reduced considerably, with relief of exercise-induced pain. (B) Histopathologically, epidermal acanthosis and dermal inflammatory infiltrates were markedly reduced after treatment. The depth of the epidermis was 0.28 mm, and the density of the infiltrating lymphoid cells in the dermis was $0.4 \times 10^5/\text{mm}^2$, with reductions of 70% and 67%, respectively.

DISCUSSION

HHD is a recurrent erosive erythema occurring predominantly in flexural areas, with an autosomal dominant inheritance caused by mutation of ATP2C1 (OMIM 604384) localized on chromosome 3q22.1, which encodes the human secretory-pathway $\text{Ca}^{2+}/\text{Mn}^{2+}$ -ATPase isoform 1 (hSPCA1) (9, 10). The skin manifestations usually occur in the third or fourth decade of life (1). Histopathological features are characterized by suprabasal acantholysis with various degrees of acanthosis and scattered dyskeratotic keratinocytes in the epidermis. In our case, topical treatment including corticosteroid and antifungal agent was not effective, with the patient experiencing progressive pain in the groin area. Oral prednisone and etretinate had no beneficial effect. Thereafter, excimer light therapy provided a favourable clinical course, with significant decrease in epidermal acanthosis and dermal infiltrating lymphocytes histopathologically. Even in summer, the disease was well-controlled by the therapy, with no recurrence. Usually, UV exacerbates HHD, and the expression of ATP2C1 mRNA in cultured normal human keratinocytes was reported to be suppressed immediately after exposure to UVB (11). However, the impairment of the adhesion of cultured keratinocytes from HHD patients induced by UVB irradiation has not proved to be more pronounced than in normal keratinocytes (12). Clinically, phototherapies have been reported as effective in some patients with refractory HHD (8). In psoriasis, the major phototherapeutic effect of topical UV irradiation is thought to be the induction of apoptosis in the lesional infiltrating T cells (13). Also, in our case, dermal inflammatory infiltrates were significantly decreased by the excimer light therapy, with clinical improvement of the disease. This case suggests that targeted narrow-band UVB therapy may be an effective therapy for refractory skin disease of patients with HHD, especially those with lesions in flexural areas.

The authors declare no conflicts of interest.

REFERENCES

- Burge SM. Hailey-Hailey disease: the clinical features, response to treatment and prognosis. *Br J Dermatol* 1992; 126: 275–282.
- Harris A, Burge SM, Dykes PJ, Finlay AY. Handicap in Darier's disease and Hailey-Hailey disease. *Br J Dermatol* 1996; 135: 959–963.
- Fernández Guarino M, Ryan AM, Harto A, Pérez-García B, Arrázola JM, Jaén P. Experience with photodynamic therapy in Hailey-Hailey disease. *J Dermatolog Treat* 2008; 19: 288–290.
- Awadalla F, Rosenbach A. Effective treatment of Hailey-Hailey disease with a long-pulsed (5 ms) alexandrite laser. *J Cosmet Laser Ther* 2011; 13: 191–192.
- Koeyers WJ, Van Der Geer S, Krekels G. Botulinum toxin type A as an adjuvant treatment modality for extensive Hailey-Hailey disease. *J Dermatolog Treat* 2008; 19: 251–254.
- Dammak A, Camus M, Anyfantakis V, Guillet G. Successful treatment of Hailey-Hailey disease with topical 5-fluorouracil. *Br J Dermatol* 2009; 161: 967–968.
- Pissoat L, Höller Obrigkeit D. Benign familial chronic pemphigus (Hailey-Hailey disease). Treatment with carbon dioxide laser. *Hautarzt* 2011; 62: 258–261.
- Hayakawa K, Shiohara T. Coexistence of psoriasis and familial benign chronic pemphigus: efficacy of ultraviolet B treatment. *Br J Dermatol* 1999; 140: 374–375.
- Hu Z, Bonifas JM, Beech J, Bench G, Shigihara T, Ogawa H, et al. Mutations in ATP2C1, encoding a calcium pump, cause Hailey-Hailey disease. *Nat Genet* 2000; 24: 61–65.
- Sudbrak R, Brown J, Dobson-Stone C, Carter S, Ramser J, White J, et al. Hailey-Hailey disease is caused by mutations in ATP2C1 encoding a novel Ca^{2+} pump. *Hum Mol Genet* 2000; 9: 1131–1140.
- Mayuzumi N, Ikeda S, Kawada H, Ogawa H. Effects of drugs and anticytokine antibodies on expression of ATP2A2 and ATP2C1 in cultured normal human keratinocytes. *Br J Dermatol* 2005; 152: 920–924.
- Bernards M, Korge BP. Desmosome assembly and keratin network formation after Ca^{2+} /serum induction and UVB radiation in Hailey-Hailey keratinocytes. *J Invest Dermatol* 2000; 114: 1058–1061.
- Ozawa M, Ferenczi K, Kikuchi T, Cardinale I, Austin LM, Coven TR, et al. 312-nanometer ultraviolet B light (narrow-band UVB) induces apoptosis of T cells within psoriatic lesions. *J Exp Med* 1999; 189: 711–718.