

Penile Erosions as First Manifestation of Pemphigus Vulgaris: A Misleading Presentation

Marco Stieger¹, Nedzmidin Pelivani¹, Albert-Adrien Ramelet^{1,2}, Helmut Beltraminelli¹ and Luca Borradori¹

¹Department of Dermatology, Inselspital, University Hospital Bern, CH-3010 Bern, and ²Private Practice of Dermatology and Angiology FMH, Lausanne, Switzerland. E-mail: luca.borradori@insel.ch

Accepted March 25, 2012.

Pemphigus vulgaris (PV) is a potentially devastating autoimmune bullous disease that affects the mucosa and skin. It is characteristically associated with intra-epidermal blistering and cell–cell dissociation due to the presence of autoantibodies targeting desmoglein (dsg) 3 and dsg 1, i.e. transmembrane adhesion molecules of the desmosomal cadherin protein family (1–3). In most patients, PV characteristically starts with and affects the oral mucosa, although involvement of other mucosae may also occur (4–10). We have recently observed 2 patients, in whom the first clinical manifestation of PV consisted of chronic painful penile erosions, which represented a diagnostic challenge.

CASE REPORTS

Case 1. A 59-year-old man presented with painful penile erosions of 3-months duration. Microbiological cultures and serology for *Treponema pallidum* were negative. Under treatment with local antibiotics and disinfectants the erosive lesions further progressed and affected the entire glans penis and part of the shaft. Only after the patient developed painful aphthoid lesions in the oral mucosa, was a biopsy specimen from the oral mucosa obtained, which showed suprabasal blistering with acantholysis. Direct immunofluorescence studies of perilesional oral mucosa demonstrated intercellular epithelial deposits of immunoglobulin G (IgG) and complement (C3). Enzyme-linked immunoassay-desmoglein 3 (ELISA-dsg 3) (136 U/ml, normal <7) and ELISA-dsg 1 (62 U/ml, normal <14) were both positive. The patient was first given prednisone 0.5 mg/kg body weight. However, under this regimen he further developed multiple vesicles and bullae on the neck, trunk and extremities. Prednisone was hence increased to 1 mg/kg body weight/day and associated with azathioprine 2.5 mg/kg/day. Genital lesions were concomitantly treated with topical betamethasone associated with topical antibiotics and disinfectants. Thereafter, both mucous and cutaneous lesions started healing. Four weeks later, at the end of the consolidation phase, prednisone was tapered gradually. After 12 months, the patient remained in complete remission under therapy (Fig. 1).

Case 2. A 35-year-old man was referred for evaluation of a 3-month history of painful penile erosions. Topical treatments with disinfectants and topical antibiotics had no effect. Two months after appearance of the genital lesions the patient also developed painful oral lesions. On examination, the patient had multiple erythematous erosions on the glans penis and sulcus coronarius (Fig. 2). In the oral cavity, the patient exhibited asymptomatic erosions in the region of the palatal arch and the lower lip. Histology from the glans penis showed an intraepidermal bulla with acantholytic cells. Direct immunofluorescence microscopy studies demonstrated deposits of IgG and C3 on the cytoplasmic membrane of the keratinocytes. ELISA-dsg 3 was strongly positive (146 U/ml, normal <7), whereas ELISA-dsg 1 was negative. The patient was treated with prednisone 1 mg/kg body weight and azathioprine 150 mg/day. Furthermore, he received topical betamethasone in combination with topical antibiotics and disinfectants. Under this regimen, the lesions

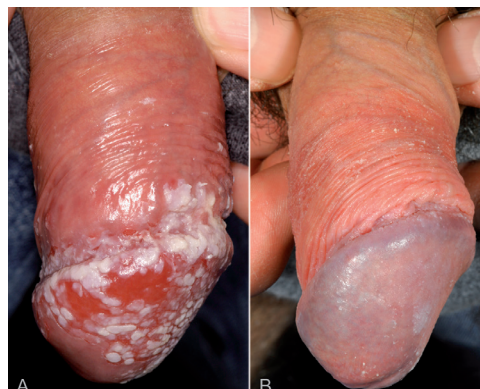

Fig. 1. (A) Penile pemphigus. On initial evaluation, there were widespread erosions of the glans penis and of the corona glandis with denuded areas. The epithelium was whitish, macerated, and could be displaced easily using a cotton tip (Nikolsky sign). (B) Resolution of the lesions following treatment with prednisone and azathioprine.

slowly healed within 4 weeks. Prednisone dosage was subsequently reduced over a time period of 6 months to a daily dose of 7.5 mg without further exacerbation of the disease.

DISCUSSION

We present here the observation of 2 patients in which penile erosions represented the first and leading manifestation of PV. Although mucosal involvement in PV is common, it is the oral mucosa that is most frequently affected, while other mucosae are significantly less frequently involved (3). In a retrospective series Chams-Davatchi et al. (11) observed involvement of

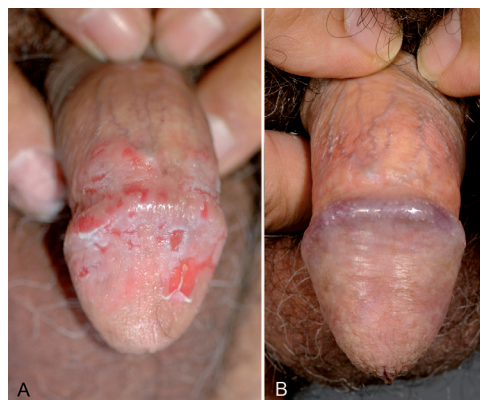


Fig. 2. (A) Penile pemphigus. Isolated irregular erosions with denuded epithelium. At the periphery of the erosions, such as on the middle portion of the glans, the epithelium detaches and can be easily displaced. Note the stellate-like and fissured appearance reminiscent of Hailey-Hailey disease. (B) Resolution of the erosions under systemic therapy.

the oral cavity, conjunctiva, nasal, vaginal, laryngeal/oesophageal and perianal mucosae in 81%, 16%, 11%, 9%, 8% and 2% of cases, respectively. Genital tract lesions have also been described in PV, but almost invariably in women. Akhyani et al. (12) observed genital involvement in 51%, almost invariably showing extensive mucocutaneous involvement. After the oral mucosa, genital mucosa might thus represent the second most commonly affected mucosal site in PV, and its involvement is surely under-diagnosed (12). Finally, the presence of genital lesions was associated with treatment-resistance and regarded as a poor prognostic factor and marker of disease severity (9).

Although the presence of genital lesions of PV in men has been described anecdotally (10, 13, 14), the possibility of penile involvement as a first manifestation of PV has received little attention so far. The only report emphasizing genital involvement in men is that of Sami & Ahmed (13), who described 12 PV patients with penile lesions. Ten of these patients also had typical cutaneous lesions, whereas 2 had lesions involving both the oral and genital mucosae. The glans penis was the most commonly affected area, followed by the shaft and corona glandis. All patients responded to systemic corticosteroids and immunosuppressive agents, as well as, in some cases, to intravenous immunoglobulins, with no further recurrence of penile lesions.

The clinical features of PV in the 2 cases described here seem to be characteristic for penile PV. Coalescing erosions of the glans penis and sulcus coronarius were present. The penile skin had a whitish macerated appearance with delicate fissures. Proper diagnosis was difficult and delayed in both cases. Since erosive penile lesions are most frequently related to an infectious aetiology, both patients first underwent systemic topical antiviral and antibiotic treatments, with no effect. In one of our cases the initial diagnosis was that of bipolar aphthosis (oral and genital), and the patient was treated accordingly with no response.

Sirois et al. (15) reported that patients with PV exhibiting oral lesions as a first manifestation had a mean diagnostic delay of >6 months. Penile involvement needs to be systematically excluded by clinical examination, even in patients without local discomfort or other symptoms.

ACKNOWLEDGEMENTS

This study was supported by Coordination Theme 1 (Health) of the European Community's FP7, grant agreement number HEALTH-F2-2008-200515 (to L.B.) and the Swiss National Foundation for Scientific Research (FNS/SNF 31003A-09811, to L.B.).

REFERENCES

1. Stanley JR, Amagai M. Pemphigus, bullous impetigo, and the staphylococcal scalded-skin syndrome. *N Engl J Med* 2006; 355: 1800–1810.
2. Scott JE, Ahmed AR. The blistering diseases. *Med Clin North Am* 1998; 82: 1239–1283.
3. Bystryn JC, Rudolph JL. Pemphigus. *Lancet* 2005; 366: 61–73.
4. Black M, Mignogna MD, Scully C. Number II. Pemphigus vulgaris. *Oral Dis* 2005; 11: 119–130.
5. Mignogna MD, Lo Muzio L, Galloro G, Satriano RA, Ruocco V, Bucci E. Oral pemphigus: clinical significance of esophageal involvement: report of eight cases. *Oral Surg Oral Med Oral Pathol Oral Radiol Endod* 1997; 84: 179–184.
6. Scully C, Mignogna M. Oral mucosal disease: pemphigus. *Br J Oral Maxillofac Surg* 2008; 46: 272–277.
7. Espana A, Fernandez S, del Olmo J, Marquina M, Pretel M, Ruba D, et al. Ear, nose and throat manifestations in pemphigus vulgaris. *Br J Dermatol* 2007; 156: 733–737.
8. Frangogiannis NG, Gangopadhyay S, Cate T. Pemphigus of the larynx and esophagus. *Ann Intern Med* 1995; 122: 803–804.
9. Malik M, Ahmed AR. Involvement of the female genital tract in pemphigus vulgaris. *Obstet Gynecol* 2005; 106: 1005–1012.
10. Malik M, El Tal AE, Ahmed AR. Anal involvement in pemphigus vulgaris. *Dis Colon Rectum* 2006; 49: 500–506.
11. Chams-Davatchi C, Valikhani M, Daneshpazhooh M, Esmaili N, Balighi K, Hallaji Z, et al. Pemphigus: analysis of 1209 cases. *Int J Dermatol* 2005; 44: 470–476.
12. Akhyani M, Chams-Davatchi C, Naraghi Z, Daneshpazhooh M, Toosi S, Asgari M, et al. Cervicovaginal involvement in pemphigus vulgaris: a clinical study of 77 cases. *Br J Dermatol* 2008; 158: 478–482.
13. Sami N, Ahmed AR. Penile pemphigus. *Arch Dermatol* 2001; 137: 756–758.
14. Palleschi GM, Giomi B, Giacomelli A. Juvenile pemphigus vegetans of the glans penis. *Acta Derm Venereol* 2004; 84: 316–317.
15. Sirois DA, Fatahzadeh M, Roth R, Ettl D. Diagnostic patterns and delays in pemphigus vulgaris: experience with 99 patients. *Arch Dermatol* 2000; 136: 1569–1570.