

## Cryptococcal Cellulitis in a Patient with Bullous Pemphigoid

Kazumitsu Sugiura<sup>1</sup>, Nana Sugiura<sup>1</sup>, Tetsuya Yagi<sup>2</sup>, Mitsutaka Iguchi<sup>2</sup>, Hideaki Ohno<sup>3</sup>, Yoshitsugu Miyazaki<sup>3</sup> and Masashi Akiyama<sup>1</sup>

Departments of <sup>1</sup>Dermatology and <sup>2</sup>Infectious Diseases, Nagoya University Graduate School of Medicine, 65 Tsurumai-cho, Showa-ku, Nagoya, 466-8550, and <sup>3</sup>Department of Chemotherapy and Mycoses, National Institute of Infectious Diseases, Tokyo, Japan. E-mail: kazusugi@med.nagoya-u.ac.jp

Accepted Mar 14, 2012; Epub ahead of print Jun 12, 2012

Cryptococcosis is a rare, life-threatening fungal infection caused by the yeast-like encapsulated fungus *Cryptococcus neoformans*. It is considered an opportunistic infection as it affects mainly immunosuppressed individuals (1, 2). The disease is believed to be acquired mainly by inhalation of the infectious propagule from the environment. In humans, *C. neoformans* causes various kinds of clinical manifestations; meningoencephalitis, pneumonia, skin lesions, eye lesions, bone involvement, etc. (3). AIDS is the predisposing factor in approximately 90% of cryptococcal infections (4). Other defects in T-cell-mediated immunity are also predisposing factors of infection, such as haematological malignancies (4).

We report here an elderly male patient with bullous pemphigoid (BP) who was complicated with cryptococcal cellulites.

### CASE REPORT

A 79-year-old man, living in a big city in Japan, presented with swelling, erythema and severe pain of the left arm. The skin lesions had developed rapidly. The patient reported an accidental injury of the left arm before the skin lesions. The patient had had BP for one year and had been treated with oral prednisolone at 17.5 mg daily from the onset of the lesion on the arm. The diagnosis of BP was based on skin manifestations of generalized multiple bullae (Fig. 1), histological features of subepidermal blisters with eosinophilic infiltration, deposition of IgG and C3 at the dermal basement membrane zone, and high-titre circulating

anti-BP180 antibodies detected with BP180 enzyme-linked immunoassay (ELISA) (MBL Intl. Corp., Nagoya, Japan).

On examination, the left forearm exhibited swelling and erythema, suggesting cellulitis. The left axillary lymph nodes were palpable. The results of blood examination were as follows: white blood cell count of 11,600/ $\mu$ l (normal: 4,000–8,000/ $\mu$ l), C-reactive protein of 6.77 mg/dl (<0.30 mg/dl), urea nitrogen of 30 mg/dl (10–15 mg/dl), creatinine of 1.15 mg/dl (0.60–1.10 mg/dl), and lactate dehydrogenase of 315 U/l (125–225 U/l). Other data were within normal limits, including beta-D glucan of <6.0 pg/ml (<11.0 pg/ml) and circulating antibodies to HIV of 0.1 S/CO (<1.0 S/CO). Intravenous piperacillin 2 g  $\times$  2/day was initiated for 1 week as an empirical treatment for bacterial cellulitis. Pairs of blood cultures were negative. One week later, intravenous meropenem at 0.5 g  $\times$  2/day was administered. However, no improvement in the cellulitis of the left arm was perceived.

Finally, histopathological observations of a skin biopsy specimen from the cellulitis with haematoxylin-eosin stain, Grocott stain and periodic acid-Schiff stain revealed yeast-like microbes 2 weeks after the administration of antibiotics. *Cryptococcus* spp. was suspected as pale spherules by haematoxylin-eosin stain (Fig. 1). This finding was subsequently verified by microbial culture. Biopsy tissue on the left arm was also positive for *Cryptococcus* spp by culture. The serotype of isolated *Cryptococcus* sp. strain was identified as A (*C. neoformans* (var. *grubii*)) by PCR using primers specific for STE20 gene (5), and culture using L-canavanine glycine bromothymol blue medium (6), which was the most frequent type, not only in Japan but also in the world. Because of these findings, the patient's serum was tested for cryptococcal antigen, with repeated positive results.

Computed tomography (CT) of the lung revealed multiple peripheral round solid lesions including cavitory nodules, at most 2 cm in diameter and only in the right lower lung field,

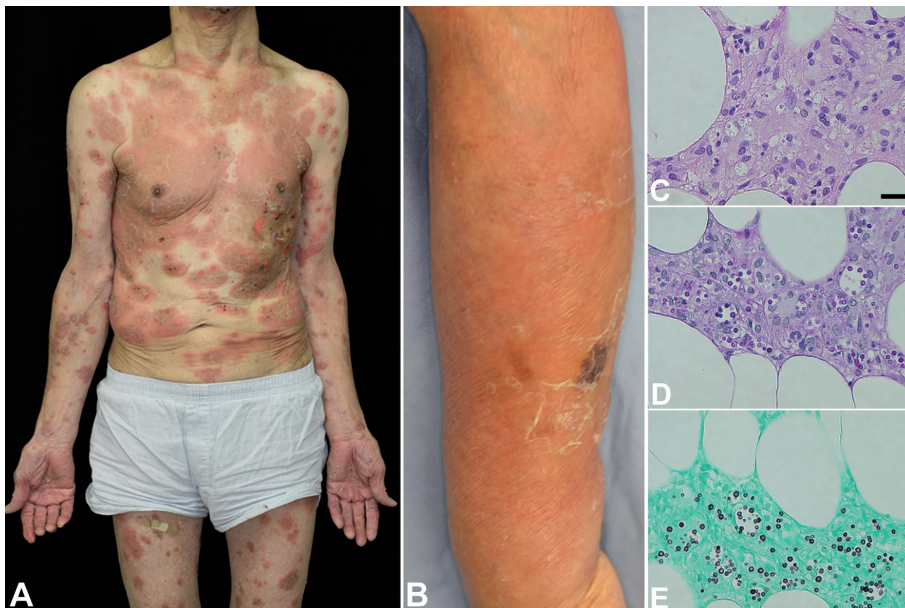


Fig. 1. Clinical features of the patient, and the *C. neoformans* infection in the skin biopsy specimens from the left arm. (A) Generalized multiple blisters were seen when the BP initially occurred. (B) Erythema and swelling of cellulitis on the left forearm. (C–E) Spherules of *C. neoformans* were apparent in the subcutaneous fat tissue on the left arm when the cellulitis occurred (C, haematoxylin-eosin stain; D, periodic acid-Schiff stain; E, Grocott stain). Bar: 20  $\mu$ m.

of unknown aetiology. Sputum cultures could not be performed because the patient had no cough and sputum. The lesions were too peripheral for bronchoscopic guided biopsy and, due to the general condition of the patient, an open lung biopsy was not performed. However, on the basis of the results of the skin biopsy and positive serum cryptococcal antigen, we finally diagnosed them as pulmonary cryptococcosis. There was no evidence of cryptococcal meningitis by cerebrospinal fluid examination and brain CT.

Antifungal therapy with liposomal amphotericin B at 200 mg/day was given for 2 weeks and the empirical intravenous anti-bacterial therapy was discontinued. However, due to renal dysfunction, the therapy was changed to oral fluconazole (200 mg/day). Erythema and swelling on the left arm gradually improved. Fluconazole was continued for 9 weeks. As liver dysfunction was recognized, fluconazole was discontinued and itraconazole (100 mg/day) has been administered for 12 weeks. Although the patient had no respiratory symptoms, a follow-up CT scan of the lung after 4 months of antifungal treatment revealed slight improvement of the pulmonary lesions. Cryptococcal antigen in serum was still positive even after 4 months of treatment. Antifungal treatment was planned to be continued until recovery of immune status, or at least no shorter than 3 months from complete healing of the cellulitis. The prednisolone was tapered off until the BP flared up and then restored to a maintenance dose of 17.5 mg/day.

## DISCUSSION

Cutaneous cryptococcal infection is a rare, but important, feature of disseminated cryptococcosis (7). As demonstrated by our case report, it can mimic bacterial cellulitis.

Cutaneous cryptococcosis is usually painless and asymptomatic lesions often appear on the head and neck, but rarely on the limbs or the trunk (8), except under administration of corticosteroid (9). In our case, the patient suffered from pulmonary cryptococcosis, presenting nodules at most 2 cm in diameter by CT of the lung. It should take more than one month to develop such a granuloma. Therefore it is certain that the pulmonary lesion preceded the cellulitis in this case.

We saw a good clinical response by liposomal amphotericin B and fluconazole to the cellulitis in our patient. Indeed, the present strain of *C. neoformans* serotype A was susceptible to amphotericin B, fluconazole and itraconazole, according to the results of antifungal susceptibility test recommended by Clinical and Laboratory Standards Institute, which we obtained later. However, the lung lesions improved slightly and cryptococcal antigen in the serum was continuously positive even after 4 months of antifungal treatment. It is sometimes difficult to prevent cryptococcal antigenaemia in patients on long-term corticosteroid therapy (10). To control cryptococcal infection in BP patients, it is important to reduce the amount of corticosteroid. In light of this, administration of high-dose intravenous immunoglobulin is recommended to diminish BP disease activity and to reduce the use of corticosteroid in BP patients with cryptococcal infection (11).

Generally speaking, the risk of opportunistic infections is low in patients treated with PSL at 20 mg/day or less. However, immune abnormalities in BP patients, such as T cell abnormality (12), might create conditions beneficial for *C. neoformans* growth.

## ACKNOWLEDGEMENTS

The authors thank Ms Hiroko Kusachi and Mrs Akiko Okawara for their technical help with serotype identification and antifungal susceptibility testing of *Cryptococcus* strain.

This study was supported in part by 2 Grants-in-Aid for Scientific Research, (C) 23591617 (K.S.) 23802800 (H.O.) from the Ministry of Education, Culture, Sports, Science and Technology of Japan, a Grant-in-Aid for Scientific Research, (A) 23249058 (M.A.) from the Ministry of Education, Culture, Sports, Science and Technology of Japan, and a grant from the Ministry of Health, Labour and Welfare of Japan H23-shinkou-ippan-018, H22-shinkou-ippan-008, H21-shinkou-ippan-009.

*The authors declare no conflict of interest.*

## REFERENCES

1. Chen S, Sorrell T, Nimmo G, Speed B, Currie B, Ellis D, et al. Epidemiology and host- and variety-dependent characteristics of infection due to *Cryptococcus neoformans* in Australia and New Zealand. Australasian Cryptococcal Study Group. Clin Infect Dis 2000; 31: 499–508.
2. Christianson JC, Engber W, Andes D. Primary cutaneous cryptococcosis in immunocompetent and immunocompromised hosts. Med Mycol 2003; 41: 177–188.
3. Dromer F. Cryptococcosis medical mycology. In: Kwon-Chung KJ, Bennett JE, editors. Lea & Febiger, Philadelphia 1992: 397–446.
4. Pagano L, Fianchi L, Caramatti C, D'Antonio D, Melillo L, Caira M, et al. Cryptococcosis in patients with hematologic malignancies. A report from GIMEMA-infection. Haematologica 2004; 89: 852–856.
5. an Z, Li X, Xu J. Geographic distribution of mating type alleles of *Cryptococcus neoformans* in four areas of the United States. J Clin Microbiol 2002; 40: 965–972.
6. Kwon-Chung KJ, Polacheck I, Bennett JE. Improved diagnostic medium for separation of *Cryptococcus neoformans* var. *neoformans* (serotype A and D) and *Cryptococcus neoformans* var. *gattii* (serotype B and C). J Clin Microbiol 1982; 15: 535–537.
7. Kwon-Chung KJ, Sorrell TC, Dromer F, Fung E, Levitz SM. Cryptococcosis: clinical and biological aspects. Med Mycol 2000; 38 Suppl 1: 205–213.
8. Adachi M, Tsuruta D, Imanishi H, Ishii M, Kobayashi H. Necrotizing fasciitis caused by *Cryptococcus neoformans* in a patient with pemphigus vegetans. Clin Exp Dermatol 2009; 34: 751–753.
9. Anderson DJ, Schmidt C, Goodman J, Pomeroy C. Cryptococcal disease presenting as cellulitis. Clin Infect Dis 1992; 14: 666–672.
10. Hafner C, Linde HJ, Vogt T, Breindl G, Tintelnot K, Koellner K, et al. Primary cutaneous cryptococcosis and secondary antigenemia in a patient with long-term corticosteroid therapy. Infection 2005; 33: 86–89.
11. Czernik A, Toosi S, Bystryjn JC, Grando SA. Intravenous immunoglobulin in the treatment of autoimmune bullous dermatoses: an update. Autoimmunity 2012; 45: 111–118.
12. Ujiie H, Nishie W, Shimizu H. Pathogenesis of bullous pemphigoid. Dermatol Clin 2011; 29: 439–446.